

# Trauma to the esophagus

Floyd D. Loop, M.D.

*Department of Thoracic and Cardiovascular Surgery*

All esophageal perforations, regardless of location or size, are potentially lethal. As with the rupture of any hollow viscus, an esophageal tear demands recognition without delay, for early diagnosis influences the patient's hospital course more than any other single factor. Mediastinitis and its devastating sequelae progress rapidly, and any prolonged loss of time may eventually render the patient unresponsive to even the most aggressive treatment.

Before the era of antibiotics and incisional drainage, most patients died after cervical esophageal perforation and disruption of the thoracic esophagus was uniformly fatal. From the experiences reported by Jemerin,<sup>1</sup> Pearse,<sup>2</sup> Barrett,<sup>3</sup> Samson,<sup>4</sup> and others, the concept of operative treatment was introduced. In recent years, surgical intervention has become well established, and the prognosis for esophageal injury has greatly improved. It is the purpose in this paper to present the mechanisms of esophageal perforation, the methods that aid in preventing such injury, and the surgical principles involved in early and late stages of management.

### Upper esophageal perforation

Virtually all perforations of the cervical esophagus are caused by instrumentation or penetrating wounds. The upper end of the esophagus is the narrowest part, and the esophageal wall is compressed against the sixth or seventh cervical vertebra as the esophagoscope passes across the cricopharyngeus muscle.<sup>5</sup> The endotracheal tube cuff should always be deflated, since it contributes to a further decreased lumen diameter. The crushing effect is increased by hyperextending the patient's neck; perforation during diagnostic instrumentation is most likely to occur at this level. The surrounding buccopharyngeal fascia is lacerated, thus contaminating the retroesophageal or prevertebral space. Although lateral spread is contained by muscle and fascia, the retroesophageal space extends to the carina, providing an open route for descending mediastinal infection.

The endoscopist may realize what has happened when he becomes "lost" during the procedure. A suspected perforation should be confirmed by immediate contrast swallow. If the laceration is unnoticed, the patient will soon provide his own clues: cervical pain and tenderness, dysphagia, and fever occur within a few hours. Subcutaneous air soon becomes palpable in the neck and also can be seen on the roentgenogram. Within 6 to 8 hours, the infection becomes prominent laterally and descends into the mediastinum.<sup>6</sup>

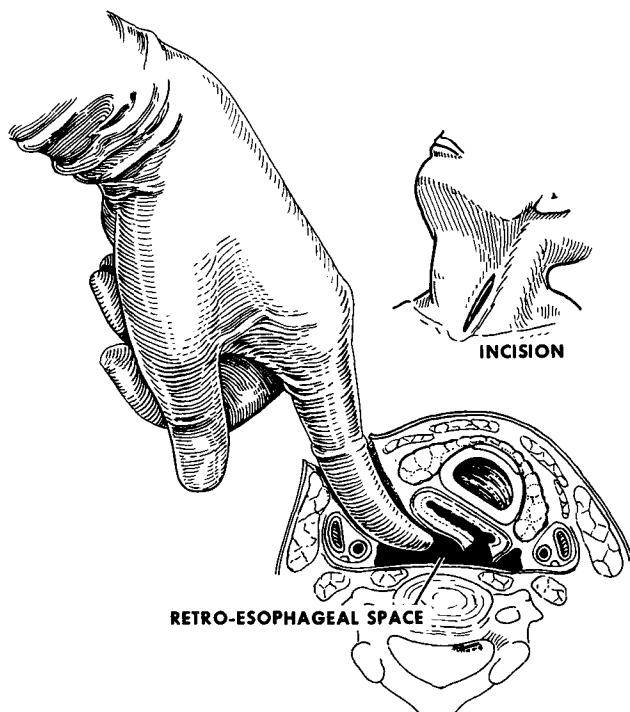
Unless the perforation is minute, e.g., from a pin or fish bone, expectant treatment with antibiotics involves a risk which may result in abscess formation, ultimately requiring cervical

drainage. In contrast, cervical mediastinotomy is a safe and simple approach that halts the threat of descending mediastinitis, drains the abscess, and shortens the hospital stay (*Fig. 1*). Often the laceration cannot be seen due to the tremendous inflammatory reaction, but primary suture is not mandatory and the hole will close spontaneously if no distal esophageal obstruction exists. Soft drains are placed both superiorly and inferiorly into the upper mediastinum and should remain in place 4 or 5 days, until a suitable tract is established.<sup>7</sup> During this time, the patient is fed through a nasogastric tube or intravenously, and broad spectrum antibiotics are administered until the drainage decreases. Thereafter, a solid diet is preferred, since liquids only add to the fistula output. In most cases, the leak closes within 10 days.

### Lower esophageal perforation

Endoscopic errors occur beyond the cricopharyngeal region less frequently. The incidence of perforation increases, however, in the presence of distal esophageal obstruction. Bouginage used for the treatment of achalasia, stricture, or neoplasm is associated with the greatest risk. Major operations, such as removal of large thoracic aneurysms or radical pulmonary resection may also cause injury to the nearby esophagus.<sup>8</sup> Perforation during abdominal vagotomy is another cause, and the possibility of esophageal injury should be considered when unexplained pleural infection arises in conjunction with these procedures.<sup>9</sup>

In the past decade, the so-called spontaneous rupture has been rediscovered and now rivals instrumenta-

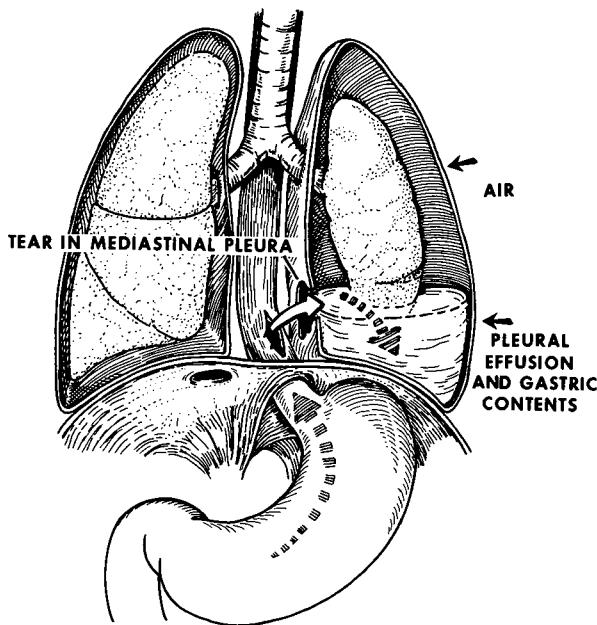


**Fig. 1.** Instrumental rupture of the cervical esophagus shown contaminating the prevertebral space. The drainage incision parallels the anterior border of the sternomastoid muscle and can be performed on either side. The middle thyroid vein and inferior thyroid artery are ligated to gain wide exposure of the prevertebral space. The inflammatory reaction guides the surgeon into the proper plane between trachea and carotid sheath.

tion as the leading cause of intrathoracic esophageal injury. The term spontaneous implies a tear not caused by external trauma, foreign bodies or instruments, but inflicted by the patient upon himself. Postmetic perforation has been suggested as more descriptive, but many reports emphasize heavy straining rather than vomiting.<sup>10</sup> The eponym, Boerhaave's syndrome (after the Dutch physician who first described the entity in 1754), is probably more applicable than the descriptive terms. A full thickness linear laceration is usually produced in the lower third of the esophagus on the left posterolateral wall. The muscle is thinner in this region and

the left side is least supported by surrounding viscera.<sup>11</sup>

For increased intraluminal pressure to cause a blowout, a temporary obstruction must exist at the other end of the esophagus. This can be produced through spasm of the cricopharyngeal pinchcock during alcoholic intoxication, or in central nervous system disease.<sup>12</sup> Muscular incoordination associated with prolonged retching and benign or malignant stricture can also provide the necessary obstructive element. The esophageal damage is often misdiagnosed, and the resulting delay accounts for a graver prognosis than with cervical perforations.



**Fig. 2.** Thoracic esophageal perforations create a fulminating chemical and bacterial effect that soon ruptures the mediastinal pleura. The negative intrapleural pressure then draws more saliva, air, and gastric fluid through the defect, causing a hydropneumothorax and compressive atelectasis.

Within several hours perforation of the thoracic esophagus produces a fulminating mediastinitis that directly contaminates one or both pleural cavities. The chemical insult quickly changes to a necrotizing aerobic and anaerobic process that ruptures the mediastinal pleura. When the pleura is contaminated, it reacts by producing a large effusion which compresses the lung, shifts the mediastinum and, eventually, compromises the cardiorespiratory mechanism (*Fig. 2*).

Typically, the so-called spontaneous rupture occurs in men older than age 50, and the history often includes excessive intake of food or alcohol. Mackler<sup>13</sup> described a triad of vomiting, chest pain, and subcutaneous emphysema that is pathognomonic for thoracic esophageal rupture, but the clinical findings are atypical in at least

one third of the patients. Hematemesis may have been noted initially, but its significance is much less than in Mallory-Weiss syndrome, in which the tear is confined in depth to the mucosa and circular muscle near the gastric junction. The diagnosis of a ruptured esophagus must be considered whenever vomiting and upper abdominal pain are prominent in the history. These early symptoms later give way to thoracic pain which will worsen despite supportive treatment and, finally, a shock-like picture develops.

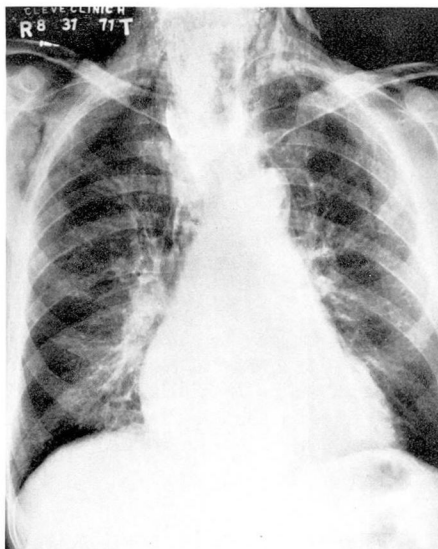
The most valuable diagnostic procedure is the upright chest roentgenogram. Most patients have pleural effusion or hydropneumothorax and a small percentage show fluid bilaterally. Air is common in the fascial planes of the mediastinum and can be seen in the soft tissues of the neck (*Fig.*

3). A contrast swallow of barium or an iodinated dye confirms the presence of a leak. In moribund patients, the medium can be injected through a naso-esophageal tube. When the esophagogram is normal, a diagnostic esophagoscopy can be performed.<sup>14</sup> If the diagnosis is still in doubt, the barium swallow should be repeated after an hour or two.

Free subdiaphragmatic air is rarely found and is an important differential point in ruling out a perforated peptic ulcer. The serum amylase level and roentgenographic picture of mediastinal or subcutaneous emphysema distinguish esophageal injury from pancreatitis, and an electrocardiogram helps exclude myocardial infarction. The pattern of signs and symptoms eliminate most other acute emergencies such as dissecting aneurysm, pulmonary emboli, mesenteric thrombosis, and inflammatory gastrointestinal diseases.

Treatment begins with insertion of a large intravenous cannula. The pleural contamination causes a massive fluid shift that requires large volume replacement and blood transfusions as indicated. A broad spectrum antibiotic or combinations thereof are also administered intravenously. A nasogastric tube is passed down the esophagus and its position in the stomach is confirmed when the chest is opened. A massive hydrothorax can be decompressed by tube thoracotomy while preparations are made for the formal procedure, but the definitive operation must be prompt. Toxicity and shock are not contraindications to operative treatment, and improvement cannot be expected until the defect is closed.<sup>15</sup>

Lower perforations are exposed



**Fig. 3.** Subcutaneous and mediastinal air demonstrated on posteroanterior chest roentgenogram. The patient sustained an iatrogenic esophageal perforation during diagnostic gastroscopy. The film was taken within 1 hour of injury. Note that neither pleural space is yet involved.

from the left side; middle third or higher thoracic esophageal injuries are approached through a right thoracotomy. The mucosal laceration may extend further than the muscular tear, and the surgeon should clearly visualize the limits of the defect before proceeding with a two-layer closure (*Fig. 4*). Multifenestrated chest tubes can be accurately sutured in dependent positions, preferably away from the thoracic aorta.

When the perforation is treated within 6 to 8 hours and no associated esophageal disease exists, the patient can begin eating by the end of the 1st week. Unfortunately this situation is the exception rather than the rule. More often, the patient already has gangrenous mediastinitis or underlying obstructive disease, such as carcinoma or esophagitis with stricture.

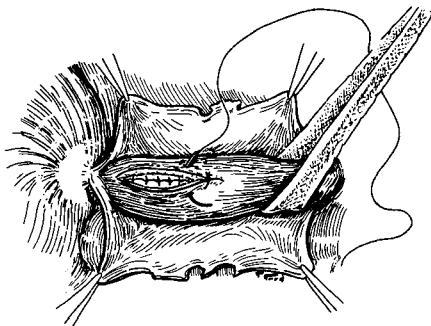


Fig. 4. View of lower esophageal rent seen through a left thoracotomy. The necrotic mediastinal pleura is widely opened and debrided. Mucosa and muscles are closed in two separate layers using interrupted 4-0 non-absorbable sutures.

In these cases, the major complication to avoid is breakdown of the repair. Suture of the perforation above a constriction, whether it be benign or malignant, is inadequate treatment, since a persistent fistula will inevitably result. Primary esophageal resection for benign disease is generally not a good alternative plan since reflux can later lead to severe esophagitis. Nevertheless, esophagogastrectomy is a straightforward procedure and results even in the presence of established mediastinitis have been good<sup>16</sup> (Fig. 5A). Reflux of gastric contents through the esophago-gastric anastomosis can be diminished and even eliminated by invaginating several centimeters of distal esophagus into the gastric fundus.<sup>17</sup> A one-stage resection is indicated when a perforation is encountered with carcinoma, providing the neoplasm has not widely disseminated. One operation is more beneficial than staged procedures and avoids prolonged hospitalization. Staging rarely accomplishes anything because the carcinoma is usually so advanced that its removal is impossible by the time the mediastinitis has cleared.

The fundic patch operation of Thal<sup>18</sup> is a proven method for covering large lacerations with necrotic edges or a perforation located above a benign stricture. The fully mobilized gastric fundus is applied over the divided stricture or long rent, thereby covering the defect and widening the esophageal lumen. Reflux is controlled by wrapping the remaining fundus around the patch (Fig. 5B).

Esophageal exclusion is the last resort of the alternative procedures and is reserved for the most desperate circumstances. This method described by Johnson et al<sup>19</sup> entails division of the lower esophagus and creation of a cervical esophagostomy. The pleural cavity is evacuated by water seal drainage and a gastrostomy is constructed for feeding. Exclusion may be life-saving but requires a secondary reconstruction (Fig. 5C).

Pulmonary complications are a primary concern in the postoperative period. Even the patient undergoing early repair often requires ventilatory assistance for the first 24 to 48 hours postoperatively. The elderly, malnourished, alcoholic, and those patients seen after 24 hours usually need tracheostomy. Serial upright chest roentgenograms are important in assessing the parenchymal and pleural changes during hospital convalescence.

Nutritional support is a problem in patients who experience dehiscence of the repair. Intravenous hyperalimentation may be employed during the first week of management; thereafter, if the patient is unable to swallow because of a persistent leak, a feeding jejunostomy is preferred to gastrostomy to reduce the reflux through the rent. Late suture line breakdown, after the chest tubes have been removed, pro-

duces symptoms of sepsis and the chest roentgenogram demonstrates air-fluid levels. This situation does not obligate the surgeon to reoperate for closure, if the collection is well drained. These leaks often close when nutrition is

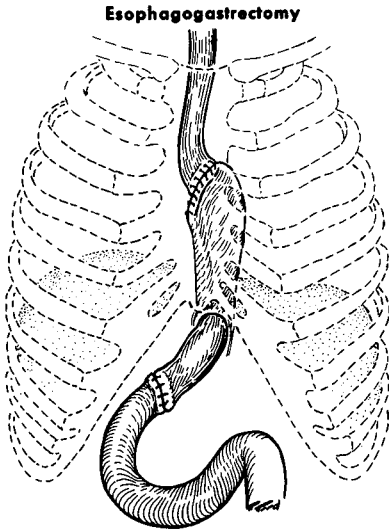


Fig. 5A

**THAL PROCEDURE AND FUNDOPPLICATION**

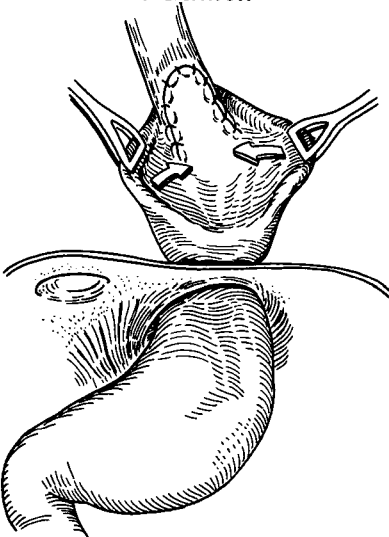


Fig. 5B

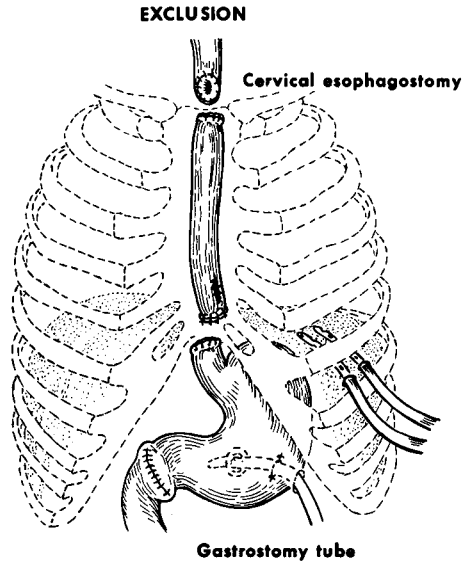
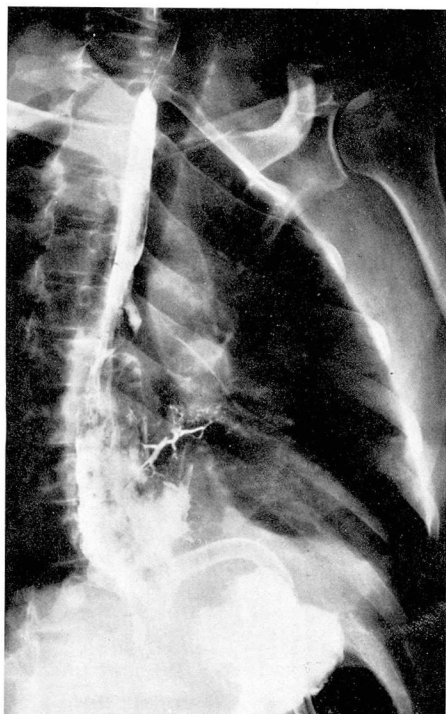


Fig. 5C

Fig. 5. The established surgical methods for treating large, necrotic tears or perforations that occur above an obstruction. A, Esophageal resection with a standard esophagogastric anastomosis, usually reserved for carcinoma. B, Mobilized gastric fundus covers the esophageal opening and a fundoplication is used to retard reflux. C, Esophageal exclusion. The esophagus is isolated by cervical esophagostomy above and division below.

preserved and no distal obstruction exists.<sup>20</sup> A solid diet can be started even in the presence of a moderate fistula. The patient will usually tolerate these feedings and hold a steady weight when more than half the food enters the stomach. Bronchoesophageal fistulas may also form after long-standing mediastinitis and pyopneumothorax. Under these circumstances, the esophagus should be kept at rest and the pleural cavity well drained. If satisfactory caloric intake can be maintained, the smaller fistulae will often heal spontaneously (Fig. 6).

The goals of surgical management are (1) secure closure of the rent



**Fig. 6.** The ravages of persistent mediastinal infection include bronchoesophageal fistulas. This communication formed 4 weeks after initial treatment. A feeding jejunostomy combined with further mediastinal drainage resulted in spontaneous closure.

coupled with wide mediastinal and pleural drainage, (2) full lung expansion, and (3) provision of a high caloric intake that yields a positive nitrogen balance. When the patient can gain weight through oral intake, he will usually overcome all late wound complications. None of these objectives are easy to attain, especially in the deteriorating patient who already has widespread necrotic mediastinitis and empyema. These challenging problems must be met with unerring surgical judgment, sound metabolic management, and the aggressive persistence always required in long-term support.

### Corrosive injury of the esophagus

Corrosive liquids are most often ingested by children between the ages of 1 and 2 years. Swallowing caustics with suicidal intent involves a relatively small number of adults. The extremely high acid or alkali concentration in drain cleaners and many cleansing agents inflicts an esophageal burn on immediate contact, and the healing process ends in stricture. The esophageal mucosa is more resistant to a substance with low pH, and acid ingestion produces its primary effect on the gastric antrum, which may lead to fibrosis, scarring, and pyloric obstruction. Corrosive chemicals rarely cause esophageal perforation, but this type of injury has an especially poor prognosis due to intense inflammatory destruction and suppurative mediastinitis.<sup>21</sup>

Esophagoscopy must be performed at the outset to assess the extent of the burn and to decide whether hospitalization is necessary. The chance of iatrogenic injury lessens when the esophagoscope is not advanced beyond the first esophageal burn. To diminish the fibroblastic response, steroid therapy (prednisone) should be administered within 48 hours of the ingestion and continued for approximately 6 to 8 weeks.<sup>22</sup> Antibiotic therapy shortens the necrotic phase of the burn and thus indirectly promotes healing.

In children and adults diagnostic esophagoscopy and the initial dilatation procedures should be performed under general anesthesia. It is dangerous to inspect repeatedly the areas of reepithelization, since the esophageal wall is weakest and most vulnerable to rupture during the first month

after steroid treatment. If the patient is suspected of having a severe corrosive injury, a gastrostomy should be performed early and a string swallowed to guide later dilatation. The fusiform Tucker bougies pulled through a gastrostomy are safer and more effective than antegrade dilatation when multiple strictures are present.

The esophageal segment below a long constriction may not be well visualized in an ordinary contrast study. An isolated area of scar can usually be dilated from above using olive-tipped bougies over previously swallowed string. Success using local triaminalone infiltration to resolve short strictures has been reported.<sup>23</sup>

When dilatation fails or extensive injury leads to obliteration of the esophagus, reconstructive surgery is required. This surgical procedure may be performed any time after the age of 1 year, and is usually colon interposition or the reversed gastric tube operation.

### Foreign bodies

More than half of all foreign bodies taken in through the oral cavity lodge in the esophagus. In children under age 4, the swallowed material can become impacted at or just below the cricopharyngeus muscle and, if undiagnosed, may eventually migrate through the lateral or ventral wall, even into the trachea.<sup>24</sup> The physician must suspect an impacted object in all children with respiratory complaints, gagging, or difficulty swallowing. Respiratory complaints such as dyspnea or wheezing are due to compression, aspiration, or fistulous communication with the trachea. In infants, the symp-

toms often are irritability or refusal to eat.

Pennies, buttons, and safety pins are the most frequent offenders in childhood (*Fig. 7A and B*), and bones and meat are most often responsible in the adult. Upper dentures inhibit the tactile sensation and disguise the true size of the object. In either age group, the surgeon must remove the object and also rule out any associated disease process that would reduce the size of the lumen. Although some foreign materials may pass with conservative treatment, this approach generally is not accepted. In adults, the "steakhouse syndrome" of meat impaction is often associated with an esophageal web or an esophagitis with stricture formation.<sup>25</sup> One of the first symptoms of esophageal carcinoma is obstruction from a bolus of food.

Roentgenograms are taken in the two standard planes with cervical hyperextension in the lateral view to raise the larynx and esophageal inlet above the clavicle. In difficult cases, cineradiography is of value. Foreign bodies in the esophagus lie in the coronal plane; those in the larynx or trachea lie in the sagittal plane. After careful study of the films, esophagoscopy is performed under general anesthesia. The endoscopist should never override or push the foreign body ahead of the esophagoscope but, instead, grasp the object with forceps, advance the esophagoscope to contact and then gently withdraw forceps, foreign body, and esophagoscope in one motion. Success has been reported in passing a Foley catheter beneath the foreign body, inflating the bag, and removing the object with gentle traction.<sup>26</sup> Obviously, this technique

should not be used for sharp objects or when there has been a long delay before the extraction procedure.

After the inflammation subsides, sometimes the impacted material still cannot be extracted endoscopically. In these cases and when esophageal erosion has occurred, direct surgical intervention is indicated rather than risk further damage by difficult instrumental manipulation. The same principles of exposure, esophageal suture, and mediastinal drainage apply.

### External trauma

Penetrating injury from knife or gunshot wounds almost always involves the cervical esophagus.<sup>27</sup> One should suspect esophageal damage in any neck wound, no matter how small. Subcutaneous emphysema associated with cervical penetration could mean esophageal perforation and laceration of the larynx, trachea, or apical pleura. If the wound has pierced the

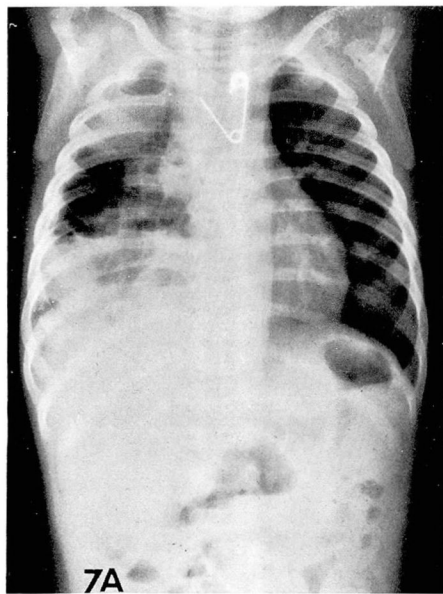


Fig. 7A

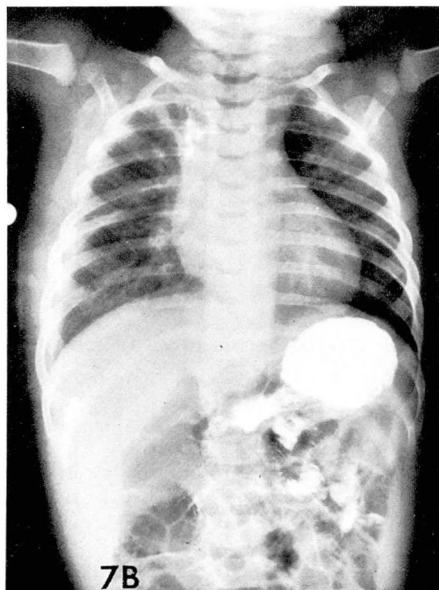


Fig. 7B

**Fig. 7.** A, An open safety pin with the sharp point proximally imbedded into the esophageal wall. The point was manipulated into the esophagoscope before withdrawing the pin. B, A suspected perforation is confirmed by barium swallow. The lung has been re-expanded by chest tube water seal drainage but a right thoracotomy was required for repair.

platysma muscle, exploration is indicated. When time permits, endoscopy and contrast studies can confirm or exclude occult injury to the trachea or esophagus. Esophageal lacerations from knife wounds are small and easily missed, even with contrast studies.<sup>28</sup>

An esophageal laceration produced by blunt trauma is uncommon but mimics the symptoms and signs of spontaneous rupture.<sup>29</sup> External penetrating wounds rarely involve the thoracic esophagus alone, but the possibility of esophageal injury must be kept in mind whenever the picture is confusing or when exploration is performed for other injury. A thoracot-

omy is necessary for closure of the defect and drainage.

## References

1. Jemerin EE: Results of treatment of perforation of the esophagus. *Ann Surg* **128**: 971-975, 1948.
2. Pearse HE Jr: The operation for perforations of the cervical esophagus. *Surg Gynecol Obstet* **56**: 192-196, 1933.
3. Barrett NR: Report of a case of spontaneous perforation of the oesophagus successfully treated by operation. *Br J Surg* **35**: 216-219, 1947.
4. Samson PC: Postemetic rupture of the esophagus. *Surg Gynecol Obstet* **93**: 221-229, 1951.
5. Wychulis AR, Fontana RS, Payne WS: Instrumental perforations of the esophagus. *Dis Chest* **55**: 184-189, 1969.
6. Paulson DL, Shaw RR, Kee JL: Recognition and treatment of esophageal perforations. *Ann Surg* **152**: 13-21, 1960.
7. Seybold WD, Johnson MA III, Leary WV: Perforation of the esophagus; an analysis of 50 cases and an account of experimental studies. *Surg Clin North Am* **30**: 1155-1183, 1950.
8. Takaro T, Walkup HE, Okano T: Esophagopleural fistula as a complication of thoracic surgery; a collective review. *J Thorac Cardiovasc Surg* **40**: 179-193, 1960.
9. Postlethwait RW, Kim SK, Dillon ML: Esophageal complications of vagotomy. *Surg Gynecol Obstet* **128**: 481-488, 1969.
10. Anderson RL: Spontaneous rupture of the esophagus. *Am J Surg* **93**: 282-290, 1957.
11. Mosher HP: Lower end of the esophagus at birth and in the adult. *J Laryngol Otol* **45**: 161-180, 1930.
12. MacIver IN, Smith BJ, Tomlinson BE, et al: Rupture of the oesophagus associated with lesions of the central nervous system. *Br J Surg* **43**: 505-512, 1956.
13. Mackler SA: Spontaneous rupture of the esophagus; an experimental and clinical study. *Surg Gynecol Obstet* **95**: 345-356, 1952.
14. Carter R, Hinshaw DB: Use of the esophagoscope in the diagnosis of rupture of the esophagus. *Surg Gynecol Obstet* **120**: 1304-1306, 1965.
15. Groves LK: Instrumental perforation of the esophagus: What is conservative management? *J Thorac Cardiovasc Surg* **52**: 1-10, 1966.
16. Hendren WH, Henderson BM: Immediate esophagectomy for instrumental perforation of the thoracic esophagus. *Ann Surg* **168**: 997-1003, 1968.
17. Pearson FG, Henderson RD, Parrish RM: An operative technique for the control of reflux following esophagogastrostomy. *J Thorac Cardiovasc Surg* **58**: 668-677, 1969.
18. Thal AP: A unified approach to surgical problems of the esophagogastric junction. *Ann Surg* **168**: 542-550, 1968.
19. Johnson J, Schwegman CW, Kirby CK: Esophageal exclusion for persistent fistula following spontaneous rupture of the esophagus. *J Thorac Surg* **32**: 827-832, 1956.
20. Tuttle WM, Barrett RJ: Late esophageal perforations. *Arch Surg* **86**: 695-700, 1963.
21. Dafoe CS, Ross CA: Acute corrosive oesophagitis. *Thorax* **24**: 291-294, 1969.
22. Webb WR, Koutras P, Ecker RR, et al: An evaluation of steroids and antibiotics in caustic burns of the esophagus. *Ann Thorac Surg* **9**: 95-102, 1970.
23. Holder TM, Ashcraft KW, Leape L: The treatment of patients with esophageal strictures by local steroid injections. *J Pediatr Surg* **4**: 646-653, 1969.
24. McLaughlin RT, Morris JD, Haight C: The morbid nature of the migrating foreign body in the esophagus. *J Thorac Cardiovasc Surg* **55**: 188-192, 1968.
25. Hargrove MD Jr, Boyce HW Jr: Meat impaction of the esophagus. *Arch Intern Med* **125**: 277-281, 1970.
26. Bigler FC: The use of a Foley catheter for removal of blunt foreign bodies from the esophagus. *J Thorac Cardiovasc Surg* **51**: 759-760, 1966.
27. Fogelman MJ, Stewart RD: Penetrating wounds of the neck. *Am J Surg* **91**: 581-596, 1956.
28. Noon GP, Beall AC Jr, DeBaKey ME: Surgical management of penetrating esophageal injuries. *J Trauma* **8**: 458-464, 1968.
29. Worman LW, Hurley JD, Pemberton AH, et al: Rupture of the esophagus from external blunt trauma. *Arch Surg* **85**: 333-338, 1962.

