

DIVERTICULA OF THE URINARY BLADDER

WILLIAM E. LOWER, M.D.

Diverticula of various hollow organs of the body are frequently encountered. They may be present without causing any outstanding symptoms, but that they do often cause symptoms and impairment of health is well attested by the many reports which have appeared in the literature of diverticula of the gastro-intestinal tract. In many cases, however, their presence is not suspected and the symptoms produced by them are supposed to be due to some other condition for which treatment is instituted. This is true also of diverticula of the urinary bladder.

The most common location of diverticula in the urinary bladder is in the lateral wall near the ureters. It is interesting to note that in the cases cited in the literature, as in our series, more were proximal to the left than to the right ureter — a fact, however, that seems to have no especial significance. In 62.1 per cent of our cases the diverticulum was in the lateral wall. In 21.2 per cent it was on the posterior wall; rarely in the dome and still less frequently in the trigone.

Diverticula may be single or multiple. In our series a single diverticulum was present in 63 per cent, two diverticula were demonstrated in 14.9 per cent, and there were more than two in 22 per cent.

The causative factors of diverticula of the gastro-intestinal and of the urinary tract are probably fundamentally identical. They are no doubt due to some congenital defect which, becoming aggravated under certain conditions, produces a diverticulum.

In the light of E. M. Watson's observations it seems probable that there is a congenital predisposition to their formation, but that their clinical recognition during adult life is hastened and "their dimensions greatly increased by any of the factors that would bring about increased vesical distention or increased activity of the bladder musculature." This opinion is strengthened by the fact that diverticula nearly always occur in males in whom also the urinary outlet is more frequently obstructed.

In our own series of 151 cases (see previous report of 110 cases) only two were in women. That obstruction to the urinary outlet is a strong etiological factor is further suggested by the fact that in

Reprinted by permission of SURGERY, GYNECOLOGY AND OBSTETRICS, 1931, Vol. 52, pages 324-329, 1931.

DIVERTICULA OF THE URINARY BLADDER

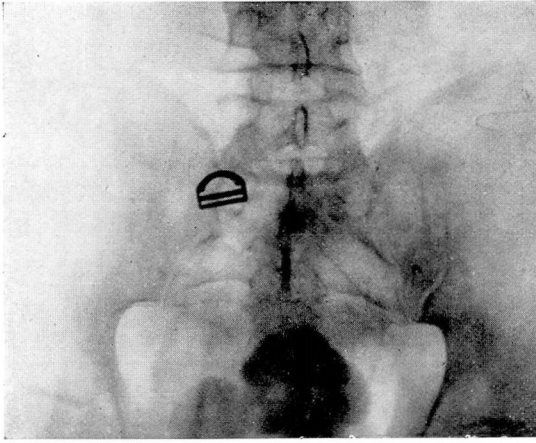


Fig. 1. Cystogram showing a vesical diverticulum on the posterior surface of the bladder. Stones are seen in both bladder and diverticulum.

Fig. 2. Right, Cystogram of bladder showing two large vesical diverticula, one on either side of the bladder. (See also illustration below.)

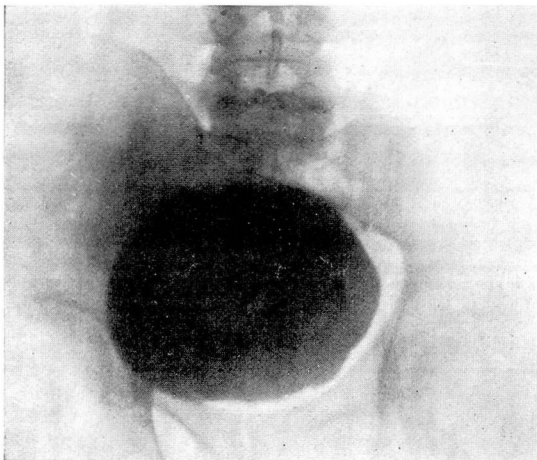
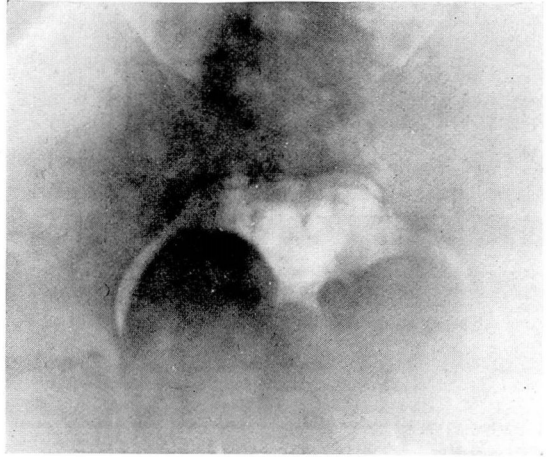


Fig. 2. (Cont.) Cystogram showing outline of bladder after removal of diverticula.

48.4 per cent of our total series, some obstruction of the urinary outlet existed, a ureteral caruncle being present in each of the two women in the series.

Whatever their cause — whether they be congenital or acquired — there is little we can do to prevent their formation, and our attention must therefore be devoted to diagnosis and treatment.

AGE INCIDENCE

Diverticula may occur at any age but they usually occur after the age of 50 years, this being true in 81.3 per cent of our cases. Our experience accords with the findings of many other reporters such as Judd, Hinman, Legueu and Papin, and others. The age incidence in our total series is given in Table I.

TABLE I. AGE INCIDENCE

Years	Cases
20-29.....	3
30-39.....	7
40-49.....	16
50-59.....	28
60-69.....	48
70-79.....	35
80 plus.....	2
Not stated.....	12

SYMPTOMATOLOGY

Diverticula present no specific symptoms. Their presence should be suspected, however, in any case in which frequency, difficulty in urination, and pyuria are present and in particular when ever there is persistent pyuria after repeated irrigations. The best diagnostic method is a roentgenographic examination of the bladder which should include an anteroposterior plate and at least two plates taken from different angles. If two or more urinations are necessary to empty the bladder, the presence of a diverticulum should always be suspected especially if the first urine voided is comparatively clear and is followed by the voiding of thick, foul-smelling urine and if difficulty in completely emptying the bladder is lessened by changing the position of the patient.

In our series, the order of frequency of the different symptoms in uncomplicated cases — that is, cases in which no other pathological conditions of the genito-urinary tract was demonstrated — is shown in Table II.

DIVERTICULA OF THE URINARY BLADDER

TABLE II.—SYMPTOMS

	Per Cent
Frequency.....	51.5
Retention.....	36.3
Pain on urination.....	27.3
Hæmaturia.....	24.2
Cloudy urine.....	21.2
Difficulty in urination.....	15.1
Pyuria.....	12.1
Acute pain.....	12.1
Dribbling.....	9.0
Burning.....	6.0
Incontinence.....	3.0

In the presence of inflammation, burning upon urination and dysuria may be quite pronounced. Hæmaturia, pyuria, and other urinary irregularities except those noted above, when present are generally due to some complicating condition.

DIAGNOSIS

Before the advent of the roentgenogram, we had little to guide us in the diagnosis of diverticula in the gastro-intestinal tract, and although the cystoscope was a great aid in determining the presence of a diverticulum of the urinary bladder, there was no way by which its size and contents could be accurately determined.

This accounts for the paucity of reports of diverticula until within comparatively recent years, for, after the existence of such a condition was suspected, the profession did not have at hand the means whereby to diagnose it properly.

Indeed, the cystoscope and roentgenogram are essential in making an absolute diagnosis of the presence of a diverticulum for the reason, as stated above, that there are no classical symptoms which may be considered as pathognomonic of the presence of this condition. Many diverticula are now found in the course of a routine cystoscopic examination in cases in which their presence has not been suspected, especially in cases of hypertrophy of the prostate.

Frequently the clinical history leads to a suspicion that a diverticulum is present. This is especially true in the case of men over 45 years of age who complain of difficulty in urination, frequency, pyuria, and have a feeling that the bladder is incompletely emptied. If two successive urinations are necessary to empty the bladder and there is no prostatic difficulty, the presence of a diverticulum is suggested.

Although a cystoscopic examination, when skillfully made, will usually reveal the presence and the situation of a diverticulum, its

size cannot be accurately estimated. The size of the opening into the diverticulum is no index to the size of the sac, as the largest diverticula often have very small openings. We feel, therefore, that after the presence of a diverticulum has been determined, the wisest procedure is to determine its size by cystograms. After the bladder has been drained by catheterization, it is refilled with a solution of sodium iodide, and a picture is taken with the patient on his back. Then the patient is turned on the side and another roentgenogram is taken. The bladder is then emptied as completely as possible by catheterization without introducing the tip of the catheter into any of the diverticula, and another picture is taken. The roentgenogram is then studied to determine whether or not retention is present.

This method of studying the bladder for the determination of the presence of diverticula is much more satisfactory than the older method of filling the bladder and making films in the usual positions, as when the films thus made were examined it was frequently found that the diverticulum was not satisfactorily demonstrated.

The final film, made after the bladder has been emptied, is sometimes of considerable importance because it may indicate whether or not a diverticulum should be removed.

COMPLICATING CONDITIONS

We have already referred to common complicating conditions which may either mask the presence of a diverticulum or lead to its discovery. Aside from prostatic conditions the most common complications are vesical infection, vesical calculi, and vesical tumors.

Many cases of calculi associated with diverticula have been reported; they may be in the bladder, in the diverticulum, or in both, or a "dumb-bell" stone may lie partly in the bladder and partly in the diverticulum. In a series of 133 cases reported from the Mayo Clinic, the following incidence of stones was noted:

	Cases
Stone in bladder and none in diverticulum.....	13
Stone in bladder and also in diverticulum.....	9
Stone in diverticulum.....	6

In our series, the incidence was as follows:

	Cases
Single stone in diverticulum.....	3
Multiple stones in dieverticulum.....	8
Stones in bladder alone.....	9
Stones in bladder and diverticulum.....	7

DIVERTICULA OF THE URINARY BLADDER

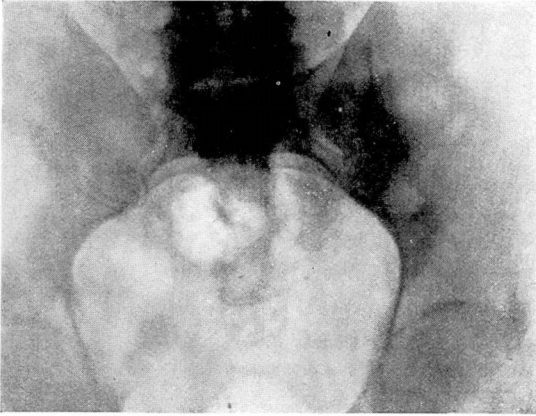


Fig. 3. Cystogram showing a dumb-bell stone, part of which is in the bladder and part in a diverticulum.

Fig. 4. Cystogram showing extensive multiple diverticulosis of the bladder.

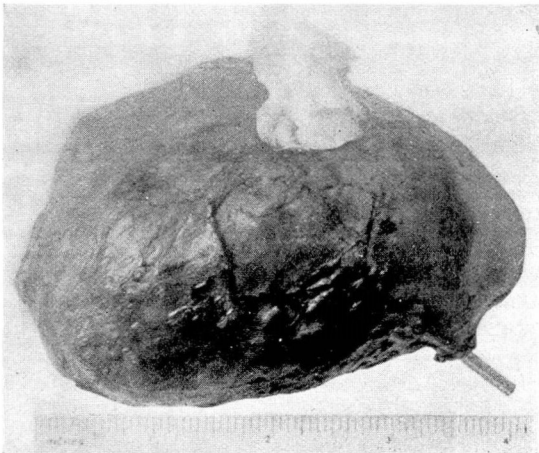
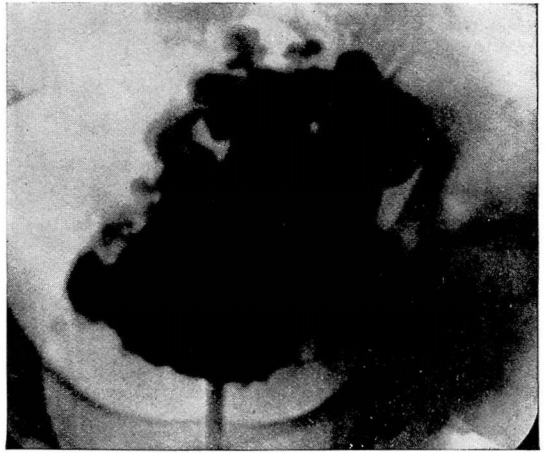


Fig. 5. Photograph of diverticulum involving the left ureter. In removing this diverticulum it was necessary to transplant the ureter into the bladder wall.

Stagnation and infection are naturally instrumental in the formation of calculi, and these factors are usually present in varying degrees in these cases. As shown by our statistics, calculi in the diverticulum may be single or multiple. If they are multiple they may become faceted and lie close together, so that only a roentgenogram will show that more than one stone is present. When large calculi are found in the diverticulum, they are usually associated with calculi in the bladder.

The presence of a malignant growth is a not altogether rare complication of diverticulum of the bladder. In our series we have had eight cases in which a diverticulum was associated with a tumor of the bladder, and in two of these cases, a papilloma was present in the diverticulum itself.

Infection of a diverticulum is of frequent occurrence and varies in intensity from a catarrhal inflammation to an actual ulcerated condition. Inflammation of the diverticulum is usually associated with cystitis, which gives the usual symptoms. Cases have been seen in which infection has progressed to such an extent that rupture of the diverticulum has occurred. The infection is more marked in those cases in which the orifice of the diverticulum is so small that it empties incompletely and stagnation results, the contents of the diverticulum finally becoming purulent. Efforts at emptying the bladder will often close the opening into the diverticulum like a sphincter muscle and instead of the contents of the diverticulum flowing out it will be retained. When the effort is over the opening relaxes and the contents empty into the bladder. Therefore, a second voiding is necessary to empty the bladder.

TREATMENT

The following surgical procedures for the treatment of diverticula of the bladder have been reported: (1) suture of the orifice of the diverticulum without excision of the sac (Pousson); (2) enlargement of the orifice (Pousson and Chute); (3) radical excision of the diverticulum *in toto* (Young, Hinman, Howard, Lower, Squier, and others).

Surgeons who have had the widest experience in the treatment of diverticula seem to be agreed that complete excision is the only procedure which leads to permanently satisfactory results. Moreover, there is a unanimity of opinion that, since obstruction in some form is nearly always an important factor in the development of a diverticulum of sufficient size to be brought to clinical notice, the cause of such obstruction should be removed with the diverticulum, if recurrence of the malady is to be avoided.

DIVERTICULA OF THE URINARY BLADDER

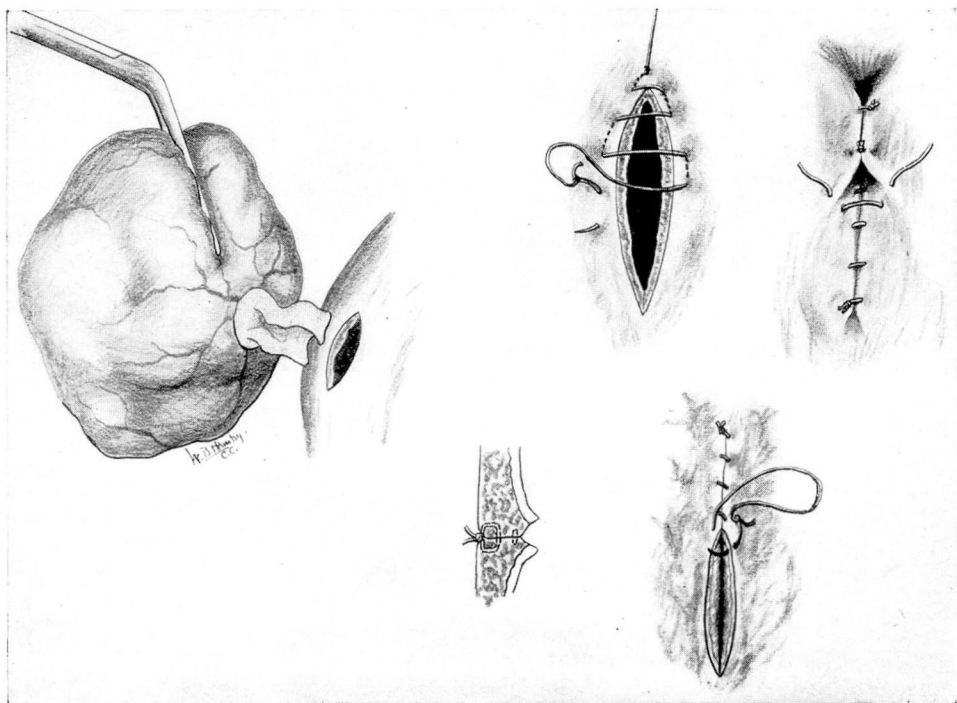


Fig. 6. Technique of closing the bladder wall after removal of a diverticulum.

In our clinic the following operative technique has been adopted: Under spinal or sacral anæsthesia, to which analgesia with nitrous oxide-oxygen is added in the case of an apprehensive patient, a suprapubic incision is made and carried down to the bladder. After the peritoneum has been stripped back, the bladder is opened. Exposure of the interior of the bladder is secured by means of flexible retractors and a Cameron light. The diverticulum is located and from its size and position the mode of procedure is determined.

If the extravesical approach is to be used, the collapsed diverticulum is first converted into a solid or semi-solid tumor by packing it with a gauze tape. It then becomes a comparatively simple matter to dissect down outside the bladder, lift out the created tumor, sever the attachment of the diverticulum, and close the opening into the bladder. It is important that at the point where the diverticulum has been removed, the bladder be closed with a good muscular apposition, the walls being inverted if possible so as to leave a slight ridge on the inner surface of the bladder rather than a depression at the point from which the attachment of the diver-

ticulum was removed, for such a depression might serve as a starting point for a recurrence.

One or more small diverticula may be present near a larger one. These are usually left intact, for if the cause of the urinary obstruction is removed and the large diverticulum is excised, the small ones apparently do not increase in size or cause symptoms.

The prevesical space should always be carefully drained. The bladder is closed with catgut sutures, a suture being applied first, to bring the two cut surfaces into apposition, and then an interlocking suture which passes entirely through the muscular coat. An inlying catheter is placed in the urethra and is allowed to remain for several days.

For the removal of a diverticulum in which the ureter is involved, various methods have been employed. Often the ureter will appear to empty into the diverticulum when in reality it has only been pulled over its edge, as it were, and the diverticulum can be removed without materially disturbing the ureter. When the ureter is included in the diverticulum or injured in the removal it must be carefully transplanted into the bladder. The transplantation should in such a way as to retain its physiological function as nearly as possible. A ureter has been transplanted in each of 10 of our cases.

MORTALITY AND END-RESULTS

In the reported cases the operative mortality varies from 6 to 8 per cent. In our series of cases in which excision of the diverticulum was performed the operative mortality was slightly over 5 per cent. In a few of the earlier cases, there has been a recurrence and a second operation done. However, in the later group an improved technique has prevented recurrences and the patients have been relieved of the principal symptoms of which they had complained. Postoperative cystograms have been made in many of these cases and no evidences of diverticula have been noted. The most difficult thing to eliminate entirely is the presence of some pus in the urine, especially when the infection has been of long standing before operation.

PROGNOSIS

If a radical operation is performed early and before renal impairment has become marked, the prognosis is usually favorable, although, of course, the prognosis depends upon any complicating condition which may be present. If, for example, a malignant growth is present, the prognosis must be guarded.

DIVERTICULA OF THE URINARY BLADDER

Whether or not there will be a recurrence of the diverticulum depends in part upon the manner in which the opening into the bladder is closed after the diverticulum is removed — if the musculature is not well approximated, or if any defect is left, it may be the starting point for a recurrence; and in part, upon whether or not the obstruction to the urinary outflow is removed.

In every case the relief secured from a radical operation is so much greater than that secured from palliative measures that there can be no doubt that the radical operation is the method of choice.

REFERENCES

- 1 Cabot, Hugh. *Modern Urology, Diseases of Bladder, Ureter and Bladder, Ureter and Kidney*. Vol. ii, 2d ed., p. 65. Philadelphia: Lea & Febiger, 1924.
- 2 Hinman, F. Vesical diverticulum. *Surg., Gynec. and Obst.*, 1919, xxix, 150-172.
3. Howard, H. W. Quoted by Cabot, loc. cit., p. 65.
- 4 Judd, E. S. Diverticula of the bladder. *Ann. Surg.*, 1918, lxxviii, 298-305.
- 5 Legueu and Papin. Diverticules de la vessie. *Arch. urol. de la Clin. de Necker*, 1921, p. 2.
- 6 Lower, W. E. An improved method of removing a diverticulum of the urinary bladder. *Cleveland M. J.*, 1914, xiii, 1-7.
- 7 Lower, W. E., and Higgins, C. C. Diverticula of the urinary bladder with report of 110 cases. *J. Urol.*, 1928, xxii, 635-661.
- 8 Pousson. Quoted by Cabot, Hugh, loc. cit., p. 65.
- 9 Pousson and Chute. Quoted by Cabot, Hugh, loc. cit., p. 65.
- 10 Squier, J. B. Surgery of the hourglass bladder. *New York M. J.*, 1914, xcix, 1026-1028.
- 11 Watson, E. M. Developmental basis for vesical diverticula. *J. Am. M. Assn.*, 1920, lxxv, 1473.
- 12 Young, H. H. The operative treatment of vesical diverticula with a report of four cases. *Johns Hopkins Hosp. Rep.*, 1906, xiii, 401-446.