

## THE CLINICAL PICTURE

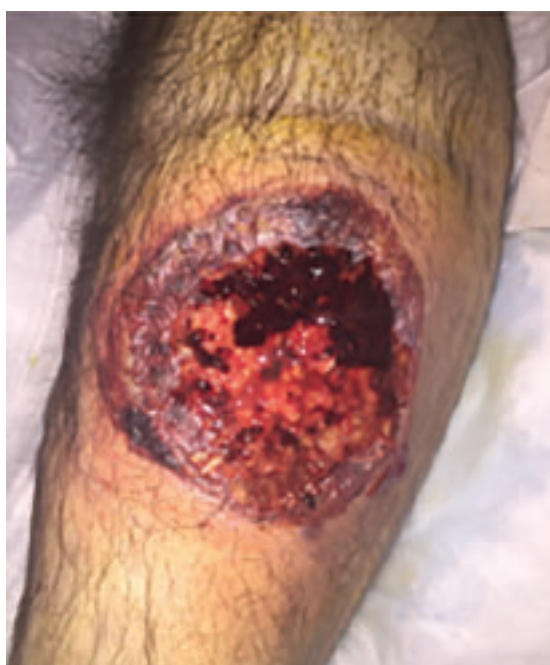**MICHAEL A. MUNOZ, MD**

Department of Internal Medicine,  
Hospital Medicine, Saint John's Episcopal  
Hospital, Far Rockaway, NY

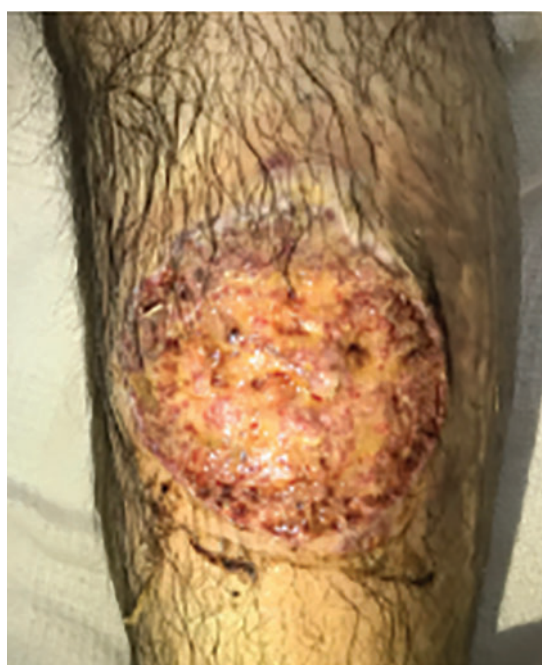
**BENSON A. BABU, MD, MBA, FACP**

Department of Internal Medicine,  
Hospital Medicine, Northwell Health, Plainview, NY

# Pyoderma gangrenosum mistaken for diabetic ulcer



**Figure 1.** The ulcer at presentation.



**Figure 2.** The lesion improved rapidly after the start of oral corticosteroid therapy.

**A man with type 2 diabetes, hypertension, anemia, and ulcerative colitis presented with an ulcer on his leg**

**A** 55-YEAR-OLD MAN WITH TYPE 2 diabetes mellitus, hypertension, anemia, and ulcerative colitis presented to the emergency department with an ulcer on his left leg (**Figure 1**). He said the lesion had started as a “large pimple” that ruptured one night while he was sleeping and then became drastically worse over the past week. He said the lesion was painful and was “oozing blood.”

On examination, the lesion was 7 cm by 6.5 cm, with fibrinous, necrotic tissue, purulence, and a violaceous tint at the borders. The patient's body temperature was 100.5°F (38.1°C) and the white blood cell count was

$8.1 \times 10^9/L$  (reference range 4.0–11.0).

Based on the patient's medical history, the lesion was initially diagnosed as an infected diabetic ulcer. He was admitted to the hospital and intravenous (IV) vancomycin and clindamycin were started. During this time, the lesion expanded in size, and a second lesion appeared on the right anterior thigh, in similar fashion to how the original lesion had started. The original lesion expanded to 8 cm by 8.5 cm by hospital day 2. The patient continued to have episodes of low-grade fever without leukocytosis.

Cultures of blood and tissue from the lesions were negative, ruling out bacterial infection. Magnetic resonance imaging of the left

doi:10.3949/ccjm.86a.19015

tibia was negative for osteomyelitis. Punch biopsy of the ulcer border was done on day 3 to evaluate for pyoderma gangrenosum.

On hospital day 5, the patient developed acute kidney injury, with a creatinine increase to 2.17 mg/dL over 24 hours from a baseline value of 0.82 mg/dL. The IV antibiotics were discontinued, and IV fluid hydration was started. At this time, diabetic ulcer secondary to infection and osteomyelitis were ruled out. The lesions were diagnosed as pyoderma gangrenosum.

The patient was started on prednisone 30 mg twice daily. After 2 days, the low-grade fevers resolved, both lesions began to heal, and his creatinine level returned to baseline (Figure 2). He was discharged on hospital day 10. The prednisone was tapered over 1 month, with wet-to-dry dressing changes for wound care.

After discharge, he remained adherent to his steroid regimen. At a follow-up visit to his dermatologist, the ulcers had fully closed, and the skin had begun to heal. Results of the punch biopsy study came back 2 days after the patient was discharged and further confirmed the diagnosis, with a mixed lymphocytic composition composed primarily of neutrophils.

### ■ APPROACH TO DIAGNOSIS

Pyoderma gangrenosum is rare, with an incidence of 3 to 10 cases per million people per year.<sup>1</sup> It is a rapidly progressive ulcerative condition typically associated with inflammatory bowel disease.<sup>2</sup> Despite its name, the condition involves neither gangrene nor infection. The ulcer typically appears on the legs and is rapidly growing, painful, and purulent, with tissue necrosis and a violaceous border.<sup>3</sup>

Pyoderma gangrenosum is often misdiag-

nosed as infective ulcer and inappropriately treated with antibiotics.<sup>2</sup> It can also be mistreated with surgical debridement, which can result in severe complications such as pathergy.<sup>1</sup>

The differential diagnosis includes diabetic ulcer, peripheral vascular disease, vasculitis, bacterial infection, osteomyelitis, and malignancy. Because it presents as an open, necrotic ulcer, ruling out infection is a top priority.<sup>3</sup> However, an initial workup to rule out infection or other conditions can delay diagnosis and treatment,<sup>1</sup> and treatment with broad-spectrum antibiotics poses the risk of nephrotoxicity and new complications during the hospital stay.

Diagnosis requires meeting 2 major criteria—ie, presence of the characteristic ulcerous lesion, and exclusion of other causes of skin ulceration—and at least 2 minor criteria including histologic confirmation of neutrophil infiltrate at the ulcer border, the presence of a systemic disease associated with pyoderma gangrenosum, and a rapid response to steroid treatment.<sup>4,5</sup>

Our patient was at high risk for an infected diabetic ulcer. After infection was ruled out, clinical suspicion for pyoderma gangrenosum was high, given the patient's presentation and his history of ulcerative colitis.

### ■ TREATMENT

Treatment of pyoderma gangrenosum begins with systemic corticosteroids, as was done in this patient. Additional measures depend on whether the disease is localized or extensive and can include wound care, topical treatments, immunosuppressants, and immunomodulators.<sup>1</sup>

### ■ REFERENCES

1. **Bhat RM.** Pyoderma gangrenosum: an update. *Indian Dermatol Online J* 2012; 3(1):7–13. doi:10.4103/2229-5178.93482
2. **Marinopoulos S, Theofanakis C, Zacharouli T, Sotiropoulou M, Dimitrakakis C.** Pyoderma gangrenosum of the breast: a case report study. *Int J Surg Case Rep* 2017; 31:203–205. doi:10.1016/j.ijscr.2017.01.036
3. **Gameiro A, Pereira N, Cardoso JC, Gonçalo M.** Pyoderma gangrenosum: challenges and solutions. *Clin Cosmet Investig Dermatol* 2015; 8:285–293. doi:10.2147/CCID.561202

4. **Su WP, David MD, Weenig RH, Powell FC, Perry HO.** Pyoderma gangrenosum: clinicopathologic correlation and proposed diagnostic criteria. *Int J Dermatol* 2004; 43(11):790–800. doi:10.1111/j.1365-4632.2004.02128.x
5. **von den Driesch P.** Pyoderma gangrenosum: a report of 44 cases with follow-up. *Br J Dermatol* 1997; 137(6):1000–1005. PMID:9470924

ADDRESS: Benson A. Babu, MD, MBA, FACP, Department of Internal Medicine, Northwell Health, 888 Old Country Road, Plainview, NY 11803; [bensonbabumd@gmail.com](mailto:bensonbabumd@gmail.com)