


CLEVELAND
CLINIC
JOURNAL OF
MEDICINE



CLINICAL PRACTICE
GUIDELINES:
RENAL CELL CARCINOMA


SUPPLEMENT 1 TO VOLUME 64, 1997

SPECIAL ISSUE

Acknowledgment

Clinical Practice Guidelines: Renal Cell Carcinoma represents the second in a series of special supplements supported through an unrestricted educational grant from Schering Oncology/Biotech.


CLEVELAND CLINIC JOURNAL OF MEDICINE



CLINICAL PRACTICE GUIDELINES: RENAL CELL CARCINOMA

SUPPLEMENT 1 TO VOLUME 64, 1997

CLEVELAND CLINIC JOURNAL OF MEDICINE



INTRODUCTION

- From the Editor SI-3
R.M. BUKOWSKI, MD

ONCOLOGY SUPPLEMENT

- Clinical Practice Guidelines:
Renal Cell Carcinoma SI-4
R.M. BUKOWSKI AND A.C. NOVICK
- List of Abbreviations SI-5

CME CREDIT TEST



- CATEGORY I CREDIT SI-45

*Current guidelines state that participants in CME activities should be made aware of any affiliation or financial interest that may affect an author's article. Each author has been requested to complete a conflict of interest statement. The names of authors declaring a potential conflict of interest have been indicated with an asterisk.

Copyright© 1997 by the Cleveland Clinic Educational Foundation

The statements and opinions expressed in the *Cleveland Clinic Journal of Medicine* are those of the authors and not necessarily of The Cleveland Clinic Foundation or its Board of Trustees.

The *Cleveland Clinic Journal of Medicine* (ISSN 0891-1150) is published 10 times yearly by The Cleveland Clinic Foundation.

Subscription rates: U.S. and possessions: personal \$70; institutional \$90; single copy/back issue \$12. Foreign: \$90; single copy/back issue \$12. Institutional (multiple-reader rate) applies to libraries, schools, hospitals, and federal, commercial,


and private institutions and organizations. Individual subscriptions must be in the names of, billed to, and paid by individuals.

World Wide Web address: <http://www.ccf.org/ed/ccjhome.htm>

Postmaster address changes: *Cleveland Clinic Journal of Medicine*, EE37, 9500 Euclid Avenue, Cleveland, OH 44195. Subscription orders, editorial, reprint, and production offices (same address): Phone (216) 444-2661; Fax (216) 444-9385; E-mail, ccjm@cesmtp.ccf.org

Printed in USA.





RONALD M. BUKOWSKI, MD, EDITOR

From the Editor

The diagnosis and treatment of neoplastic diseases continues to evolve. Progress in the field of biotechnology, including development of recombinant cytokines and monoclonal antibodies, as well as significant advances in our understanding of the biology of neoplasms has contributed to advancement in the therapy and diagnosis of these disorders. In view of these rapid changes, guidelines addressing current therapeutic management of various malignancies are necessary.


This *Cleveland Clinic Journal of Medicine* supplement is the second in a series of management guidelines for neoplastic diseases. Dr. Novick and I have critically reviewed renal cell carcinoma literature to define practice guidelines for the diagnosis and treatment of patients with this tumor.

The first supplement was created in 1995 with a focus on the non-Hodgkin's lymphomas. Future supplements will focus on such topics as melanoma.

The goal is to establish treatment pathways that will permit cancer care providers to improve patient outcomes while containing healthcare costs. These therapeutic management guidelines are being developed as a freestanding Continuing Medical Education publication. The objective of these supplements, and of other educational commitments intended for the near future, is to share up-to-date information crucial to our understanding of the diagnosis and therapy of the targeted cancers.

We hope you find this supplement to be of value. Please let us know your comments and suggestions; we would appreciate hearing from you.

RONALD M. BUKOWSKI, MD
Cleveland Clinic Cancer Center



Clinical practice guidelines: renal cell carcinoma

RONALD M. BUKOWSKI, MD, AND ANDREW C. NOVICK, MD

BACKGROUND Renal cell carcinoma (RCC) is the most common renal malignancy and is increasing at an annual rate of approximately 2% worldwide. Metastatic RCC is among the more chemotherapy-refractory malignancies, with a 5-year survival rate less than 2%. A variety of therapies are currently under investigation for the treatment of metastatic RCC, particularly involving immunotherapeutic agents such as interferon alfa.

OBJECTIVES To review and compare historical and current data that define practice guidelines in the treatment of RCC.

DISCUSSION Of the various treatment modalities available for RCC, only surgery with complete removal of tumor burden can be considered as potentially curative, since the tumor is resistant to chemotherapy, hormonal therapy, and radiation therapy. However, biologic response modifiers (BRMs)—particularly immunotherapeutic agents such as interferon alfa—have been extensively studied and appear to produce objective tumor regression in selected patients with advanced disease.

CONCLUSIONS In patients with metastatic RCC, performance status is the most important predictor of outcome, and should therefore be utilized for therapeutic decision making. Immunotherapy with BRMs such as recombinant interferon alfa and recombinant interleukin-2 has been associated with meaningful antitumor responses in selected patients. Combination therapy with recombinant interferon alfa, recombinant interleukin-2, and 5-fluorouracil may offer considerable promise, and the subcutaneous administration of recombinant interferon alfa and recombinant interleukin-2 may improve the tolerability and convenience of these cancer treatments by reducing side effects and permitting outpatient administration. As treatment expectations for metastatic RCC are limited, experimental approaches are warranted.

INDEX TERMS: NEOPLASM, RENAL CELL; ANTINEOPLASTIC AGENTS CLEVE CLIN J MED 1997; 64:SI-1-48

From the Experimental Therapeutics Program, Cleveland Clinic Cancer Center (R.M.B.) and the Department of Urology (A.C.N.), The Cleveland Clinic Foundation.

Address reprint requests to R.M.B., Experimental Therapeutics Program, Cleveland Clinic Cancer Center, 9500 Euclid Avenue, Cleveland, OH 44195-5237.

Adenocarcinoma of the kidney is the most common renal tumor and is diagnosed in about 30 600 people in the United States each year.¹ Approximately 12 000 deaths are attributed to this disease annually in the United States. It is estimated that the incidence of renal cell carcinoma (RCC) is increasing at an annual rate of about 2% worldwide.² Approximately 33% of patients presenting with RCC will have metastatic disease at the time of initial presentation, and as many as 40% of the rest will eventually develop distant metastases.³ Although the disease most typically occurs in adults between the ages of 50 and 70 years,⁴ it has been reported in children as young as 6 months.⁴ Renal cell carcinoma affects males with approximately twice the frequency as females and collectively accounts for about 3% of adult malignancies.⁵

EPIDEMIOLOGY

Since the first report of RCC approximately 170 years ago,⁴ much has been published about the disease. A wide variety of environmental, cellular, hormonal, and genetic factors has been studied to elu-

cidate its cause (*Table 1*). Regrettably, the precise etiology of RCC remains undetermined. It occurs in sporadic, noninherited and inherited forms.⁶ Much interest exists in the molecular genetic basis of human RCC, and some of the most recent findings in this area are discussed in this review.

Cigarette smoking is a significant risk factor for the development of RCC.^{7,8} Approximately 30% of RCCs in males and 24% in females result from cigarette use.⁴ Tumor incidence appears to exhibit a dose-response relationship for pack-years of cigarette use.⁴ La Vecchia et al⁸ cited an approximately twofold increased risk of RCC in cigarette smokers based on collective information from published studies.⁸ The results of their case-control study were consistent with the results of other case-control studies.⁸ The relative risk of RCC in cigarette smokers derived from case-control studies is similar to the risk reported in cohort studies, in which relative risk ranged from 1.2 in a Japanese cohort to 2.7 in the British physician's study.⁸ Interestingly, La Vecchia et al⁸ demonstrated a significantly increased risk of RCC in not only current but also former smokers. Moreover, there was significantly increased risk with greater number of cigarettes and years of use, with

ABBREVIATIONS

5-FU: 5-fluorouracil	MIU: million International Units
ALT: autolymphocyte therapy	MNA: mean nuclear area
BRM: biologic response modifier	MNEF: mean nuclear elongation factor
CIV: continuous intravenous infusion	MNRF: mean nuclear regularity factor
CNS: central nervous system	MRI: magnetic resonance imaging
CPB: cardiopulmonary bypass	MU: million Units
CR: complete response	NK: natural killer (cell)
CT: computed tomography	PR: partial response
CTL: cytotoxic T lymphocyte	RCC: renal cell carcinoma
ECOG: Eastern Cooperative Oncology Group	rHuIFN-α: recombinant human interferon alfa
FUDR: floxuridine	rHuIFN-β: recombinant human interferon beta
GM-CSF: granulocyte-macrophage colony-stimulating factor	rHuIFN-γ: recombinant human interferon gamma
gp: glycoprotein	rHuIFN-α2a: recombinant human interferon alfa-2a
HLA-A2: human lymphocyte antigen-A2	rHuIFN-α2b: recombinant human interferon alfa-2b
IM: intramuscular	rHuIFN-α2c: recombinant human interferon alfa-2c
IU: International Unit	rHuIL-2: recombinant human interleukin-2
IV: intravenous	SC: subcutaneous
LAK: lymphokine-activated killer (cell)	TIL: tumor-infiltrating lymphocyte
MAPK: mitogen-activated protein kinase	TNF-α: tumor necrosis factor-alfa
MDR: multidrug resistance	TNM: tumor, node, metastasis (classification system)
MDR-1: multidrug resistance gene	VHL: von Hippel-Lindau (disease; gene)

TABLE 1
POTENTIAL EPIDEMIOLOGIC RISK FACTORS FOR
RENAL CELL CARCINOMA

Tobacco use
Obesity
Dietary fat
Abuse of phenacetin-containing analgesics
Occupational
Leather
Asbestos
Petroleum
Cystic kidney disease
Familial

higher risk among those who began smoking at younger ages. It is noteworthy that the risk of RCC declined after discontinuation of cigarette use. These studies confirm that cigarette smoking is an important and the single most well-defined cause of RCC, even though the association between cigarette smoking and RCC is apparently weaker than that for transitional cell carcinoma of the bladder and other urinary tract tumors.

Another more recently published case-control study⁹ investigated the relationship between RCC and tobacco in a total of 1732 cases and 2309 controls, including study sites in the United States, Germany, Denmark, Sweden, and Australia. McLaughlin et al reported a statistically significant association between cigarette smoking and RCC.⁹ The results showed that current smokers have a 40% increased risk of developing RCC compared with nonsmokers, noting that this risk increases with number of cigarettes and number of years of smoking. This pooled analysis of results from multiple countries provides additional confirmation that cigarette consumption has a significant role in the development of RCC.

In contrast, Benhamou et al¹⁰ reported that, in a hospital-based case-control study conducted in France involving a total of 196 histologically confirmed cases and 347 controls, no relationship between cigarette smoking and RCC was demonstrated. Benhamou and colleagues indicated that the lack of an association between smoking and RCC in females in their study may reflect the higher proportion of smokers in their control population than in the general population. They were, however, unable to explain the lack of an association of

smoking with RCC in males on study.

Obesity is also associated with an increased risk for development of RCC, especially in females.⁷ In a prospective study, Lew and Garfinkel¹¹ discovered increased mortality rates from RCC with increasing relative weight among females. Those whose weight was at least 140% of average were twice as likely to die from RCC than those whose weight ranged from 90% to 109% of average. It is not understood why obesity in females appears to promote the development of RCC.

Maclure and Willett¹² conducted a case-control study of diet and the risk of development of RCC. They evaluated 203 incidents and 207 prevalent cases of RCC among more than 1000 white patients in the Boston area who were at least 30 years old and diagnosed with histologically confirmed renal adenocarcinoma. Incorporating more than 600 control subjects, this study disclosed that dietary animal protein, animal fat, and saturated fat, with and without energy adjustment, were only weakly associated with RCC in unconditional or conditional logistic regression analysis. Moreover, prior hypotheses concerning the consumption of cholesterol, preformed vitamin A, beta-carotene, and cruciferous vegetables were not corroborated. Study results favored the possible association of food groups rather than specific selected nutrients in the relationship of diet to RCC, and weakly confirmed the hypothesis that a diet rich in animal products and low in vegetables increases the risk of RCC.

Other dietary factors may have a significant role in the development of RCC, particularly in females. Yu et al⁷ showed that daily coffee consumption, diuretic use, and the ingestion of diet pills appeared to be significantly associated with the development of RCC in females. By contrast, Wynder et al¹³ demonstrated no significant association between coffee consumption in males or females after controlling for cigarette smoking. Based on available published data,⁷ it is not possible at present to definitively establish a significant role for coffee consumption in the development of RCC. In addition to the factors mentioned above, an increased incidence of RCC has been found in association with the use of certain analgesics, principally associated with abuse of phenacetin-containing drugs.¹⁴

The development of RCC has also been associated with a variety of occupational and environmental factors. The incidence of RCC is increased among leather workers and individuals exposed to

asbestos in the workplace,^{15,16} and an increased risk may exist in workers who are chronically exposed to gasoline.¹⁷ Several studies also indicate a significantly increased incidence of RCC in patients with end-stage renal disease who have undergone prolonged dialysis and who develop acquired cystic kidney disease.¹⁸⁻²⁰ The risk of developing RCC in these dialysis patients has been reported to be greater than 30 times that found in the general population²¹; approximately 6% of dialysis patients with acquired cystic kidney disease will develop RCC.⁴ Nevertheless, RCC also occurs in end-stage renal disease patients who are not undergoing dialysis.

The multifactorial study reported by McLaughlin et al²² evaluated 154 histologically confirmed RCC patients and 157 controls who were similar in age. Conducted in Shanghai, China, where RCC is very uncommon, this study associated cigarette smoking with an elevated risk of RCC among males (too few females on study were determined to be regular smokers to allow a meaningful risk determination). Elevated risk for RCC was also observed for categories of greater body weight and increased meat consumption, whereas a reduced risk was noted for categories of increased fruit and vegetable intake. The regular use of phenacetin-containing analgesics (defined as at least twice per week for 2 weeks or longer) conferred an increased risk of RCC following adjustment for age, sex, education, body-mass index, and cigarette smoking. McLaughlin and colleagues indicated that their findings were consistent with those of earlier studies in Western countries and mentioned that many of the same risk factors for RCC are present in low- and high-risk societies. They also mentioned that there appeared to be no elevation of risk among asbestos-exposed workers, although they did indicate that occupational analyses were hampered by the small number of exposed patients on study.

Finally, Mellemaard et al²³ have recently reported their findings concerning the role of weight, height, physical activity, and amphetamine use in relation to RCC. This report involved the same multicenter, population-based, case-control study reported by McLaughlin et al.⁹ In this population, body-mass index was determined to be a significant risk factor among females and to a lesser extent among males. Mellemaard and colleagues calculated a threefold increased risk for females with a relative weight in the top 5% compared with those in the lowest quartile. Among females, the rate of

weight change was an independent risk factor for development of RCC. While this study reported that height and physical activity were not related to risk of RCC, high relative weight increases the risk of RCC, particularly among females, and amphetamine use was associated with an increased risk among males. Further, the rate of weight change may play a role in the etiology of RCC.

PATHOBIOLOGY

Renal cell carcinoma arises from proximal renal tubular epithelium and is therefore an adenocarcinoma.²⁴ The observation that the renal tubular epithelium is the most likely origin of RCC was made by Robin in 1855, and Waldeyer confirmed that proposal about a dozen years later.⁴ Because of the yellow color of these tumors and the fact that they bore considerable resemblance to clear cells from the adrenal cortex, Grawitz in 1883⁴ concluded that RCCs originated from adrenal rests within the kidney. For this reason, the term "hypernephroid tumors" was subsequently introduced, and for many years the incorrect term "hypernephroma" was used to describe RCCs.

Although RCC may arise in any region of the kidney, it is more frequently found in the superior pole.²⁴ The tumor most commonly presents as a solitary unilateral mass, although bilateral neoplasms may be present. The lesions tend to appear as spherical masses⁴ ranging in diameter from about 3 to 15 cm and averaging approximately 7 cm. However, RCCs may become very large, spread beyond the kidney, and eventually fill the entire retroperitoneum. These tumors typically arise in the renal cortex, but may invade the renal capsule and break through into the perirenal fat. They are commonly bright yellow or gray and tend to distort the outline of the kidney.²⁴ There are typically areas of ischemic, opaque, gray-white necrosis, as well as foci of hemorrhagic discoloration and areas of softening. The tumors commonly tend to form a pseudocapsule providing an appearance of encapsulation. Renal cell carcinomas have a tendency to invade the renal vein and subsequently appear as a solid column of cells within this vessel. This intravascular growth pattern may extend far along the inferior vena cava and even into the heart. Sporadic RCC may be found in either kidney with an approximately equal incidence.

Renal cell carcinoma may contain several different

cell types including clear, granular, and spindle cells, and may exhibit alveolar, trabecular, tubular, solid, papillary, or sarcomatoid patterns. Most tumors are combinations of clear cells and granular cells, and it is very uncommon to find a lesion that is entirely clear or granular in appearance. Clear cells exhibit vacuolation of the cytoplasm, and the nuclei are typically small and variably pyknotic. On special stain these cells are shown to contain glycogen and lipids, a histologic characteristic useful in the characterization of unknown metastases.^{24,25} The sarcomatoid variant, characterized by areas of typical RCC admixed with areas of spindle and/or pleomorphic giant cells, accounts for between 1% and 6% of all RCCs and is typically associated with a poorer prognosis than that predicted for clear-cell, granular, or mixed-cell renal carcinomas.²⁶⁻²⁹

During the past decade, great interest in the clinical and molecular genetics of RCC⁵ has been expressed. As mentioned, the disease occurs in sporadic and familial patterns, although the latter is comparatively rare. In 1979, Cohen et al³⁰ provided the first report identifying a possible chromosomal location for a gene associated with development of RCC in a kindred with clear-cell RCC. The involved family appeared to exhibit an autosomal dominant pattern of RCC inheritance. The disease was associated with a specific karyotypic abnormality: a balanced reciprocal translocation between the short arm of chromosome 3 and the long arm of chromosome 8. Each family member who developed RCC exhibited this 3;8 translocation (t[3;8]), whereas RCC did not develop in any family member lacking the t(3;8) translocation. Several years after the original report by Cohen et al,³⁰ Pathak et al³¹ reported on a different kindred exhibiting RCC in which there was a chromosome 3 to chromosome 11 translocation in the tumor. More recently, Kovacs et al³² have reported on another family with RCC wherein the chromosome translocation involved chromosome 3 to chromosome 6. Clearly, the similarity among these families was a genetic defect residing on the short arm of chromosome 3, indicating that chromosome 3 might be the locus of a gene that plays an important role in the development of RCC. Indeed, cytogenetic studies³³⁻³⁶ of RCCs have disclosed an increased incidence of deletions, translocations, and rearrangements involving chromosome 3. These and other studies established that loss of a segment of the short arm of chromosome 3 is a consistent finding in clear-cell

RCC.⁵ However, in order to identify the precise gene on chromosome 3 implicated in sporadic RCC, laboratory studies were carried out on an inherited form of RCC associated with von Hippel-Lindau disease. This disorder, which occurs approximately once in every 36 000 live births, is an inherited cancer syndrome in which malignancies develop at multiple sites including the kidneys, adrenal glands, cerebellum, spinal cord, epididymis, pancreas, and retinas.³⁷ Renal cell carcinoma occurs in almost 40% of individuals with von Hippel-Lindau disease and presents as a clear-cell tumor.⁵ Seizinger et al³⁸ used the technique of genetic linkage analysis to associate the von Hippel-Lindau (*VHL*) gene to *c-RAF1*, which is a proto-oncogene positioned on the distal region of chromosome 3p. The linkage analysis specifically demonstrated that the *VHL* gene was located on a small region of chromosome 3p between *RAF1* and a distal, polymorphic DNA marker, D3S18.⁵ It was demonstrated that the *VHL* gene consists of three exons with 854 coding nucleotides. Mutations in the *VHL* gene have been identified in each of the three coding exons. The *VHL* germ-line mutations were detected in approximately 75% of families studied.³⁹

Gnarra et al⁴⁰ examined the presence of mutations of the *VHL* gene in RCC tumors from patients with sporadic RCC. They reported the detection of mutations in tumor tissue from patients with localized or advanced cancer. In these patients, each exon of the *VHL* gene carried mutations including deletions, insertions, nucleotide substitutions, and nonsense mutations. A specific identification of defects in the *VHL* gene in tumor material obtained from patients with localized or advanced clear-cell RCC indicated that the *VHL* gene mutations play a key role in the etiology of nonhereditary RCC.^{41,42} However, *VHL* mutations have not been detected in all clear-cell RCCs studied to date.⁵ Also, the detection of frequent *VHL* mutations in sporadic RCCs does not absolutely exclude the participation of other tumor suppressor genes located on chromosome 3p in the etiology of RCC. Defects at other tumor suppressor gene loci in RCC, such as retinoblastoma or p53, may also play a role in the etiology and evolution of this tumor. The genetic and biologic alterations in RCC show many similarities with those in retinoblastoma. For instance, both cancers appear in sporadic and inherited forms and the inherited form of each disease appears to be associated with an earlier age of disease onset.⁴

It appears very well substantiated that a gene located at chromosome 3p is involved in RCC. Indeed, the introduction of a normal chromosome 3 into a RCC cell line has been demonstrated to diminish tumorigenicity, thereby providing additional evidence in sporadic RCC that a gene present on chromosome 3 is involved in its development.^{42,43}

In a recently published study, Schmidt et al⁴⁴ tested two new t(3;8)-associated RCCs for mutations in the *VHL* gene by single-stranded conformational polymorphism analysis followed by direct DNA sequencing, for loss of alleles on chromosomes 3p and 8, and for abnormalities in methylation in the first cloned exon of the *VHL* gene. This study disclosed the presence of a missense mutation in the *VHL* gene in one of the RCCs. Such a mutation produces a stop codon and a truncated protein. Schmidt and colleagues indicated that all of the RCC tumors from the family exhibiting the t(3;8) translocation showed a loss of the translocated portion of chromosome 3. They proposed a new multistep model for the development of RCC in persons possessing the t(3;8) translocation. In their model, a balanced t(3;8) translocation chromosome is inherited, followed by loss of the derivative chromosome 8 that contains one copy of the *VHL* gene at 3p25 because of chromosomal mutation. The remaining *VHL* gene then experiences a somatic mutation resulting in inactivation of both copies of the *VHL* gene.

Papillary RCC occurs in approximately 5% to 10% of malignant renal tumors.^{45,46} It is similar to clear-cell RCC in that it may occur in both inherited and noninherited forms. By contrast, however, the *VHL* gene does not appear to have a role in the etiology and continued evolution of papillary RCC.⁵ The observation that the *VHL* gene is mutated in many clear-cell RCCs, but is not mutated in papillary RCC, suggests that there are significant fundamental differences in genetic properties between papillary and nonpapillary RCC.

Recent studies from several laboratories^{47,48} have identified the functional target of the protein produced by the *VHL* gene. The von Hippel-Lindau protein binds tightly to the cellular transcription factor elongin. This factor consists of several subunits that activate transcription elongation by RNA polymerase II. The von Hippel-Lindau protein binds to elongin B and C subunits and inhibits transcriptional activity in vitro. Thus, the product of

the *VHL* gene may have a very important regulatory role in cellular transcription mechanisms. With increased understanding of the functions of the von Hippel-Lindau protein, it may be possible to design novel drugs or other approaches to provide effective therapy for von Hippel-Lindau disease and RCC.

Another area of investigation in RCC involves the participation of mitogen-activated protein kinases (MAPKs), which are known to have a key role in the mitogenic signal transduction pathway. In a recently reported study by Oka et al,⁴⁹ constitutive activation of MAPKs was demonstrated in a majority of human RCC samples. Moreover, this enzymatic activation was significantly associated with the histologic grade of the tumors. Oka and colleagues proposed that the constitutive activation of the MAPK cascade may be important in enhancing malignant potential in RCC. They acknowledged, however, that the precise cause of the MAPK activation is not understood.

CLINICAL FEATURES

Symptomology

Renal cell carcinoma has been described as one of the great "mimics" in clinical medicine²⁴ because it commonly produces a variety of systemic symptoms that do not appear directly related to the kidney. Moreover, RCC may exist in a clinically occult form for the greatest part of its duration. The classic diagnostic triad of gross hematuria, costovertebral pain, and a flank mass is estimated to occur in only approximately 10% to 20% of patients. This symptom complex is typically indicative of the presence of advanced metastatic disease.⁵⁰

It is common for RCC patients to exhibit systemic symptoms.⁵¹⁻⁵⁵ However, reports on the frequency of specific symptoms, abnormal laboratory findings, or other abnormalities demonstrate marked variability, probably due to variations in patient selection criteria. According to Skinner et al,⁵⁶ anemia is found in approximately 21% of patients undergoing nephrectomy for RCC. However, hypochromic anemia as a result of hematuria or hemolysis has been reported in up to 88% of patients with the disease according to other investigators.⁴ Other findings seen in RCC patients include fever, weight loss, hypercalcemia, erythrocytosis, and hepatomegaly, all of which have been reported to occur with varying frequency depending

TABLE 2
TNM CLASSIFICATION AND STAGE GROUPING FOR KIDNEY TUMORS*

TNM Classification		Stage Grouping			Robson Stage	
T1	≤ 2.5 cm/limited to kidney	Stage I	T1	N0	M0	I
T2	> 2.5 cm/limited to kidney	Stage II	T2	N0	M0	II
T3	a) Perinephric invasion	Stage III	T1	N1	M0	IIIB
	b) Major veins		T2	N1	M0	IIIB
T4	Invades beyond	Stage IV	T3a	N0,N1	M0	IIIA or IIIB
	Gerota's fascia		T3b	N0,N1	M0	IIIA or IIIB
N1	Single ≤ 2 cm		T4	Any N	M0	IV
N2	Single > 2 cm ≤ 5 cm		Any T	N2,N3	M0	III or IV
N3	Multiple ≤ 5 cm > 5 cm		Any T	Any N	M1	IV

Abbreviations: T = tumor; N = node; M = metastasis

*(From AJCC, reference 65, and UICC, reference 66). Adapted from Keller, reference 67, with permission

on the report cited.^{4,51-57} Abnormal liver function is reported in as many as 40% of RCC patients,^{52,55} who may also exhibit elevation of plasma fibrinogen levels⁵⁸ or acquired dysfibrinogenemia.⁵⁹ The polycythemia encountered in RCC patients,⁶⁰ which reportedly occurs in fewer than 5% of patients, may reflect the known ability of RCC cells to produce erythropoietin. In addition to this apparent endogenous hormone-producing effect of the tumor, it has also been observed that RCC elaborates a factor possessing bioactivity similar to that of parathyroid hormone.⁶¹⁻⁶³ In this regard, it has been reported that a parathyroid hormone-like substance may be responsible for malignant hypercalcemia, although it has not yet been established that this is the factor responsible for the hypercalcemia found in RCC patients.

Although RCCs may grow to impressive dimensions in the retroperitoneum prior to any evidence of metastasis, approximately one third of patients presenting with the disease will already have metastases. The most common metastatic sites are the lung (75%), soft tissues (36%), bones (20%), and liver (18%).⁵⁷

Staging

The RCC staging system most commonly used in the United States is the Robson Modification of the Flocks/Kadefsky Staging System.⁶⁴ This classification system is described in *Table 2* and compared to

the American Joint Committee on Cancer staging system. In the Robson Classification System, stage I RCC is confined to the renal parenchyma. Stage II disease involves tumor extension through the perirenal capsule, but with confinement to Gerota's fascia. Stage III is divided into two portions: stage IIIA includes tumor involvement of the renal vein or inferior vena cava; stage IIIB includes tumor involvement of local hilar lymph nodes. In the most advanced level, stage IV, the tumor has invaded adjacent organs or exhibits distant metastases.

Despite the fact that the Robson Classification System for RCC staging is straightforward and very widely used, it is imperfect in the sense that it does not sufficiently differentiate stages that might have substantially different prognoses. The tumor, node, and metastasis (TNM) classification system more accurately depicts the extent of tumor and lymph node involvement in patients with RCC.⁶⁸ Its correlation with Robson staging is shown in *Table 2*. In the TNM classification system, T1 indicates the presence of a tumor ≤ 2.5 cm in its greatest dimension and confined to the kidney; T2 indicates the presence of a larger tumor that may deform the kidney or its collecting system but which is still confined to the kidney; T3 indicates a tumor with perinephric extension (T3a) and/or invasion into major veins (T3b); and T4 indicates a tumor that has extended beyond Gerota's fascia. N indicates the degree of regional lymph node involvement

and M denotes the presence of distant metastases. Although there is a considerable degree of inconsistency in estimates of stage-adjusted survival in RCC, the survival statistics from the past two decades do not dramatically differ from those reported by Robson et al⁶⁴ in 1969 (Table 3). Patients with regionally advanced disease (stage IIIB) and lymph node involvement have limited 5- and 10-year survival. In patients with vascular invasion (stage IIIA), 5-year survival rates approaching 50% have been reported.

Furthermore, despite occasional reports of long-term survival in patients with metastatic RCC (stage IV), survival curves for this disease suggest that most patients will expire within 5 years.

Prognostic Factors

Golimbu et al⁷⁴ studied survival and prognostic factors in RCC using a retrospective analysis of 326 RCC patients treated at New York University Medical Center. They correlated survival with five factors: stage, location and size of primary tumor, extent of intrarenal and extrarenal infiltration, presence or absence of metastasis to regional lymph nodes or distant sites, and tumor cell histologic characteristics. An improved prognosis was found to be associated with several tumor characteristics, such as tumor size < 5 cm diameter; absence of invasion of the collecting system, perirenal fat, or regional nodes; and predominance of clear or granular cell pattern. Tsukamoto et al⁷⁵ reported that the prognosis of RCC patients whose tumors are diagnosed incidentally tends to be better than that in patients who present with symptoms, largely because the former group comprises patients with smaller lesions that are more likely to be confined to the kidney. The presence of metastases dramatically worsens the prognosis in RCC.^{4,74,76}

A recently published study from Sweden⁷⁷ reported on the analysis of serum from 170 unselected RCC patients. Erythrocyte sedimentation rate and

five acute-phase reactants including haptoglobin, ferritin, C-reactive protein, orosomucoid, and alpha 1-antitrypsin were studied. Each of these parameters separately had significant prognostic value for survival, according to the log rank test, but only the erythrocyte sedimentation rate was an independent prognostic factor for survival when evaluated using a multivariate Cox analysis.

Those patients who present with metastatic RCC and accompanying hypercalcemia of malignancy tend to have a very poor prognosis. Patients with metastatic disease who do not receive treatment have an extremely poor prognosis, with a 5-year survival < 2%. Among patients who develop metastases within a year of surgery for RCC, the 2-year survival rate approaches zero. By contrast, those patients who develop metastases 2 or more years following nephrectomy experience an approximate 20% 5-year survival rate. In general, studies have collectively demonstrated that increased survival in RCC patients who are diagnosed with metastatic disease occurs under the following conditions: the presence of a long disease-free interval between nephrectomy and the onset of metastasis, presence of pulmonary metastases only, good performance status, and removal of primary tumor.^{3,57}

Flow cytometric analysis of tumor DNA ploidy in stage I RCC may provide meaningful prognostic information for this disease.⁷⁸ There appears to be a significant difference in survival rates between

TABLE 3
SUMMARY OF PUBLISHED SURVIVAL RATES IN RENAL CELL CARCINOMA*

Year	Length of Survival (years)	Survival (%) by Stage				Ref
		I	II	III	IV	
1969	5	66	64	42	11	64
1971	5	65	47	51	8	56
1979	5	56	100	50	8	69
1981	5	67	51	34	14	70
1982	5	—	—	0-53	0	71
1983	5	93	63	80	13	72
1985	5	91-100	—	—	18	73
1986	5	88	67	40	2	74

*(From Linehan, reference 4). Adapted from Keller, reference 67, with permission

patients with aneuploid versus diploid tumors.⁷⁸ The study of Currin et al⁷⁹ employed flow cytometric evaluation of DNA content in primary RCC from more than 100 patients to determine if DNA ploidy status allowed improved prognostic stratification over staging alone. This study disclosed a significant difference in the incidence of disease progression among patients exhibiting diploid lesions compared with those exhibiting aneuploid tumors. However, when the data were adjusted for TNM stage, a survival advantage for DNA ploidy status was not evident. This is interesting because the incidence of disease progression among patients with diploid tumors was approximately 13%, compared with the approximately 35% incidence noted in patients with aneuploid tumors.

In addition to the highly sophisticated cellular and molecular probes, biophysical methods including nuclear morphometry⁸⁰ may have a meaningful role in providing important prognostic information for RCC patients. Nativ et al⁸⁰ recently studied the value of nuclear morphometry to predict outcomes in patients with localized RCC. In their study, the strongest predictors of disease-free interval were mean nuclear elongation factor (MNEF), mean nuclear regularity factor (MNRF), and mean nuclear area (MNA). Their multivariate analysis disclosed that MNA and MNEF independently correlated with survival among radical nephrectomy-treated patients with localized RCC. They propose that if further prospective controlled study corroborates their findings, it would be reasonable to employ nuclear morphometry in clinical trials involving patients with localized RCC.

DIAGNOSTIC FEATURES

Confirmatory studies are always necessary whenever a renal mass is suspected, regardless of the presence or absence of symptoms suggestive of RCC. The differential diagnosis of a renal mass lesion includes a variety of possibilities including RCC and other malignant tumors; benign inflammatory processes such as abscesses and pyelonephritis; hematomas within the structure of the kidney; various pseudotumors; and a variety of cystic masses including benign cysts, polycystic kidney, cystic dysplastic kidney, and hydronephrosis. Lang et al⁸¹ studied asymptomatic patients with 940 asymptomatic space-occupying renal mass lesions. Among these lesions, 55% were attributable to the presence

of a benign renal cyst and only 5.5% were due to malignant tumors. Only 2.2% of the 940 renal mass lesions were identified as RCCs.

Other malignant tumors that may present as a renal mass lesion include Wilms' tumor, which is found in children, and urothelial carcinomas of the renal calyces and pelvis.²⁴ Although Wilms' tumor, or nephroblastoma, typically arises between the ages of 1 and 4 years, rare cases have been reported in adults.²⁴ Malignancies of the renal pelvis are commonly first discovered when still small, as they typically cause hematuria or urinary tract obstruction with hydronephrosis early in their course. Although rare, a variety of sarcomas may be found in the kidney, as well as metastatic neoplasms that occasionally originate in the contralateral kidney.²⁴

Because of the high mortality associated with RCC, screening for this disease is worthy of consideration.⁸² Generalized screening of the public is not presently conducted because of such factors as the comparatively low incidence of RCC and the lack of availability of clearly defined target populations. In general, screening evaluation should be reserved for (1) patients with diseases with increased risk of RCC, such as tuberous sclerosis, von Hippel-Lindau disease, autosomal dominant polycystic kidney disease, or acquired (dialysis-associated) renal cystic disease; (2) patients with symptoms suggestive of RCC; or (3) immediate relatives of patients with von Hippel-Lindau disease or familial RCC.

The six basic radiographic modalities used to study and stage renal mass lesions are excretory urography, ultrasound, computed tomography (CT) scan, magnetic resonance imaging (MRI), arteriography, and venography. Any of these may provide useful information in any patient, but a combination of these techniques is often required to obtain the most comprehensive radiographic information about the character of a space-occupying renal mass lesion, especially if surgical removal is contemplated. Of these, MRI, ultrasound, and CT are widely used outpatient procedures that are noninvasive and thus preferred by patients.

Excretory urography with laminography is a popular modality for the initial radiographic evaluation of a space-occupying renal mass lesion, although ultrasonography is also frequently used.⁸³ If the excretory urogram or ultrasound examinations are abnormal or indeterminate, an abdominal CT scan should be then performed.

Ultrasound is an extremely useful modality for

the evaluation of space-occupying renal mass lesions and is particularly useful when a cystic mass is evident on the excretory urogram. Moreover, ultrasound may permit the determination of adjacent lymph node involvement, as well as possible tumor infiltration of the adrenal gland and adjacent organs.^{84,85}

The CT scan is also a valuable radiographic modality for the diagnosis of RCC.⁸⁴⁻⁸⁶ The concordance of CT data with gross pathology and histopathology is high, and CT has particular merit in delineating local lymph node involvement.^{87,88} Contrast-enhanced CT is extremely useful because of its exceptional sensitivity for relatively early stage neoplasia.^{85,89} The CT scan may be the single best study to clinically stage the primary tumor site and to exclude the possibility of intra-abdominal metastases.

An MRI is an excellent radiographic modality for the staging of RCC⁹⁰ and is an alternative to CT for patients with azotemia. An MRI produces an informative three-dimensional picture of the renal tumor mass and can demonstrate involvement of adjacent vascular and visceral tissues. An MRI is more accurate than either CT or ultrasound in the delineation of possible tumor involvement of the vena cava.⁹¹

Goldfarb et al⁹¹ studied the accuracy of MRI for demonstration of vena caval tumor thrombi in a group of 20 patients, 18 of whom had associated RCC. The patients underwent surgical exploration during which the presence of the vena caval thrombus was confirmed. Magnetic resonance imaging was able to accurately determine the presence and extent of the thrombus in all patients studied, with results better than those associated with venacavography or CT. Goldfarb and colleagues indicated that MRI not only has the advantage of being a noninvasive, noncontrast procedure, but also is cost-effective. They recommended this technique as the preferred imaging modality when clinical presentation or preliminary radiographic study suggests vena caval involvement.

Arteriography, another useful modality for evaluation of a space-occupying renal mass lesion, may provide anatomic information of significant value, such as highlighting of the renal capsular vasculature, new blood vessel formation, and tumor-related fistula formation. Because renal arteriography provides a relatively clear picture of the vascularity associated with a space-occupying renal mass lesion, it is of particular value to the surgeon in removing a

tumor mass or performing a partial nephrectomy. Arteriography has additional value as a diagnostic tool in elucidating the identity of small renal lesions.⁹² The technique is generally safe and involves relatively little discomfort for the patient.

An inferior venacavogram provides excellent information regarding the presence and degree of tumor involvement of the vena cava, thus providing the surgeon with meaningful information in planning the operative approach.⁹³ However, as previously mentioned, MRI is as accurate as inferior vena cavography in this regard and has the added advantage of being noninvasive.

The evaluation of renal masses by percutaneous biopsy has recently been reviewed by Herts and Baker.⁹⁴ They cite that the recent increase in the detection of small renal masses through the popular use of abdominal CT has created an increasing role for percutaneous biopsy in differentiating metastatic disease, lymphoma, or a renal abscess when clinical radiographic evidence suggests a diagnosis other than primary RCC. Percutaneous biopsy may also differentiate a renal metastasis of an established primary nonrenal tumor from a coexisting primary RCC. Fine-needle aspiration biopsy of renal masses may be used in patients with suspected disseminated metastatic disease, unresectable renal tumors, or other conditions in which surgery may be contraindicated. Importantly, Herts and Baker cited that fine-needle aspiration biopsy can provide an accurate histologic diagnosis of a low-grade primary renal tumor, allowing for continuing patient follow-up without surgical intervention. Finally, fine-needle aspiration biopsy may be used for nuclear grading of tumors before conservative surgery.

Currently in the United States, fine-needle aspiration biopsy is commonly carried out using CT guidance. Although percutaneous fine-needle aspiration biopsy of renal masses is considered a generally safe procedure, complications may occur, such as bleeding (the most frequent complication), tumor seeding along the needle tract, and pneumothorax (which may occur when using a posterior approach for upper renal pole lesions).

TREATMENT

Surgical Therapy

Nephrectomy. For patients presenting with stage I or II RCC, surgical excision is the only effective

therapy.⁹⁵ Radical nephrectomy incorporates removal of the entire Gerota's fascia, including the kidney and adrenal gland. The surgical approach employed depends on several factors, including the position and size of the tumor.⁹⁶ Lymphatic sampling or regional lymphadenectomy may be carried out for purposes of staging. In those patients presenting with bilateral RCCs or the presence of a neoplasm in a solitary kidney, nephron-sparing surgery involving tumor enucleation is commonly employed.

Nephron-sparing surgery is increasingly used in the management of both small unilateral RCCs and incidentally detected unilateral solid renal masses possessing characteristics suggestive of RCC.⁹⁷⁻¹⁰¹ Nephron-sparing surgery is emerging as a successful treatment for patients with localized RCC when the need exists to preserve functioning renal parenchyma. This need is often present in patients with bilateral RCC, RCC involving a solitary functioning kidney, chronic renal failure, or unilateral RCC and a functioning contralateral kidney that has been affected by an intercurrent condition such as renal artery stenosis, pyelonephritis, nephrosclerosis, nephrolithiasis, or diabetes mellitus. Licht et al¹⁰⁰ have reviewed the experience at the Cleveland Clinic involving the outcome of nephron-sparing surgery in 216 patients with sporadic RCC operated on between 1956 and 1992. They found that in comparison with those found in suspected RCC cases, RCC tumors found incidentally were smaller, more often unilateral, and of lower pathologic stage. Moreover, incidentally discovered tumors were associated with significantly improved 5-year cancer-specific survival and a lower rate of postoperative recurrence. The study also demonstrated that overall 5-year cancer-specific survival rates were improved among patients with stage I RCC compared with higher-stage disease, unilateral disease as opposed to bilateral disease, the presence of a solitary tumor versus multiple tumors in the operated kidney, and tumors < 4 cm compared with larger tumors. In summary, the study indicated that radical nephrectomy and nephron-sparing surgery may each afford effective curative therapy for patients presenting with a single, unilateral, small, localized RCC. However, the long-term renal functional advantage associated with nephron-sparing surgery in the presence of a normal contralateral kidney is uncertain. For those patients with tumors > 4 cm or in the presence of multiple, local RCC tumors, radical nephrectomy should be considered the current

treatment of choice.

Physiologically, as little as 15% to 20% of one kidney¹⁰² may satisfactorily preserve overall renal function. Temporary renal dialysis may be required, however, during the early postoperative period if the physiologic function of the remaining renal tissue is suboptimal. As the process of compensatory renal hypertrophy takes place, however, there is a gradual return of renal function, often most pronounced during the first 3 months following surgery. Novick noted that successful partial nephrectomy has been associated with 5-year survival rates approaching 80%.¹⁰² Novick agreed with Licht et al^{100,102} that partial nephrectomy is a subject of controversy in unilateral RCC patients with a normal contralateral kidney and no intercurrent disorder that might impair the function of that kidney. Thus, the indications for partial nephrectomy in patients with a normal contralateral kidney are not yet established, and radical nephrectomy is still the treatment of choice for such patients.

Percutaneous angioinfarction. The technique of preoperative percutaneous angioinfarction in selected RCC patients with large, highly vascular tumors has encompassed the use of a broad range of agents, including ethanol, inflatable balloons, microspheres, and gelatin sponges.¹⁰³ Preoperative angioinfarction is generally not considered a requirement for the safe surgical resection of RCCs, but it may permit the easier surgical removal of large bulky tumors and may have a place in the control of bleeding and pain from the primary tumor site in patients with advanced disease. In that situation, angioinfarction would be essentially a palliative tool for patients with tumors amenable to such therapy.¹⁰⁴

Cardiopulmonary bypass and removal of vessel thrombus. In patients with stage IIIA disease and major vein involvement, cardiopulmonary bypass (CPB) and removal of the vena caval thrombus may be indicated. In the Cleveland Clinic study conducted over a 5-year period,¹⁰⁵ 43 patients with large vena caval tumor thrombi underwent surgical treatment with CPB and deep-hypothermic circulatory arrest. Among the 43 patients, 39 had RCC. In this group of patients, the time of circulatory arrest ranged from 10 minutes to 44 minutes, with a mean of 23.5 minutes. The primary tumor and vena caval thrombus were completely removed in all patients. Novick et al reported that the 3-year survival rate following surgical removal of nonmetastatic RCC with an inferior vena caval tumor thrombus was

63.9%, whereas the 3-year survival in metastatic RCC patients was only 10.9%.¹⁰⁵ This study demonstrated that deep hypothermic circulatory arrest is a safe and effective approach, with hemorrhage necessitating surgical re-exploration (the most common postoperative complication) occurring in only four of 43 patients. Novick and colleagues also concluded that deep hypothermic circulatory arrest with CPB facilitates surgical removal of retroperitoneal tumors with large vena caval thrombi, thereby offering the possibility of cure with low morbidity and mortality rates.

A review of the long-term outcome in 18 patients who, between 1984 and 1993, underwent complete surgical excision for localized RCC and an intra-atrial tumor thrombus¹⁰⁶ permits the conclusion that long-term survival after such a surgical approach is possible. In this group of patients with localized RCC and an inferior vena caval tumor thrombus, the cephalad extent of inferior vena caval involvement did not appear to be of prognostic significance. Long-term follow-up revealed overall and cancer-specific 5-year survival rates of 57% and 60%, respectively.

Use in metastatic disease. Approximately one third of RCC patients will exhibit metastatic disease at the time of initial presentation, and as many as 40% of the rest will eventually develop distal metastases.³ Among those patients exhibiting metastatic disease, only a very small percentage will present with a solitary metastasis.¹⁰⁷ Those patients exhibiting a solitary metastasis in the presence of a primary RCC have decreased survival compared with those who apparently develop metastatic disease following surgical removal of the primary renal mass.^{108,109} Utz's group¹⁰⁹ studied surgical treatment of RCC patients with a coexisting primary renal mass and a solitary metastasis. Among the nephrectomized patients who subsequently developed a metastasis, 23% survived for longer than 5 years following surgical removal of the metastatic lesion and several patients exhibited long-term survival, which is generally an uncommon occurrence.¹⁰⁹

Surgical therapy of RCC is generally contraindicated in the presence of multiple distant metastases. However, in the situation where advanced RCC is present and the patient is symptomatic, palliative nephrectomy might be a therapeutic option if there is a significant chance that the tumor is in fact resectable. As Linehan et al⁴ cite, palliative nephrectomy is performed frequently in patients

with metastatic RCC, especially in those exhibiting pain, hemorrhage, malaise, hypercalcemia, erythrocytosis, or hypertension. The goal of nephrectomy in this setting is not to induce spontaneous tumor regression, which is extremely rare, but rather to diminish tumor burden and associated symptoms or to prepare for treatment with other agents.

Surgery in patients with metastatic RCC may, however, have more than a palliative role, particularly in patients presenting with or developing solitary metastatic sites where aggressive surgical procedures may be of value. Recently, with the advent of biologic therapy for patients with metastatic disease, approaches employing biologic agents combined with surgery are being explored.¹¹⁰ In selected patients with metastatic disease who respond partially to combination therapy with such agents as recombinant human interleukin-2 (rHuIL-2) and interferon alfa (rHuIFN- α), evidence tentatively suggests that resection of residual disease may be of value.^{111,112} In patients with primary tumors and metastatic disease, the use of nephrectomy before or following administration of other therapy has been explored.

Rackley et al report that treatment of metastatic RCC with biologic response modifiers (BRMs) and cytoreductive surgery has resulted in durable clinical responses,¹¹³ but the optimal schedule of immunotherapy and surgery has not been determined. At present, there has been no definitive determination of the relative efficacy of initial cytokine treatment versus initial nephrectomy. Nevertheless, it is likely that cytoreductive surgery will be carried out more frequently as an adjunct to immunotherapy in the treatment of patients with RCC, under the rationale that diminished host immune response exists in the presence of excessive tumor burden.⁹⁷ Despite current interest, it is clear that prospective well-designed clinical studies are essential to confirm the role of surgery in the setting of biologic therapies for RCC.

The results of surgical therapy for RCC are related to disease stage. In terms of the influence of nephrectomy on outcome for patients with stage I or II RCC, complete excision of localized lesions results in a 50% to 80% 5-year survival rate.¹⁰⁴ Patients exhibiting tumor extension into the inferior vena cava without regional lymph node involvement and in whom the primary tumor mass is restricted to the renal parenchyma (stage IIIA) experience a cure rate approaching that of stage I or

II disease when successful radical nephrectomy includes complete removal of the caval thrombus.¹⁰⁴ The 5-year survival rate is considerably less (Table 3) when regional nodes are involved (stage IIIB). Finally, in the situation where synchronous bilateral RCC occurs or where cancer is present in a solitary remaining kidney (approximately 2% to 3% of RCC cases), partial nephrectomy with preservation of the functioning renal tissue is typically advised. In the absence of distant metastases in such patients, complete surgical removal of the tumor is associated with a 70% to 80% tumor-free survival rate 3 to 5 years after surgery.¹⁰⁴

Radiotherapy

During the past 25 years, only a handful of reports have been presented on the result of nephrectomy with and without adjuvant radiation therapy for RCC,^{108,114-118} involving a total of 724 patients. While such a number of patients might ordinarily suffice to draw definitive conclusions on the merit of a specific treatment in carefully controlled clinical trials, the reports in this area unfortunately are inconclusive because of the great variability in experimental design and administered dose of radiation therapy. Among these studies, only one¹⁰⁸ suggested the superiority of nephrectomy plus radiation therapy over nephrectomy alone. However, as the 190 patients evaluated were not randomized and the dose of radiation therapy was not specified, it is difficult to draw conclusions from this report. Postoperative irradiation was associated with extremely severe and sometimes fatal complications in two of the published reports.^{114,116} Thus, the results of published studies do not support a role for radiation therapy in the management of early stage RCC. Radiation therapy does appear, however, to have a role in the management of advanced-stage RCC patients. In this group it may be employed to control bleeding and pain from primary tumor sites and also to diminish symptoms associated with bone or central nervous system metastases.^{119,120}

Chemotherapy

Multiple studies carried out during the 1980s clearly demonstrated that RCC is a chemotherapy-resistant tumor.¹²¹⁻¹²⁴ In fact, Yagoda, in his review of 39 agents tested in phase II trials over a 6-year period,¹²³ disclosed an objective response rate of less than 9%, usually of limited duration. His data reflected collective results on over 3000 patients

between 1983 and 1989. The cellular and molecular mechanisms that account for the remarkable refractoriness of RCC to chemotherapy have not been elucidated. However, it is possible that this phenomenon is in part attributable to the expression of the multidrug resistance (MDR)-associated p-170 glycoprotein on the surface of RCC cells.¹²⁵ Overexpression of the human multidrug resistance gene 1 (MDR-1), which encodes a 170-kilodalton membrane glycoprotein, sometimes referred to as P-glycoprotein, appears to provide a mechanism for the extrusion of selected chemotherapeutic agents from the cancer cell.¹²⁵ Goldstein et al¹²⁶ have reported that the MDR-1 gene is overexpressed in a high percentage of human RCC specimens. Among the chemotherapy agents formerly considered to have potential merit in the treatment of RCC, vinblastine appeared to be the most promising. In Harris' review, the overall response rate for vinblastine was approximately 25%.¹²¹ However, because his review incorporated the results of early clinical trials employing variable response criteria, the 25% estimate is probably excessive. In contrast, the results of studies conducted at Sloan-Kettering Cancer Center demonstrated an overall response rate of less than 10% for vinblastine.¹²⁷ The combination of vinblastine and other cytotoxic chemotherapeutic drugs not only has not improved response rates in RCC, but has also been associated with substantial increases in toxicity.¹²¹ The recognition that refractoriness of RCC to chemotherapy may in part be related to overexpression of MDR-1 has prompted several investigations employing MDR modifiers. These clinical trials have included combinations of vinblastine with oral cyclosporin A¹²⁸ or PSC 833,¹²⁹ both of which reverse MDR in vitro. Clinical tumor regressions have been noted,¹²⁹ but the overall effectiveness of this approach requires additional study. Finally, recent studies involving newer agents such as suramin,¹³⁰ methyl-GAG and melphalan,¹³¹ and vinorelbine tartrate^{132,133} have demonstrated no substantial activity of these agents in RCC patients.

Von Roemeling and Hrushesky¹³⁴ carried out murine and human clinical studies to determine whether circadian rhythms would influence the therapeutic indices of cytotoxic agents such as floxuridine (FUDR). Using their circadian-fashioned infusion protocol, they were able to show that diminished toxicity at similar daily dosing could be achieved. When this circadian-adjusted protocol

was applied to RCC patients undergoing continuous intravenous (IV) FUDR administration, they found that drug delivery was substantially limited by adverse effects such as nausea, vomiting, and diarrhea. Nevertheless, the protocol resulted in four complete responses (CRs) and seven partial responses (PRs), representing a combined response rate of approximately 20%, with a median response duration of almost 11 months. Dexeus et al¹³⁵ also employed a circadian infusion of FUDR and achieved a 10% PR rate in 42 metastatic RCC patients. Additionally, preliminary results reported by Damascelli et al¹³⁶ noted an improved survival in patients receiving continuous systemic infusion of FUDR compared with untreated historical controls. Collectively, these rather small trials suggest that circadian-adjusted FUDR infusion protocols may be of value in selected metastatic RCC patients, and randomized studies examining this question are underway.

Hormonal Therapy

The use of hormonal therapy in the treatment of metastatic RCC has yielded disappointing results.¹²¹ It was originally believed that progestational agents would be useful based on their ability to inhibit the growth of diethylstilbestrol-induced renal cancers in Syrian hamsters.¹²¹ Unfortunately, the collective experience with medroxyprogesterone acetate, as well as androgens and antiestrogens, has repeatedly demonstrated that preclinical models of RCC do not consistently correlate with the situation in humans.¹²¹ Even though initial clinical trials on the use of progestins in RCC provided optimistic data, more recent trials using modern objective response criteria have demonstrated an overall response rate of less than 5%.¹²¹ Despite the early enthusiasm for the use of medroxyprogesterone acetate in the treatment of RCC, it is reasonable to conclude that this agent has no value in this disease.¹³⁷

Immunobiologic Therapy

The use of immunobiologic therapies (Table 4), in particular rHuIFN- α , rHuIL-2, and combinations of these agents, represents an encouraging pathway for the treatment of RCC.¹³⁸⁻¹⁴⁹ Observations that metastases may regress following nephrectomy, perhaps reflecting the development and/or enhancement of the patient's immune response,¹³⁹ formed the basis for the interest in immunotherapy for RCC. Although such spontaneous regressions are

TABLE 4
PRINCIPAL AGENTS USED IN THE IMMUNOBIOLOGIC THERAPY OF RENAL CELL CARCINOMA

Interferons (alfa, beta, gamma)
Interleukins (IL-2)
Lymphokine-activated killer (LAK) cells
Tumor-infiltrating lymphocytes (TILs)
Autologous peripheral blood lymphocytes (activated with anti-CD3 antibody)

considered rare, they are still viewed as providing a rationale for the use of immunotherapy in RCC.¹⁴⁶ Support for an immune mechanism to explain such spontaneous regression is provided by the observation that tumor-infiltrating lymphocytes (TIL) can be detected in RCC tissue.¹⁵⁰ Recent studies in these patients^{150,151} have demonstrated the existence of specific cytotoxic T cells within the TIL population. Collectively, these and other data provide a potent rationale for the use of BRMs in the treatment of metastatic RCC patients. During the past decade, the most popular BRMs used in RCC have been cytokines belonging to the interferon and interleukin families. Encouraging evidence of their potential value in this disease have heightened interest in the molecular immunology of RCC. Much, however, needs to be learned about the cellular immunology of RCC. The existence of specific cytotoxic T lymphocytes (CTLs) suggests the presence of antigens responsible for their development. One recent study demonstrated human lymphocyte antigen-A2 (HLA-A2)-restricted recognition of a T-cell-defined antigen on autologous renal cancer cells.¹⁵² This antigen was also expressed and recognized in association with HLA-A2 on normal kidney cells in culture as well as other HLA-A2-positive tumor cells. The investigators propose that the target antigen may be a normal differentiation antigen for which tolerance may be incomplete. The antigen described in this study was found not only in major histocompatibility complex-matched RCC, but also in melanoma and tumors of epithelial origin. These investigators are now attempting to clone the gene coding for the epitope of interest to obtain additional information regarding the nature of target antigens in RCC.

TABLE 5
MAJOR PLEOTROPHIC
ACTIVITY OF INTERFERON ALFA

Antiviral protein expression (ie, endonuclease, 2-5-oligoadenylate synthetase)
Oncogene regulation (ie, <i>c-myc</i> , <i>c-fos</i>)
Cell cycle regulation
Immunoregulatory
Monocyte/macrophage activation
Increased natural killer (NK) cell activity
Induction of cell-surface antigen expression
Enhanced cytotoxic T-lymphocyte activity

Interferons. The first cytokines to be used for therapeutic purposes were the interferons, which were discovered approximately 35 years ago.¹⁵³ The interferons comprise a family of inducible cellular glycoproteins separable, depending on antigenic type, into three major groups: alfa (α), beta (β), and gamma (γ). The interferons possess antiproliferative, immunomodulatory, and antiviral characteristics, with significant differences among the three types. The original leukocyte-derived interferon was a mixture of IFN- α species produced by lymphocytes, lymphoblasts, and macrophages in response to viruses, foreign cells, and certain mitogens.¹⁴⁸ Interferon beta (IFN- β), also called fibroblast interferon, derives from fibroblasts or epithelial cells stimulated with natural or synthetic double-stranded RNA. Interferon alfa (which consists of 21 subtypes) and IFN- β are collectively referred to as type I interferons and they share a common cell-surface receptor. Interferon gamma (IFN- γ) is produced by T lymphocytes following their activation by a variety of antigens or cytokines. Interferon gamma appears to act on different cell-surface receptors than those shared by IFN- α and IFN- β .¹⁴⁸ In vitro IFN- α and IFN- γ demonstrate synergistic activity, probably due in part to the fact that they act on different cell-surface receptors.¹⁵⁴

Interferon alfa. The alfa interferons include a family of related proteins that are coded by up to 13 different genes on human chromosome 9 in leukocytes and monocytes.¹⁵³ The availability of recombinant DNA methodology has permitted the commercial production of purified interferons. Two of these commercial forms of rHuIFN- α available in the United States differ by only a single amino acid

at the number 23 position: lysine in recombinant human interferon alfa-2a (rHuIFN- α 2a; Roferon[®]-A, Roche Laboratories, Nutley, NJ) and arginine in recombinant human interferon alfa-2b (rHuIFN- α 2b; INTRON[®]-A, Schering-Plough, Kenilworth, NJ). Interferons initiate their biologic effects following binding to specific cell-membrane receptor sites. After receptor binding occurs, the interferon-receptor complex is internalized and the receptor itself is returned to the cell surface.¹⁵³

Interferon alfa has been shown to possess significant anticancer activity as well as relatively broad-spectrum antiviral activity (Table 5). The mechanism of IFN- α 's action as an antiviral agent may involve expression of specific antiviral proteins such as endonuclease and 2-5-oligoadenylate synthetase, enzymes that enhance the destruction of viral RNA.

The mechanism of IFN- α 's action as an anticancer agent remains unclear. It is appreciated that following internalization to the intracellular compartment, IFN- α affects a variety of biochemical processes via an effect on the expression of multiple genes. Interferon alfa inhibits the *c-myc* and *c-fos* oncogenes, as well as the gene for the enzyme ornithine decarboxylase. The potent inhibition of this enzyme may partly explain IFN- α 's effect on cell-cycle slowing and the arrest of cell division during G₀ phase.¹⁵³ The interferons also possess a variety of immunoregulatory characteristics, including activation of macrophages and monocytes, increased natural killer (NK) cell activity, induction of specific antigen expression on cell surfaces, and enhancement of CTL activity.¹⁵³ The favorable effect of rHuIFN- α in cancer therapy may reflect multiple levels of activity, including inhibition of protein synthesis, immunologic enhancement, and direct suppressive effects on selected oncogenes. Nanus et al¹⁵⁵ described a relationship between the clinical efficacy of rHuIFN- α and the specific expression of a 160-kd kidney-associated differentiation glycoprotein (gp) in RCC cell lines in vitro as well as in animal xenograft models. Renal cell lines expressing this glycoprotein (gp160) appear to be IFN- α resistant; by contrast, those that do not express gp160 appear to be IFN- α sensitive.

The earliest reports of successful treatment of metastatic RCC using IFN- α were published in 1983.^{156,157} Some features of metastatic RCC suggested responsiveness to immune modulation and, as a result, RCC has become an important clinical

model for the development of a variety of biologic approaches to the treatment of cancer. In early studies of the treatment of metastatic RCC using partially purified human leukocyte interferon,^{156,157} objective combined clinical responses (CRs plus PRs) were documented in as many as 26% of patients.¹⁵⁶ These encouraging initial reports provided a basis for multiple phase II trials of IFN- α in the treatment of RCC. Subsequent studies using partially purified IFN- α also provided evidence of a small but consistent clinical response.¹⁴⁸ In six separate studies reported between 1983 and 1985, using the partially purified IFN- α in a total of 141 metastatic RCC patients,¹⁵¹ 26 patients (18%) exhibited a response. Among these, six were CRs and 20 were PRs.

During the mid-1980s, a number of studies were conducted involving the administration of human lymphoblastoid interferon, which is obtained from a transformed lymphoid cell line and contains eight species of IFN- α . Collectively, 398 metastatic RCC patients were treated with this agent, yielding a response in approximately 15% of patients, including four patients with CRs and 57 patients with PRs.¹⁴⁸ From these studies it was concluded that IFN- α has a role in the treatment of metastatic RCC, and that the purity of the interferon preparation did not appear to significantly affect the clinical response rate. Clinical responses did appear to correlate with good performance status, a long disease-free interval, previous nephrectomy, and the presence of lung-predominant disease.¹⁴² Median durations of response averaged between 6 and

10 months; however, a few patients had long-lasting CRs. Also, when taken as a whole, these studies demonstrated that the frequency of a favorable clinical response was only partly dose-dependent. Treatment with intermediate doses of rHuIFN- α (3 to 10 million International Units [MIU]/d) appears to be more effective than treatment with a lower dose (< 3 MIU/d) or a higher dose (> 10 MIU/d).¹⁵⁸ Further, the route of administration was important, with subcutaneous (SC) or intramuscular (IM) administration ordinarily providing a better response rate than IV administration.¹⁴⁸

The early studies involving crude, partially purified IFN- α and human lymphoblastoid interferon

TABLE 6
CLINICAL STUDIES OF RECOMBINANT HUMAN INTERFERON ALFA (rHuIFN- α)
IN THE TREATMENT OF RENAL CELL CARCINOMA

Study	No. Assessable Patients	rHuIFN- α Regimen (Dose \times 10 ⁶ IU)	No. CR	No. PR	Percent CR + PR
Minasian et al ¹⁶⁵	149	50/m ² IM TIW or 3 \rightarrow 36 SC qd	2	14	11
Krown et al ¹⁷⁴	19	50 IM TIW	—	2	11
Einzig et al ¹⁷⁰	24	3 \rightarrow 36 IM	—	2	8
Quesada et al ¹⁵⁹	41	20/m ² qd IM	1	11	29
	15	2/m ² qd IM	—	—	0
Umeda and Nijijima ¹⁶⁶	108	3 \rightarrow 36/m ² qd IM	2	13	14
Schnall et al ¹⁶⁷	22	3 \rightarrow 36 qd IM	—	1	5
Kempf et al ¹⁶⁹	10	2/m ² TIW SC	—	—	0
Sarna et al ¹⁶⁸	19	3 \rightarrow 36 qd IM	1	4	26
Otto et al ¹⁷⁵	8	18 TIW IM	—	1	12
Steineck et al ¹⁷¹	30	10 \rightarrow 20/m ² TIW IM	1	1	6
Marshall et al ¹⁶²	17	10 ³ qd SC	—	4	24
Umeda and Nijijima ¹⁶⁶	45	3 \rightarrow 36 IM	1	7	18
Muss et al ¹⁶⁴	46	30 \rightarrow 50/m ² 5 \times /wk q 3 wks IV	1	2	7
Muss et al ¹⁶⁴	51	2-10/m ² TIW SC	1	4	10
Levens et al ¹⁷²	15	10 qd SC	1	3	27
Bono et al ¹⁶³	61	3/m ² TIW SC	2	3	8
Creagan et al ¹⁷³	87	20/m ² TIW IM	1	6	8

Adapted from Wirth, reference 149, with permission

Abbreviations: CR = complete response; PR = partial response; IU = International Units; IM = intramuscular; TIW = three times per week; \rightarrow = dose escalation; SC = subcutaneous; qd = every day; IV = intravenous

generated sufficient enthusiasm to accelerate the commercial development of purer IFN- α utilizing recombinant DNA technology. Virtually all recent studies of IFN- α in patients with metastatic RCC have involved a recombinant-derived product. Clinical response rates with rHuIFN- α are essentially the same when using different preparations and, when taken collectively, a review of phase I and phase II clinical trials on rHuIFN- α indicates an overall objective clinical response rate of approximately 17%.¹³⁹ Nevertheless, response rates reaching 29%, including occasional CRs, have been reported.^{139,159-175} A considerable number of patients have been enrolled in clinical trials of rHuIFN- α in RCC (Table 6).¹⁴⁹ The variability in the percentage of combined response rates may be explained in part by substantial differences in dosing schedules and patient eligibility criteria. Accordingly, it is not possible to confidently propose an optimal dosing regimen for rHuIFN- α monotherapy. This limitation notwithstanding, an objective review of the available published data suggests that a dose of 5 to 10 MIU/m² IM or SC either daily or three to five times per week appears to provide comparatively good results. Moreover, chronic dosing is generally better than intermittent high doses. Ordinarily, the average latency period of a discernible clinical response to rHuIFN- α administration is approximately 3 months, and the duration of the achieved remission seldom exceeds 2 years.¹⁴⁴ In his review of immunotherapy for metastatic RCC, Wirth¹⁴⁹ cited that several groups of investigators believe that 2 to 3 months of rHuIFN- α administration may suffice to determine which particular patients will respond to treatment; thereafter, rHuIFN- α administration may be discontinued in nonresponders. In general, a median response duration of 6 to 10 months may be anticipated among patients who exhibit a clinical response to this agent. Also, objective clinical responses have been reported following administration of as little as 1 MIU/d SC.¹⁶² Marshall et al¹⁶² studied administration of daily low-dose rHuIFN- α (1 MIU/d SC), and found that treatment was well tolerated without interruption of therapy for toxicity. They also indicated that no patient experienced the flu-like symptoms commonly associated with higher doses. Moreover, they reported no episode of granulocytopenia or thrombocytopenia. Interestingly, with the low-dose regimen, one patient exhibited a PR that persisted for at least 20

months. Marshall and colleagues appropriately concluded that a low-dose rHuIFN- α regimen was well tolerated and could produce objective clinical responses in some patients. It should be taken into consideration that, regardless of the dose employed, the clinical response to rHuIFN- α may take several months to be manifested. Thus, considerations of tolerability as well as antitumor effects suggest a chronic dosing schedule rather than intermittent high doses. Overall, published studies on rHuIFN- α monotherapy in metastatic RCC clearly indicate that the agent has only limited activity in this disease, but that selected subpopulations of patients may exhibit favorable responses.

Interferon beta. In comparison with the clinical experience with rHuIFN- α , there is only limited data on the use of rHuIFN- β in the treatment of RCC. Few reports of studies with rHuIFN- β have been published.¹⁷⁶⁻¹⁷⁸ Collectively, only 56 patients were assessable; among those only one achieved a CR, whereas seven exhibited a PR. The combined response rates (CRs plus PRs) with rHuIFN- β in metastatic RCC ranged from 6% to 20%, differing very little from those obtained in studies on rHuIFN- α .

Interferon gamma. The experience with recombinant human interferon gamma (rHuIFN- γ) in RCC is also rather limited compared with that in rHuIFN- α . Clinical response rates of patients treated with rHuIFN- γ range from zero to 33%. This is not surprising given the great variability in treatment regimens employed as well as the considerable differences in patient selection criteria. More than 14 studies have been published in complete or abstract form on rHuIFN- γ treatment of RCC and have collectively included more than 320 assessable patients.^{149,175,179-191} In the study by Aulitzky et al,¹⁸⁴ 20 patients received 100 mg of SC rHuIFN- γ weekly and achieved two CRs and four PRs accounting for a combined response rate of 30%. Aulitzky and colleagues speculated that their results reflected "optimal" immunostimulation. The possibility that weekly low-dose SC rHuIFN- γ was an optimal BRM-modifying dose was reflected by alterations of various immune parameters indicating stimulation of cellular cytotoxicity by peripheral blood lymphocytes.^{184,191} Their approach,¹⁸⁴ incorporating the "biologically active dose" of rHuIFN- γ , produced two CRs of greater than 20 months' duration as well as four PRs that lasted from 6 to more than 24 months. It should be mentioned that in this study, patients

were selected for good prognosis, which certainly may have contributed to the comparatively favorable treatment results. Also, a favorable side effect profile permitted a long median treatment period of 10 months.

Ellerhorst et al,¹⁸¹ in a study conducted at The University of Texas M.D. Anderson Cancer Center, enrolled patients with metastatic RCC who were administered SC rHuIFN- γ weekly at a fixed dose of 100 mg. They reported that toxicity was limited to low-grade fever, chills, and myalgias within 4 to 8 hours after injection. Their preliminary abstract report documented a combined response rate of 11%. They concluded from their preliminary data that rHuIFN- γ administered under these conditions has activity and that the response rate appeared to compare favorably with that of other biologic agents. They proposed that rHuIFN- γ should be considered as a biologic agent for use in combination with other biologics or chemotherapeutic agents. In contrast, however, Heider et al,¹⁸² in their study of 25 patients treated with 100 mg SC rHuIFN- γ three times weekly, concluded that rHuIFN- γ administration according to this schedule and under these conditions had no significant activity in patients with metastatic RCC.

Barna et al¹⁸⁰ conducted a study in which they monitored the immunologic function of five patients who were enrolled in a phase II clinical trial of rHuIFN- γ for treatment of metastatic RCC. Their study demonstrated enhancement of immunologic function, including increases of spontaneous monocyte-mediated tumoricidal activity and NK cytolytic activity. The modest clinical efficacy of rHuIFN- γ and the alterations of immune functions found suggest it might have a greater effect when used in combination with other forms of cytokine or cytotoxic drug treatment. DeMulder et al¹⁷⁹ investigated this possibility in 31 patients with established progressive RCC who received SC rHuIFN- γ at 100 mg/m² (2 MIU/m²) and SC recombinant human interferon alfa-2c (rHuIFN- α 2c) at 6 mg/m² (2 MIU/m²) twice weekly. Two patients exhibited a CR and six patients achieved a PR for a combined response rate of 25%. The median duration of PR was 14 months, with a range of 8 to 16 months. DeMulder and colleagues also cited that of the two complete responders, one patient persisted with a CR for more than 23 months, whereas the other suffered a relapse after 22 months. In this study, the median time to response was 24 weeks

and the maximum tolerated dose of rHuIFN- α 2c was 30 mg/m². The toxicity observed was relatively similar to that reported by other researchers. The investigators cited that, although the overall response rate of 25% appeared favorable, the significance of adding rHuIFN- γ to the rHuIFN- α regimen remained unclear because the observed response rate was within the range found for the rHuIFN- α alone.

The results of clinical studies with rHuIFN- γ appear to justify further evaluation of this agent in the treatment of metastatic RCC. However, such studies should involve consistent and clearly formulated criteria for patient enrollment and evaluation as well as dosage regimen. Studies enrolling larger numbers of patients to treatment with rHuIFN- γ and comparing rHuIFN- γ with supportive care are underway. At the present time, the role of rHuIFN- γ in the therapy of advanced RCC is unclear.

Prognostic factors. Although it is not possible to precisely estimate the likelihood of a favorable clinical response to interferon monotherapy, certain patient profiles appear to better predict the likelihood of successful responses. In general, patients are likely to exhibit a more favorable clinical response if they have good performance status, have had a nephrectomy, exhibit nonbulky pulmonary and/or soft-tissue metastases, and are asymptomatic or have minimal symptoms. By contrast, an unfavorable response is more likely to occur in those patients with unresected primary RCCs, extensive prior treatment, and bulky metastases to viscera or bone. In the clinical trial reported by Muss et al,¹⁶⁴ all responders to rHuIFN- α had prior nephrectomy, six of eight had no prior chemotherapy, none had bone metastases, and five had lung metastases. In this multicenter trial involving six institutions, a total of 97 patients with recurrent or metastatic RCC were randomized to receive rHuIFN- α 2b by either IV or SC routes. The IV dosage was 30 MIU/m² for 5 consecutive days every 3 weeks, whereas the SC dose was 2 MIU/m² three times per week. The overall response rate in this trial was only 8%, with two CRs and six PRs among the total enrolled trial population. However, the clinical responses obtained were frequently of long duration; for instance, six of eight lasted longer than 1 year and the median duration was 16 months. The response rates were similarly low for both routes of administration, but toxicity was substantially higher when using the IV route. One of the notable findings in this study was

that a subgroup of patients with prior nephrectomy, no prior therapy, and absence of bony metastases displayed a combined response rate of 23%.

In a more recently published review from Sloan-Kettering Cancer Center,¹⁶⁵ 159 patients with metastatic RCC were treated with rHuIFN- α 2a in three separate trials. The investigators applied univariate and multivariate analyses to identify prognostic factors for survival. The results of these trials demonstrated an overall response rate of 10.7%. Median survival duration was 11.4 months, and the median response duration was 12.2 months. Notably, only 3% of patients were alive at 5 or more years. Among these five patients, three had been treated with rHuIFN- α for 6 years without undue toxicity. Statistical evaluation by univariate survival analysis disclosed that prior nephrectomy, Karnofsky performance status \geq 80% at initiation of therapy, and a diagnosis to treatment interval longer than 365 days were each significantly associated with prolonged survival. However, using the multivariate Cox model, only prior nephrectomy and Karnofsky performance status \geq 80% were found to be independent prognostic factors for long-term survival. The investigators noted that although rHuIFN- α 2a has a low level of antitumor activity, a small proportion of patients in these studies did achieve a long-term survival rate. Despite the frequency of constitutional side effects, administration of rHuIFN- α 2a was safely tolerated in an outpatient setting. Finally, the investigators indicated that the relationship between response to therapy and prolonged survival in the study could not be distinctly demonstrated and acknowledged that whether response to therapy leads to improved survival or simply identifies a group of patients with a better prognosis remains to be answered.

Monotherapy of metastatic RCC using rHuIFN- α appears to be well tolerated, and symptoms associated with toxicity disappear rapidly upon discontinuation of drug administration. The most commonly reported side effects consist of flu-like symptoms including fever, chills, and malaise. In addition, nausea and vomiting, gastrointestinal symptoms, weight loss, alopecia, and various cardiovascular and central nervous system (CNS) effects may occur. Constitutional symptoms may occur with considerable frequency. For example, Tsavaris et al¹⁶⁰ found that rHuIFN- α administration was associated with fever in 95% of patients, fatigue in 87%, anorexia in 80%, and the flu-like syndrome in 65% of patients.

Because the cellular and molecular mechanisms of action of interferon have not been fully elucidated, research is needed to clarify its pharmacology and to better delineate host characteristics that might enhance the efficacy of this agent. In addition, greater knowledge of the possible role of human leukocyte antigen expression and the potential clinical relevance of IFN- α antibodies may provide valuable information on potential host responses to interferon therapy, both in single-agent and multicomponent treatment regimens.^{192,193}

Chronic administration of rHuIFN- α may result in the formation of interferon antibodies. In the study of Prümmer et al,¹⁹³ in which patients received adjuvant rHuIFN- α 2a after complete RCC tumor resection, 47% of rHuIFN- α -treated patients developed IFN- α binding and 29% exhibited IFN- α neutralizing antibodies within a median period of 3 and 6 months, respectively. Prümmer and colleagues noted a distinct peak in binding antibody titers between 6 and 9 months. In this study, IFN- α binding antibody titers decreased and, in some cases, even disappeared despite continuation of interferon administration. The immunologic explanation for such an event is unclear. In this study, the rHuIFN- α 2a-induced antibodies were equally reactive with all rHuIFN- α 2 subtypes, suggesting that in such instances it may not be useful to substitute other recombinant subtypes for rHuIFN- α 2a. By contrast, therapy-induced neutralizing antibodies only poorly recognized natural IFN- α , rHuIFN- α 1/ α 8, and recombinant human interferon omega-1. The authors state that the high frequency of rHuIFN- α 2a antibodies in RCC is a matter of major concern. In this study, the duration of clinical remission and rate of relapse appeared to be independent of interferon antibody status, although neutralizing and most non-neutralizing antibodies appear to correlate with a reduction in the interferon-induced increase in β_2 -microglobulin levels. The authors conclude that RCC patients treated with rHuIFN- α 2a should be monitored for the presence and clinical relevance of IFN- α antibodies to determine those patients who might respond better to alternative interferon preparations or other treatments. Studies investigating the frequency of neutralizing antibody formation in RCC patients receiving rHuIFN- α 2b appear to demonstrate a decreased incidence of neutralizing antibodies when compared with those employing rHuIFN- α 2a. The clinical relevance of these differ-

ences in patients with metastatic RCC is unclear.

Additional studies of interferon therapy in RCC patients are required to investigate the potential mechanisms of response and to explore the reasons for differences in response among the various subgroups noted previously. Additionally, comparative trials comparing IFN- α monotherapy and/or cytokine combinations are required to determine the overall effects of such therapy on patient survival.

Interleukin-2. Interleukin-2 is a T-cell growth factor first described by Morgan et al¹⁹⁴ in 1976. It was initially used for the treatment of metastatic RCC in 1984 after in vitro and animal studies demonstrated its significant activity as an antitumor agent. Since then, this agent has been extensively tested in RCC patients at both low¹⁹⁵ and high doses,¹⁹⁶ both as monotherapy and in combination with other agents.^{139,142,149,197-215} In general, monotherapy of metastatic RCC using rHuIL-2 has demonstrated efficacy roughly equivalent to that of monotherapy with rHuIFN- α .^{139,142,149,197-215} One characteristic of both rHuIL-2 and rHuIFN- α studies is that considerable heterogeneity of design, dosage regimens, and patient entry criteria exist in the literature. Combined response rates (CRs plus PRs) range from zero to 31% (Table 7).¹⁴⁹ A review of published clinical studies using rHuIL-2 to treat patients with metastatic RCC disclosed an objective antitumor response in approximately 14% of patients.²¹⁶ The Food and Drug Administration approved rHuIL-2 in 1992 for the treatment of metastatic RCC, and it became the first biologic to be approved for this disease. Recombinant human IL-2 is marketed as PROLEUKIN® (aldesleukin for injection; CHIRON Therapeutics, Emery, CA). Approval was based in significant part on the results of clinical studies involving 255 patients who were treated with high-dose, rHuIL-2 monotherapy at 21 different institutions.²¹⁷

Fyfe et al²¹⁸ described the results in these 255 assessable patients entered into seven separate phase II clinical trials involving rHuIL-2 administered at a dose of 600 000 or 720 000 IU/kg by 15-minute IV infusion every 8 hours over 5 days or as tolerated. Patients were scheduled to receive a second identical treatment cycle following 5 to 9 days of rest, and treatment courses were to be repeated each 6 to 12 weeks for stable or responding patients. Their report revealed an overall objective combined response rate of 14%, with 5% CRs and 9% PRs. Fyfe and colleagues indicated that responses occurred in all dis-

ease sites including intact primary tumors and bone and visceral metastases. Although they mentioned that the median response duration for patients achieving a CR has not yet been reached, that value was 19.0 months for patients achieving a PR. When taken collectively, the baseline Eastern Cooperative Oncology Group (ECOG) performance status was the only prognostic factor predictive for response to rHuIL-2. The investigators appropriately cited that, during the 5 years encompassed by their series of clinical trials, a great deal had been learned about patient selection and clinical management. They mentioned that routine screening with exercise or thallium testing and pulmonary function testing had led to the exclusion of high-risk patients with pre-existing cardiopulmonary disease. They indicated that the importance of selecting patients with a good performance status had also become more apparent. The investigators concluded that high-dose rHuIL-2 appeared to benefit some patients with metastatic RCC, as reflected by durable CRs or PRs. They proposed that despite severe acute treatment-associated toxicities, rHuIL-2 is to be considered for initial therapy of appropriately selected patients with metastatic RCC.

Recombinant human IL-2-associated toxicity is dose-dependent and is believed to result from increased capillary permeability leading to fluid retention, interstitial edema, hypotension, decreased peripheral vascular resistance, increased cardiac index, tachycardia, and oliguria.¹³⁹ In addition to these toxicities, renal complications may be observed in association with rHuIL-2 therapy and are believed to result from prerenal azotemia; these complications are generally reversible upon discontinuation of rHuIL-2 administration. A variety of other adverse experiences associated with rHuIL-2 administration²¹⁹ include nausea, vomiting, stomatitis, diarrhea, anorexia, gastrointestinal hemorrhage, skin rashes, agitation, disorientation, hallucinations and other CNS complications, fever, chills, hematologic toxicity, sepsis, and other side effects. Even though most of these adverse experiences attributed to toxicity of rHuIL-2 are completely reversible upon discontinuation of drug administration, patients treated with the high-dose schedule should have documented normal cardiopulmonary, liver, hematologic, renal, and CNS function. Since this patient profile is not consistently encountered, it is incumbent upon the treating physician to assure diligent clinical monitoring during treatment with

TABLE 7
CLINICAL STUDIES OF RECOMBINANT HUMAN INTERLEUKIN-2 (rHuIL-2)
MONOTHERAPY OF RENAL CELL CARCINOMA

Study	No. Assessable Patients	rHuIL-2 Regimen (Dose × 10 ⁶ IU)	No. CR	No. PR	Percent CR + PR
Rosenberg ²⁰⁴	38	0.1/kg IV q 8hr × 5d, 2-wk cycle	4	3	18
Whitehead et al ²⁰⁵	12	3→6/m ² /d 5d/wk	—	1	8
Sosman et al ²⁰⁶	23	1-3/m ² /d IV 4d/wk × 4wk	—	3	13
Marumo et al ²⁰⁷	13	0.5 IV, bid × 28d 1 SC, qd 6 × wkly	2	1	23
Negrier et al ²⁰⁸	32	18/m ² , d1-5 and 12-16 3-wk intervals	2	4	19
Bukowski et al ²⁰⁹	41	60/m ² IV, TIW	1	4	12
Geertsens et al ²¹⁰	30	18/m ² IV, d1-5 1-wk intervals	2	4	20
Lissoni et al ²¹¹	13	9/m ² SC, q 12hr × 2d 1.8/m ² d3-7	—	4	31
von der Maase et al ²¹²	51	18/m ² IV, d1-5 and 12-15 3-wk rest	2	6	16
Negrier et al ²¹³	22	18/m ² /d IV d1-5 and 12-15	2	1	14
Perez et al ²¹⁴	12	18-72/m ² IV q wk × 16wk	1	1	17
Vlasveld et al ²¹⁵	9	0.18-9/m ² IV, × 7d	—	—	0
Lissoni et al ¹⁹⁹	48	6 SC, qd d1-5 × 6wk	1	13	29
Rosenberg et al ²⁰³	149	0.72/kg IV bolus, q 8 hr 2 Tx cycles, maximum 15 doses	10	20	20
Buter et al ²⁰⁰	46	18 SC, qd d1-5 then dose reduction 4 or 6 wks consecutive Tx	2	7	20

Adapted from Wirth, reference 149, with permission

Abbreviations: IU = International Units; CR = complete response; PR = partial response; q = every; IV = intravenous; → = dose escalation; bid = twice daily; SC = subcutaneous; TIW = three times per week; Tx = treatment

high-dose rHuIL-2 regimens. The rate of drug-related deaths among the 255 metastatic RCC patients receiving high-dose rHuIL-2 was 4%,²¹⁸ and more than half of patients so treated may require administration of vasopressors.²¹⁹

The most common major toxicities associated with rHuIL-2 administration have been oliguria and hypotension that frequently require administration

of low-dose dopamine and occasionally phenylephrine.¹⁹⁷ Yang et al¹⁹⁷ correctly cited that toxicities associated with rHuIL-2 have inhibited treatment of metastatic RCC patients with this agent except by groups with broad expertise in its administration. They also cited the fact that at present, many patients with metastatic RCC in the United States never receive rHuIL-2 therapy. This is despite the

fact that a significant minority might achieve long-term progression-free survival.¹⁹⁷

Intravenous administration. To compare the efficacy and possible toxicity of high-dose IV bolus rHuIL-2 with a low-dose regimen, Yang et al¹⁹⁷ evaluated 125 patients with metastatic RCC. These patients were randomized to receive rHuIL-2 via IV bolus every 8 hours at either a high dose (720 000 IU/kg) or a low dose (72 000 IU/kg) to the maximum tolerated number of doses or to a maximum number of 15 doses. In this clinical trial, 60 patients were randomized to receive low-dose rHuIL-2, whereas 65 patients were randomized to receive high-dose treatment. Patients who were administered the low-dose regimen achieved 7% CR and 8% PR rates, whereas those who received high-dose therapy achieved 3% CR and 17% PR rates. There were no treatment-related deaths in this study. The incidence of grade III or IV thrombocytopenia, hypotension, and malaise in patients in the high-dose treatment arm was greater than that recorded for patients receiving low-dose rHuIL-2 therapy. Interestingly, those who received the low-dose regimen experienced significantly more infections. The difference in requirement for vasopressor support between the two treatment arms was dramatic: 3% of treatment courses with low-dose rHuIL-2 required vasopressor administration, compared with 52% of courses with high-dose rHuIL-2. The investigators concluded that low-dose IV bolus rHuIL-2 is an effective regimen in metastatic RCC, and they cited that their preliminary results are comparable to those obtained using the high-dose rHuIL-2 regimen. Furthermore, they cited that the lower dose regimen can be administered with significantly fewer complications, including fewer admissions to an intensive care unit. They further concluded that the dose of rHuIL-2 employed in their clinical trial, 72 000 IU/kg, appeared to be the maximum dose of this agent that can be administered by IV bolus for up to 5 days without the need for vasopressor or intensive care unit support. Finally, Yang and colleagues indicated that the lower toxicity associated with the low-dose rHuIL-2 regimen could make this agent more readily accessible to a broader population of metastatic RCC patients. Comparisons of response duration and survival remain preliminary, and this group is now comparing these IV schedules with rHuIL-2 administered SC.

Subcutaneous administration. In addition to IV bolus administration, other routes for administra-

tion of rHuIL-2 have been examined. Sleijfer et al¹⁹⁸ carried out a phase II clinical study in the Netherlands to evaluate the efficacy and possible toxicity of SC-administered rHuIL-2 as a means of avoiding the toxicities and the resulting restrictive phase II study patient inclusion criteria associated with IV rHuIL-2. They also treated patients with advanced metastatic RCC who were otherwise not eligible for IV rHuIL-2 administration. In this single-institution phase II study, 27 unselected patients with metastatic RCC were treated in an outpatient setting with SC administration of rHuIL-2 once a day for 5 days each week for a duration of 6 weeks. The first 5-day treatment cycle involved 18 MIU rHuIL-2 given once daily. Thereafter, the doses in the first 2 days were reduced to 9 MIU. Then, following a 3-week rest period, the same treatment was repeated in those patients who exhibited a CR, a PR, or stable disease. After 6 weeks of treatment, 26 patients were considered assessable for clinical response. Among these, two patients (8%) achieved a CR, four patients (15%) achieved a PR, and 13 patients (50%) exhibited stable disease. In the two CRs, the duration of remission was greater than 17 and 19 months, respectively. Among the four PRs, the duration of remission ranged from 2 to more than 11 months. Overall, the median survival of patients was 13 months. Although transient inflammation and local induration at the injection sites occurred in all patients, it was not dose limiting and, in general, SC administration of rHuIL-2 in that clinical trial was well tolerated. Sleijfer and colleagues indicated that, following the termination of SC rHuIL-2 administration, the nodular lesions that resembled SC lipomas disappeared over a 3- to 6-month period.¹⁹⁸ They stated that this study suggests that SC-administered rHuIL-2 has significant antitumor activities in patients with advanced RCC and that the response rate in this study approximated reported response rates observed using IV rHuIL-2 administration. The SC administration of rHuIL-2 in this study also had an acceptable level of toxicity. Treatment-related side effects were limited among the unselected patients, although most patients experienced nausea and fever. Of great importance, capillary leak syndrome, renal toxicity, or hypotension were not reported. This study, although not large, provides compelling evidence to suggest that rHuIL-2 may be administered SC to patients with advanced RCC.

Several other recent publications are likewise noteworthy in regard to the use of SC rHuIL-2 in patients with metastatic RCC.¹⁹⁹⁻²⁰¹ Lissoni et al¹⁹⁹ studied 50 patients who received rHuIL-2 at a daily dose of 6 MIU for 5 days per week for 6 consecutive weeks. The overall response rate among these patients was 28%, with 1 patient achieving a CR and 13 achieving a PR. The investigators found that the response rate to rHuIL-2 administration was significantly higher among nephrectomized patients and among those with a good performance status. The toxicity of SC rHuIL-2 in these patients was low and did not require cessation of treatment or dose reduction. Principal side effects reported included fever, nausea and vomiting, and an increase in serum transaminase and/or gamma-glutamyl transpeptidase levels. Lissoni and colleagues commented that their clinical trial provided results confirming that SC rHuIL-2 monotherapy is not only efficacious but also well tolerated in patients with metastatic RCC. Finally, they concluded that their study demonstrates that SC rHuIL-2 is well tolerated in patients with compromised clinical status, and that this approach to therapy is capable of providing objective tumor responses comparable to those obtained with the commonly employed IV route of administration.

The report by Buter et al²⁰⁰ provides an update of that group's previous publication discussed above¹⁹⁸ and extends their findings to include the experience of treating 47 patients with SC rHuIL-2. The overall response rate was 20%, with 9 of 46 assessable patients achieving a clinical response to treatment. The response durations in the two patients who achieved a CR were 29 months and more than 35 months. Among the seven partial responders, the response durations ranged from in excess of 1 month to more than 28 months, with a median length of survival in all patients of 12 months. Interestingly, among the nine patients who exhibited a clinical response to SC rHuIL-2, four were 65 years old or older. The investigators were unable to establish a difference between nonresponders and responders in regard to prior nephrectomy, sites of metastasis, or performance status. Seven of nine responses occurred in lung metastases. Of particular value, this report appears to confirm prior observations that rHuIL-2 administration is effective in elderly patients. In general, the toxicities encountered in the elderly were comparable to those reported in younger patients with the exception of two individ-

uals who experienced cardiovascular toxicity. When taken in combination, these reports suggest that SC rHuIL-2 administration can be conducted safely on an outpatient basis or even managed by the patient at home with minimal requirement for nursing assistance. The SC route also appears to provide greater safety than the IV route which, in addition to the side effects discussed above, has been associated with an incidence of bacterial sepsis of approximately 25%,²⁰⁰ possibly related to the presence of a central venous catheter or a defect of neutrophil chemotactic function.²⁰⁰ With SC rHuIL-2, a low incidence of infection is observed making prophylactic antibiotic administration unnecessary.²⁰⁰

In summary, studies cited above demonstrate that low-dose SC rHuIL-2 provides benefit for certain patients with metastatic RCC with a generally tolerable and safe toxicity profile. The use of this SC administration route in elderly patients and in those with concomitant systemic disease provides an opportunity for effective therapy for a wide variety of patients. Accordingly, SC rHuIL-2 should be considered as a reasonable approach for patients with metastatic RCC, particularly as the use of SC rHuIL-2 is accompanied by clinical response rates approximating those obtained with high-dose IV bolus administration.²⁰³ It remains unclear, however, if response durability is equivalent for the IV and SC routes. Regardless of the dose of administration of this agent, however, SC administration is potentially fatal. Thus, it is crucial for the treating physician to exercise an exceptional degree of diligence in patient care to avoid any significant toxicity.

Continuous IV administration. The effects of monotherapy with rHuIL-2 delivered via continuous IV infusion (CIV) have been studied in a small group of trials conducted principally in Europe where CIV rHuIL-2 therapy is approved for marketing.¹⁴⁷ Complete response rates for this route of administration vary considerably, partly because of considerable differences in study design, and range from approximately 8% to 33%.¹⁴⁷ The administration of rHuIL-2 by CIV over a 24-hour period, one or two times per week, may allow the delivery of a much higher total cumulative dose to the patient without increased toxicity compared with CIV carried out over several days or more each week.⁴ As with SC administration, however, CIV delivery requires extremely close patient monitoring.

Summary. As seen, the optimal dose, schedule, and route for rHuIL-2 administration to metastatic RCC patients have yet to be defined in randomized trials. Overall response rate and incidence of CRs appear similar with IV bolus, CIV, or SC administration. Comparative data on response duration and overall survival are lacking however. The choice of dose and route is often dictated by patient factors and the treating physicians' familiarity with use of this cytokine.

The antitumor activity of IL-2 appears to reside in its ability to modulate the host's immunologic response, because, unlike interferon, it does not appear to possess direct antiproliferative activity against cancer cells. Interleukin-2 is a lymphocyte growth and activation factor that has a key role in the host's normal immune response. It appears to be quite capable of causing the production of lymphokine-activated killer (LAK) cells and expanding the population of T cells able to destroy target cancer cells.²²⁰ Although clinical responders among patients using rHuIL-2 monotherapy are still in the minority, numerous patients have achieved clinical responses that are unlikely to have occurred in the absence of this therapy.

Moreover, inspection of clinical trial results as reported above indicates that rHuIL-2 can in some instances produce a durable complete clinical response. Hellman cited in his recent editorial²²⁰ that CRs obtained in the study recently published by Rosenberg et al²⁰³ are best regarded as a "proof of principle" supporting the initial hypothesis that rHuIL-2 stimulates a host antitumor immune response, and can produce clinical tumor regression by this mechanism. Indeed, in the report from the National Cancer Institute on the use of high-dose bolus rHuIL-2 in the treatment of RCC patients¹⁹¹ CRs or PRs lasted in excess of 76 months and 69 months, respectively. The toxicities associated with rHuIL-2 administration differ in large part from those commonly encountered with cytotoxic chemotherapeutic agents. The comparatively minimal neutropenia and immunosuppression associated with rHuIL-2 indicate mechanisms of action different from those of chemotherapeutic agents now in use.

It should be kept in mind that patient response to rHuIL-2 is comparable to that of other treatment regimens employed in metastatic RCC. To exploit the potential of rHuIL-2 in the treatment of cancer, an improved understanding of the immune effector mechanisms involved will be required.

Combination Therapy

Recombinant human IL-2 and rHuIFN- α .

Preclinical models have demonstrated the synergistic antitumor effects of rHuIFN- α and rHuIL-2, establishing a compelling rationale for their combined use in the treatment of malignant disease.²²¹ Indeed, it has been postulated that the ability of the immune system to mediate antitumor activity may depend on a series of immunoregulatory signals instead of a solitary event.¹⁴² Accordingly, a combination of BRMs may have particular therapeutic merit. For instance, administration of interferon might augment the immunogenicity of tumor cells by enhancing their histocompatibility and tumor-associated antigens. This would render those tumor cells more vulnerable to IL-2-activated lymphocytes.¹⁴² Interest in the potential synergy between rHuIL-2 and rHuIFN- α has resulted in a variety of phase I and phase II clinical trials intended to determine whether the combination of these agents would have particular value in the treatment of patients with metastatic RCC.^{203,222-245} The features and results of some of these studies are shown in *Table 8*.

Clinical trials using combined rHuIFN- α and rHuIL-2 treatment have utilized a variety of routes of rHuIL-2 administration, including CIV, SC administration, and IV bolus injection. In addition, a wide range of dose levels of both rHuIL-2 and rHuIFN- α have been used. When taken collectively, the phase I and II clinical trials referenced above yield response rates of approximately 20% in patients with metastatic RCC. Palmer et al²²³ have recently published the results of a meta-analysis comparing two treatment modalities for patients with progressive, advanced disease, but with an ambulatory performance status. They collected data on 425 advanced RCC patients, among whom 225 were treated with CIV rHuIL-2 on an inpatient basis and 200 were treated with SC rHuIL-2 and rHuIFN- α on an outpatient basis.

The results of this study showed that the overall response rate for CIV rHuIL-2 was not significantly different from that of the SC rHuIL-2 plus rHuIFN- α treatment regimen. The combined objective response rate (CRs plus PRs) for patients receiving rHuIL-2 alone was 15%, with 11% PRs and 4% CRs, whereas that for rHuIL-2 plus rHuIFN- α was 20%, with 16% PRs and 4% CRs. The median time to disease progression was almost identical at 3.4 months in the monotherapy group and 3.5 months in the combination therapy group. Median survival

TABLE 8
 CLINICAL STUDIES OF RECOMBINANT HUMAN INTERFERON ALFA (rHuIFN- α)
 PLUS RECOMBINANT HUMAN INTERLEUKIN-2 (rHuIL-2) IN RENAL CELL CARCINOMA

Study	No. Assessable Patients	rHuIFN- α Regimen (Dose \times 10 ⁶ IU)	rHuIL-2 Regimen (Dose \times 10 ⁶ IU)	No. CR	No. PR	Percent CR + PR
Atzpodien et al ²²⁸	34	3-6/m ² SC 2-3 \times /wk \times 6wks	14.4-18.0/m ² SC d1-5, wk 1 3.6-4.8 d1-5, wk2-6	4	6	29
Lipton et al ²³³	39	3-12/m ² /d IM	3-12/m ² /d CIV	6	7	33
3 schedules of treatment						
Figlin et al ²²⁶	30	6/m ² IM, SC d1-4, \times 4wk	2/m ² IV d1-4, \times 4wk	—	9	30
Pichert et al ²³⁹	6	6/m ² SC d1,4	3/m ² CIV d1-4	—	—	0
2 cycles Tx on alternating weeks						
Bergmann et al ²⁴⁰	35	10/m ² SC	18/m ² IV \times 14d	2	7	26
Daily alternating Tx repeating q 6 wks						
Vogelzang et al ²²⁴	42	9.0 SC d1-4, \times 4wk	4.0 SC d1-4 \times 4wk	2	3	12
Atzpodien et al ²⁴⁵	152	5.0/m ² SC d1,3,5, wk2,3,5,6	20/m ² SC d1,3,5, wk1-4	9	29	25

Abbreviations: IU = International Units; CR = complete response; PR = partial response; SC = subcutaneous; IM = intramuscular; CIV = continuous intravenous infusion; IV = intravenous; Tx = treatment; q = every

was 9.1 months in the high-dose CIV rHuIL-2 group in contrast with 13 months in the low-dose SC rHuIL-2 plus rHuIFN- α group, although this difference was not statistically significant. While all toxicities reported, irrespective of the treatment regimen, were usually self-limited and rapidly reversible upon discontinuation of drug administration, Palmer and colleagues noted that there was an important shift in the toxicity profile, with the SC treatment regimen not producing a clinically detectable capillary leak syndrome and with a reduction in the severity of most other reported toxicities. The difference in severity of toxic reactions was significant for anemia, thrombocytopenia, tachycardia, diarrhea, skin and mucous membrane toxicity, hepatotoxicity, and other toxicities. The investigators concluded that SC combined rHuIL-2 plus rHuIFN- α administration makes outpatient (home) treatment possible with no evidence of a reduction in efficacy.

Several other studies also support the use of combination rHuIL-2 and rHuIFN- α as outpatient therapy in metastatic RCC. In the study of Lipton et al,²³³ the combination of these agents provided a combined response rate of 33%, with six CRs and seven PRs among 39 patients. In their study, 31 of the total 39 patients were assessable for clinical response; therefore, when the analysis was restricted to the 31 assessable patients, the response rate was 42%. In this study, most of the patients had only minimal prior treatment and most also exhibited good performance status.

The prospective multicenter phase II trial reported by Vogelzang et al²²⁴ was an outpatient study involving 42 metastatic RCC patients who had received no prior immunotherapy. Patients received rHuIL-2 at 4 MIU on days 1 through 4 and rHuIFN- α at 9 MIU on days 1 and 4 each week of a 4-week treatment course followed by a 2-week rest period. Among these patients, who were

required to have an ECOG performance status of ≤ 2 , there was a 12% combined response rate that consisted of two CRs and three PRs, with a median survival duration of 14.5 months. The toxicity reported in this study was described as modest, with a symptom complex of rash, fever, anorexia, fatigue, mild weight loss, lymphocytosis, and eosinophilia reported in 85% to 90% of patients. The investigators concluded that additional phase II studies of the combination of rHuIL-2 and rHuIFN are not necessary except perhaps to explore the mechanisms of apparent synergy between these two biologic agents. They did underscore the need to conduct phase III trials to define the role of rHuIFN in combination with rHuIL-2 in the treatment of patients with metastatic RCC or to better define the dose response curve for such combinations.

In their published report,²²⁴ Vogelzang and colleagues reviewed 23 phase I or II clinical trials published between 1989 and 1993, including their own study. The total number of patients reported in this group of studies was 607, and 116 of these were classified as responders accounting for an overall response rate of 19%.²²⁴ The response rates in these studies ranged from zero to 40%. The clinical trials described included a variety of different routes of administration, doses, and treatment schedules. Vogelzang and colleagues indicated that most of the trials reviewed by them employed high-dose IV bolus rHuIL-2 or mandated inpatient or cumbersome outpatient continuous IV infusion of the cytokine. They cited that despite variations in dose schedule and patient selection criteria, no clearly optimal dose and schedule of rHuIL-2 and rHuIFN combination therapy had been defined in the treatment of metastatic RCC patients.

The combination of SC rHuIL-2 and rHuIFN- α has also been investigated in a series of trials performed in Europe. Two studies by Atzpodien et al^{228,245} used outpatient schedules of the two cytokines (Table 8) that varied slightly in their dose level and schedules. One hundred eighty-six patients were entered, with 48 responding (13 CRs, 35 PRs) for a 26% overall response rate. In the more recent report,²⁴⁵ the duration of CRs and PRs was more than 16 months and 9 months, respectively. Toxicity in both reports was moderate, but with grade I or II fever, chills, and malaise very common.

Finally, a phase II study conducted in Germany by Bergmann et al²⁴⁰ in metastatic RCC patients uti-

lized a novel alternating schedule of rHuIL-2 and rHuIFN- α (Table 8). Over a period of 4 days, patients were administered daily alternating treatment with 10 MIU/m² rHuIFN- α SC and 18 MIU/m² rHuIL-2 as a 1-hour IV infusion. In 35 patients with measurable tumors, 9 (26%) achieved objective responses (2 CRs and 7 PRs). In this study, most of the responses occurred in patients with metastatic disease predominantly in lung or lymph node. Importantly, tumor responses were noticed early in the treatment program, with five of nine occurring following the first treatment cycle. In the two patients exhibiting a CR, a relapse-free survival of 12 and more than 23 months occurred, and four of the seven patients exhibiting PRs had relapse-free survival of 6 months or longer. The combination of cytokines administered in this manner was associated with only moderate toxicity. There was no grade IV and only occasional grade III toxicity in this clinical trial.

Thus, a variety of trials have used both rHuIL-2 and rHuIFN- α in metastatic RCC patients, with response rates ranging from zero to over 30%. Several randomized trials investigating the combination compared to either agent alone, or the superiority of one schedule or route, have been reported. One phase II trial using IV rHuIFN- α and/or rHuIL-2 alone²³⁴ reported a response rate of 11% for the combination and 17% for single-agent rHuIL-2. Statistically, the results were similar; however, the study design precluded direct comparison. It has also been shown, however, that a subset of metastatic RCC patients have responded to this cytokine combination at a frequency of response equivalent to or greater than that reported with rHuIL-2 alone, and that durable CRs have been seen with both regimens. Without randomized trials, the efficacy of the various approaches is difficult to compare. Such trials are underway in France. In 1996, the preliminary results of this randomized trial comparing rHuIFN- α (6×10^6 IU SC three times each week), rHuIL-2 (18×10^6 IU CIV on days 1 to 5 and 12 to 15) and the combination were reported.²⁴⁶ Four hundred twenty-five patients were entered, and response rates to the various agents were rHuIFN- α , 7.5%; rHuIL-2, 6.5%; rHuIL-2 + rHuIFN- α , 18.6%. Event-free survival was also superior at 1 year for the combination of cytokines. These results are of interest, but their preliminary nature makes conclusions tentative.

The mechanisms responsible for tumor regression

TABLE 9COMBINATION THERAPY OF RENAL CELL CARCINOMA WITH RECOMBINANT HUMAN INTERLEUKIN-2 (rHuIL-2), RECOMBINANT HUMAN INTERFERON ALFA (rHuIFN- α) AND 5-FLUOROURACIL (5-FU)

Study	No. Assessable Patients	PR (%)	CR (%)	Combined (95% CI) Response Rate	Dosage & Schedule		
					rHuIFN- α (MU)	rHuIL-2 (MIU)	5-FU (mg)
Atzpodien et al ²⁵⁹	120	34 (28.3)	13 (10.8)	39.0 (31-49)	6/m ² SC q wk, wk1,4 6/m ² SC TIW, wk2,3,5-8	20/m ² SC TIW, wk1,4 5/m ² SC TIW, wk2,3	750/m ² IV bolus q wk, wk4-8
Sella et al ²⁵⁸	19	6 (31.6)	3 (15.8)	47.4 (24-71)	4/m ² SC d1-28	2/m ² CIV d1-5	600/m ² CIV d1-5

Abbreviations: PR = partial response; CR = complete response; CI = confidence interval; MU = million units; MIU = million International Units; SC = subcutaneous; q = every; TIW = three times per week; IV = intravenous; CIV = continuous intravenous infusion

in patients receiving rHuIL-2 and rHuIFN- α are unclear. Attempts to develop clinical or biologic correlates of response have been made. Clinically, the major predictor of survival and possible response in metastatic RCC patients appears to be performance status^{246,247} and/or disease sites. Since the mechanisms involved are probably immune mediated, correlations with various immunologic parameters have also been made. Variables examined have included cytolytic activity of lymphocytes,^{239,249} levels of eosinophils and lymphocytes during therapy,^{223,250} alterations in various lymphocyte subsets,²⁵¹ or levels of cytokines and/or cytokine receptors induced.^{240,249} Most of these issues, however, have been examined in small, single-institution phase I or II trials with only small numbers of responding patients, and no consistent alterations have been associated with response.

Recombinant human IL-2 and rHuIFN- β . The rHuIL-2/rHuIFN- β combination for metastatic RCC patients has also been examined. Krigel et al²⁵² administered this combination to 24 patients three times a week by IV bolus injection. Among 22 assessable patients, six (27%) exhibited objective responses, including one CR and five PRs. Eleven patients had stable disease. This study demonstrated that moderate-dose, intermittent rHuIL-2 plus rHuIFN- β can be administered on an outpatient basis in a safe and tolerable fashion, with antitumor activity comparable to that of rHuIL-2 administered alone. Importantly, the investigators noted that these responses appear to be confined to patients with favorable prognostic features.

Recombinant human IL-2 and rHuIFN- γ . In a recently published study involving the combination of rHuIL-2 and rHuIFN- γ in metastatic RCC patients,²⁵³ seven (21%) patients among the 33 enrolled achieved a PR, which approximates the results of other studies of similar patients treated with rHuIL-2 monotherapy. The investigators noted that the most interesting aspect of the rHuIL-2 plus rHuIFN- γ treatment combination was the good drug tolerance, which resulted in administration of 92.5% of planned doses to participating patients. However, these overall results were not substantially better than those reported in a variety of other regimens discussed earlier, and no clear benefit of adding rHuIFN- γ to rHuIL-2 treatment was apparent.

Combination Immunobiologic and Chemotherapy

The possible therapeutic synergism of cytokines and chemotherapeutic agents has also been investigated, with 5-fluorouracil (5-FU) being the most extensively studied cytotoxic agent. The combination of a cytokine and 5-FU would be expected, on a biochemical basis, to provide synergistic effects.²⁵⁴ Moreover, phase I studies have demonstrated a decrease in 5-FU clearance when it is concurrently administered with rHuIFN- α .²⁵⁴ Further, the augmentation of 5-FU interferon cytotoxicity had been demonstrated in earlier in vitro studies of human cancer cell lines. Based on these and other factors, the Hoosier Oncology Group²⁵⁴ conducted a phase II clinical trial of the combination of 5-FU and rHuIFN- α in metastatic RCC patients. Fourteen

patients were administered 750 mg/m²/d 5-FU by CIV on days 1 through 5 followed by weekly IV infusions of 750 mg/m² beginning on day 12. Patients concurrently received 9 MIU rHuIFN- α SC three times per week beginning on day 1. The principal toxicities reported included nausea, flu-like symptoms, stomatitis, and neurotoxicity. The investigators indicated that, with a minimum follow-up period of 13 months, there was no recorded objective clinical response with this treatment regimen. The median time to progression was only 2 months and the median survival was 5 months, although the range in median survival extended beyond 14 months. The investigators concluded that their regimen of rHuIFN- α plus 5-FU was ineffective.

Notwithstanding the apparently negative results of the study reported by the Hoosier Oncology Group,²⁵⁴ there has been considerable recent interest in the combination of rHuIL-2, rHuIFN- α , and 5-FU for patients with metastatic RCC²⁵⁵⁻²⁵⁸ (Table 9). The report by Atzpodien et al²⁵⁹ describes a phase II outpatient study that involved SC administration of rHuIL-2 and rHuIFN- α and IV bolus administration of 5-FU. Among 120 assessable patients in this study, 13 exhibited CRs and 34 exhibited PRs, for an overall response rate of 39.0%. Stratification of patients by risk factors disclosed a significant survival advantage for combination treatment over that obtained by single-agent rHuIL-2 for low- and intermediate-risk patients. The studies of Sella et al²⁵⁸ at The University of Texas M.D. Anderson Cancer Center also provide encouraging results on the treatment of metastatic RCC patients with CIV rHuIL-2 combined with rHuIFN- α and 5-FU. The overall response rate reported was 47%. Among the 19 patients treated, three achieved CRs and six achieved PRs. Reported grade III to IV toxicity included stomatitis in 26% of patients, neutropenia in 16%, and skin toxicity in 11%. The central nervous system toxicity comprised a 26% incidence of hallucinations and a 5% incidence of confusion. Moreover, gram-positive bacteremia occurred in more than 14% of treatment courses.

The treatment regimen employed by Sella et al²⁵⁸ differed considerably from that employed by Atzpodien et al²⁵⁹ (Table 9). For instance, rHuIL-2 was administered CIV in the former study and SC in the latter. Further, 5-FU was administered CIV in the Sella study and by IV bolus, with a different

time course of administration, in the Atzpodien study. Despite considerable differences in the study design, the study results were favorable when taken collectively, with almost 48% of patients exhibiting an objective response. More information about the toxicity encountered in these studies will be of interest and additional confirmation of efficacy data will be necessary in the form of confirmatory phase II trials, and if indicated, in randomized controlled phase III studies.

The role of vinblastine in combination with various cytokines in the treatment of metastatic RCC has also been studied.^{128,260-264} Sertoli et al²⁶⁰ treated 20 metastatic RCC patients with a combination of rHuIFN- α at a dose of 18 MIU three times each week and vinblastine at a dose of 0.1 mg/kg every 3 weeks. In this study, two patients achieved a PR. The side effects recorded in this study were principally associated with interferon administration. While 18 of 19 patients experienced flu-like symptoms on the day of interferon treatment, these symptoms usually improved during continuing treatment. The most relevant and dose-limiting side effect in this trial was fatigue, which increased during treatment. A second trial reported by Merimsky et al²⁶¹ used the combination of rHuIFN- α and vinblastine in nine metastatic RCC patients following failure or relapse on rHuIFN- α monotherapy. No responses were noted.

Several randomized trials using this combination have been conducted, with the largest reported by Fosså et al.²⁶³ A total of 178 metastatic RCC patients were randomized to receive either rHuIFN- α alone or rHuIFN- α plus vinblastine. Recombinant human IFN- α was administered IM at 18 MIU three times each week, and vinblastine was administered IV at 0.1 mg/kg one time every 3 weeks. In this study, the response rate was 11% for patients receiving rHuIFN- α monotherapy and 24% for those receiving rHuIFN- α plus vinblastine. The overall 5-year survival of eligible patients from this phase III study was 9%, which is close to that reported by others.²⁶³ Flu-like symptoms occurred in more than 95% of patients, and fatigue and gastroenterologic symptoms occurred in approximately 70% of patients independent of treatment regimen. The investigators encountered leukopenia more frequently with combination therapy (53%) than with rHuIFN- α alone (30%). They concluded that the results of administration of IFN- α in this treatment regimen were in accord with those of other studies and that,

as monotherapy, rHuIFN- α has modest antitumor activity in metastatic RCC patients. While the combination of this agent with vinblastine produced an approximate doubling of the objective response rate, this regrettably did not translate into prolonged survival for patients enrolled in this study. The toxicity, with the exception of the leukopenia mentioned above, and tolerance to both treatment regimens were essentially the same.

In contrast to these results, Pyrhönen et al²⁶⁵ recently reported in a preliminary fashion the results of a trial comparing vinblastine (0.1 mg/kg IV every 3 weeks) alone or combined with rHuIFN- α (3 MIU SC three times weekly for 1 week followed by 18 MIU SC three times weekly). One hundred eighty patients were enrolled and randomized. Response rates were 16.5% for the combination and 2.5% for vinblastine alone. Median survival was also different (15.8 versus 8.8 months) and significantly larger for the combination. This data suggests rHuIFN- α enhances the response rate and prolongs survival when administered with vinblastine. The randomized trials with these agents, therefore, provide evidence that rHuIFN- α is a useful agent in the treatment of advanced RCC.

The combination of rHuIL-2 and vinblastine has also been evaluated in RCC patients with metastatic disease. In a phase II study, 33 patients with evidence of progressive disease at the time of study entry were treated with moderate-dose rHuIL-2 (18 MIU/m²/d, days 1 to 4 and 12 to 16) and vinblastine (4 mg/m² IV, on days 24 and 26 of each 35-day cycle).²⁶⁴ There was no treatment-related death in this study, although four patients experienced grade IV toxicity consisting of pulmonary edema, gastrointestinal bleeding, infection, mental status changes, and hypotension requiring administration of vasopressors. Two patients achieved a CR and three had a PR with subsequent resection of the residual primary renal mass. In the three responding patients, the responses were ongoing at 29+, 29+, and 27+ months of therapy. In addition, three other patients exhibited minor responses. In summary, the investigator indicated that the combination of vinblastine and moderate-dose rHuIL-2 can be administered in the setting of a regular oncology ward and may be associated with efficacy equivalent to that of high-dose rHuIL-2-based treatment.²⁶⁴

Tumor Necrosis Factor- α Therapy

Tumor necrosis factor- α (TNF- α), which has

been shown to exhibit powerful antitumor activity in vitro and in certain animal models,¹⁴⁹ has been studied in the treatment of metastatic RCC, although only sparse data are available. In general, TNF- α is extremely toxic with debilitating side effects. Recently, studies have been reported in preliminary form on the combination of TNF- α and rHuIFN- α or rHuIFN- γ in metastatic RCC patients.^{266,267} The limited patient populations in these types of trials preclude any conclusions regarding their efficacy.

Lymphokine-Activated Killer Cell Therapy

Adoptive immunotherapy refers to the transfer to the tumor-bearing host of active immunologic elements with antitumor reactivity intended to either directly or indirectly modulate antitumor effects.^{139,142,149,151,268-271} The early clinical trials of adoptive immunotherapy were conducted at the National Cancer Institute and involved administration of rHuIL-2 and LAK cells. Lymphokine-activated killer cells are derived from the incubation of resting lymphocytes in IL-2 for 3 to 4 days. These cells are then capable of lysing a variety of fresh, NK-resistant tumor cells, but not normal cells.¹⁴² Rosenberg's group reports that, as of March 1991, 72 metastatic RCC patients had received a combination of LAK cells and rHuIL-2.²⁶⁸ Among these, eight patients exhibited a CR and 17 a PR, for a combined response rate of 35%. Because clinical responses had already been noticed in RCC with high-dose rHuIL-2 monotherapy, a prospective randomized clinical trial comparing high-dose rHuIL-2 alone or in combination with LAK cells was carried out.²⁷² Even though objective responses occurred in both treatment arms, the overall survival differences between the treatment groups did not reach statistical significance, thereby casting into uncertainty the potential merit of adding LAK cells. As Figlin et al¹⁴² cited, other reports indicate that the addition of LAK-cell infusions to rHuIL-2 regimens does not produce a substantial change in antitumor response rate compared with rHuIL-2 monotherapy, but may be associated with considerably greater toxicity. This was demonstrated in a randomized, multicenter phase III trial of rHuIL-2 with or without LAK cells for patients with advanced RCC.²⁷³ The addition of LAK did not improve the response rate above that obtained using rHuIL-2 alone, and a statistically significant increase in pulmonary toxicity among patients assigned to the LAK arm was seen.

Tumor-Infiltrating Lymphocytes

One of the most intriguing approaches to therapy of metastatic RCC involves the use of tumor-infiltrating lymphocytes (TILs).²⁷⁴ Lymphoid cells isolated from solid tumors, TILs are generated by incubating enzymatic digestions of fresh tumors in IL-2 *in vitro*, which results in proliferation and activation of lymphocytes infiltrating these tumors.²⁶⁸ The resultant cells develop the ability to lyse the cocultured tumor cells. Tumor-infiltrating lymphocytes may increase dramatically in number, and in animal immunotherapy models are reported to be 50 to 100 times more effective than LAK cells on a cell-to-cell basis.²⁷⁵ In contrast to LAK cells, which are activated NK cells, TILs are activated CTLs.¹⁴⁴ Phenotypic and functional analysis of *ex vivo* expanded TILs²⁷⁶ has demonstrated heterogeneity in the cell populations, with CD3⁺ and CD56⁺ lymphocytes present with nonspecific cytolytic activity against autologous and allogeneic tumor cells. Tumor-infiltrating lymphocytes can be prepared from primary or metastatic tumors. Following enzymatic digestion of the excised tumor specimen, the single-cell suspension is incubated in the presence of IL-2 and, in approximately 3 to 4 weeks, the activated T-lymphocyte population is available. Approximately 10¹¹ cells are typically reinfused into the patient along with rHuIL-2.¹³⁴ The experience to date with TIL therapy of metastatic RCC is preliminary. Whereas significant clinical responses have been achieved during TIL therapy of melanoma,²⁷⁷ those seen in metastatic RCC are less impressive. For instance, in the Cleveland Clinic studies,^{276,278} among 34 treated patients there were four objective clinical responses. The UCLA experience with TIL therapy for metastatic RCC patients has been more encouraging.^{151,271,274} The UCLA group has reported a median duration of response for complete responders of more than 18 months, with some patients exhibiting as high as 28 or more months' response duration, and a PR median duration of more than 5 months. The investigators indicated that no completely responding patient has relapsed in their study²⁷¹ and that no death or grade IV toxicity had occurred.¹⁵¹ They concluded that immunotherapy involving combined rHuIFN- α -primed TILs, low-dose CIV rHuIL-2, and rHuIFN- α can induce significant and durable antitumor responses in certain patients with metastatic RCC. Moreover, they indicated that the combination of SC or CIV rHuIL-2 and rHuIFN- α ,

administered either alone or with primed TILs, can produce significantly beneficial clinical activity in an outpatient setting. In these studies, however, it is unclear what the administration of TILs has contributed to the cytokine regimen.

Current studies with adoptive immunotherapy employing TILs are utilizing CD8⁺-selected TILs administered with rHuIL-2. This subpopulation contains the putative CTL-effector cells but, as in other TIL trials, the expanded cell population is nonselective in its lytic activity.²⁷⁹ Belldegrun et al cited that RCC presents a special problem in regard to TIL therapy because of the original cellular heterogeneity, indicating that frequently less than 30% of TILs from RCCs are CD8⁺, and that this proportion may vary widely.²⁷⁸ Moreover, they mentioned that if the CD8⁺ T cell is actually the key antitumor effector cell, then the currently employed bulk culture processes are inefficient and have too much individual variability. The investigators have developed a single-step selection process for the expanded-scale *ex vivo* production of CD8⁺ TILs. With this technique, samples of digested tumor are cultured for up to 20 days *ex vivo* using high-dose rHuIL-2. The cultures obtained were greater than 90% CD8⁺ at the time of culture termination. There was a broad range of lytic activity expressed by the propagated CD8⁺ cells against autologous RCC, but this activity was not specific. The authors' findings have provided the basis for ongoing trials using the highly purified CD8⁺ immune T cells as part of an adoptive immunotherapy protocol. A randomized trial comparing CD8⁺ TILs with rHuIL-2 to the cytokine alone is underway.

Recent work at the Cleveland Clinic²⁷⁹ has involved culturing TILs in both rHuIL-2 and rHuIL-4 in an attempt to potentiate T-cell responses to RCC. In one clinical trial,²⁷⁹ the majority of the TILs were CD3⁺, with a very small percentage of CD56⁺ cells. In an attempt to find RCC-specific T cells, TILs were separated into CD4⁺ and CD8⁺ subsets and then evaluated for autologous tumor reactivity, which resulted in identification of five RCC-specific TIL lines from the patients' cell cultures. Among five patients who achieved a response, three had a greater percentage of CD4⁺ cells, with the remaining two patients having greater numbers of CD8⁺ cells. Among the three CD8⁺ lines with cytolytic activity isolated, two exhibited specific activity for their autologous tumor, presumably recognizing the tumor through the T-cell receptor-

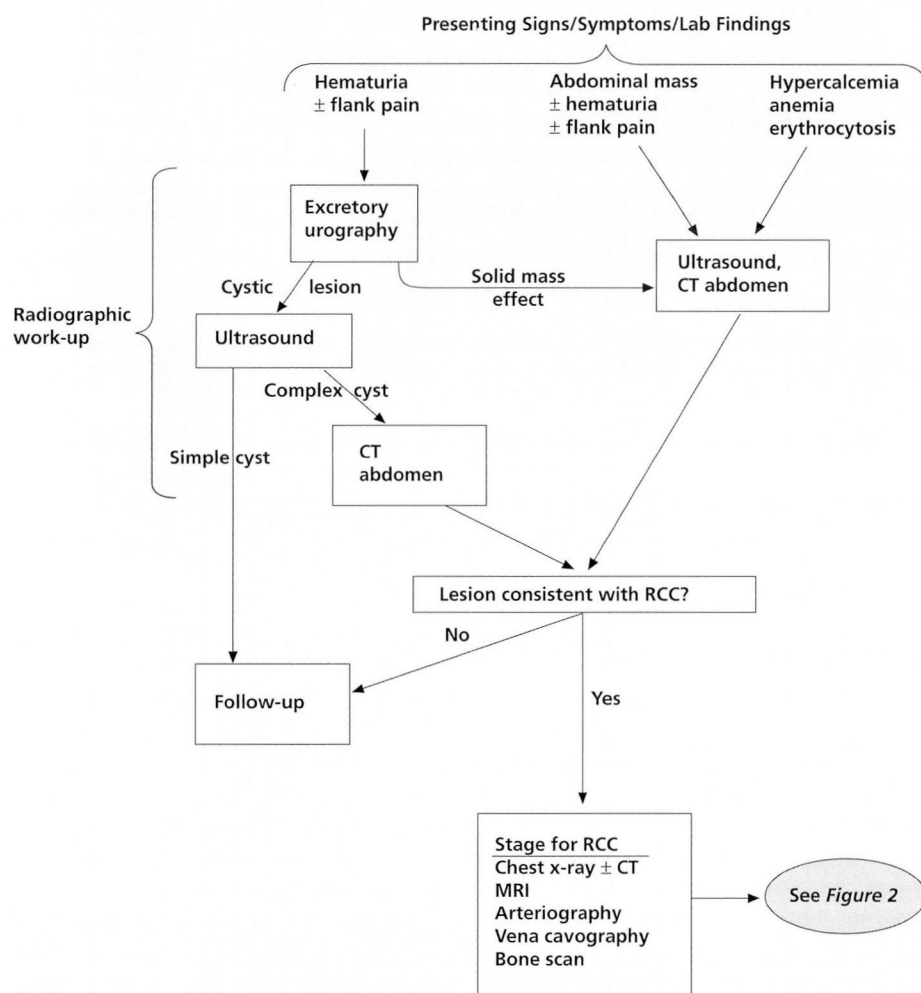


FIGURE 1. Evaluation of suspected renal cell carcinoma (RCC). CT = computed tomography; MRI = magnetic resonance imaging.

CD3 molecular complex. The investigators cited that specific and selective RCC-specific T-cell lines can be found, raising the possibility of finding antigens that serve as targets for these cells.

Adoptive immunotherapy may have a potential role in the treatment of metastatic RCC patients, but at present its role is not clear. Specific cytokine selection, dosing schedule, and selective growth of TIL subsets (eg, CD8⁺) need to be more clearly defined to optimize the use of TILs in this disease. Certainly, a wide variety of modifications may conceivably enhance the therapeutic activity of TILs. For instance, *in vivo* priming with rHuIFN- α , rHuIFN- γ , rHuIL-2, TNF, and other agents may

have considerable therapeutic merit. Among the more innovative approaches to the use of TILs in metastatic RCC is the notion of inserting specific genes that code for selected BRMs to amplify the efficacy of activated immune cells. Therapeutic clinical trials are also underway to determine the possible effectiveness of immunizing cancer patients by using autologous and/or allogeneic cancer cells modified by insertion of various genes, such as TNF²⁶⁸ and granulocyte-macrophage colony-stimulating factor (GM-CSF).²⁸⁰ Such novel approaches are of interest and may provide new methods of enhancing the immune responses in metastatic RCC patients. Results, however, remain preliminary.

Autolymphocyte Therapy

Another approach to the treatment of metastatic RCC patients involves autolymphocyte therapy (ALT).²⁸¹ This is a method of outpatient adoptive immunotherapy using T cells activated *ex vivo* by the combination of anti-CD3 monoclonal antibody along with a cocktail of autologous cytokines.²⁶⁹ Lymphocytes from the patient are harvested by lymphapheresis and are cultured in medium that may also contain cimetidine to block so-called "suppressor T cells." The autologous cytokine cocktail consists of the supernatant obtained from a culture of autologous lymphocytes activated for 3 days with anti-CD3 antibody.

In the study reported by Osband et al,²⁸¹ 90 patients were prospectively randomized to receive either oral cimetidine or cimetidine plus ALT.

Among the 39 assessable patients in the ALT group, eight (21%) exhibited a PR; in the cimetidine group, two among the 41 assessable patients (5%) achieved a PR. The difference between treatment groups was statistically significant. Interestingly, males who received ALT achieved a fourfold survival advantage over those receiving cimetidine only—a difference that was also statistically significant. By contrast, no survival difference was noted among women between the two treatment arms. Treatment was well tolerated, and the principal toxicity was of low grade and readily reversed.

The lack of toxicity of ALT is interesting, with only 8.9% of pheresis/infusion procedures being accompanied by grade I or II toxicities and with no grade III or IV toxicity reported. Additional research into this approach to therapy is now underway, and a phase III clinical trial comparing ALT to monotherapy with rHuIFN- α is in progress. The role of ALT in this patient population awaits the results of this study.

T-lymphocyte dysfunction. Finally, the causes and effects of T-lymphocyte dysfunction present in RCC patients are being actively investigated. It has long been recognized that T cells from animals or cancer patients respond less well than do healthy controls to in vitro immune stimuli.^{282,283} Recently, alterations in the T-cell antigen receptor and pathways of signal transduction in these cells have been described.^{284,285} The abnormalities include decreases in T-cell receptors, p56^{lck}, and alterations of the NF κ B complex. The functional consequences of these abnormalities may be related to the low response rates produced by cytokine therapy and/or adaptive immunotherapy. The underlying causes of these immune abnormalities may be related to the secretion of soluble inhibitory factors, such as transforming growth factor β ²⁸⁶ or interleukin-10²⁸⁷ by tumor cells. As our understanding of the signaling pathways in T lymphocytes evolves, and as the causes of tumor-associated immunosuppression are evaluated, pharmacologic and/or biologic approaches for reversal of these abnormalities may be developed.

PATHWAYS FOR MANAGING RENAL CELL CARCINOMA

During the past decade, there have been considerable advances in our understanding of the biology of RCC.²⁸⁸ Studies of the cellular and molecular biology and immunology of this disease have generated worldwide interest and continue to support the

perspective that RCC is an excellent model for the adaptation of basic scientific research to the clinic. Progress in radiographic imaging, increased attention to the use of nephron-sparing surgery, and the development of promising BRMs underscore the importance of an integrated approach to patient management involving the medical oncologist, urologist, radiologist, and other members of the healthcare team. It is of paramount importance that the patient with laboratory abnormalities, signs, or symptoms suggesting RCC be promptly evaluated for the possible presence of this disease. Also, diligence and prompt attention must be paid to the clinical management of individuals who present with the incidental finding of a solid renal mass without accompanying clinical signs or symptoms. *Figures 1 through 3* provide a schematic overview of a generalized decision pathway for disease management. It is important to appreciate that universal acceptance of any proposed clinical decision pathway is seldom achieved. Indeed, approaches to the management of RCC patients that differ from those outlined may result in satisfactory diagnosis and patient care. We believe, however, that the decision pathway outlined here provides a structured and reasonable general approach to the patient presenting with a solid mass lesion suggesting the possibility of RCC.

Figure 1 illustrates the evaluation of a patient with suspected RCC. Following demonstration of a solid renal mass lesion, surgical removal or biopsy confirmation of malignancy is required. In patients with local disease, observation and surveillance following nephrectomy are required. The optimal schedule of follow-up studies may vary with stage (eg, stage I and II versus III) and has not yet been clearly defined.²⁸⁹

Figures 2 and 3 illustrate a decision pathway for patients presenting with confirmed and metastatic disease. The differentiation of patients with solitary or multiple metastatic sites is important because, in the latter groups, the best therapeutic options may be surgical. Postoperative adjuvant therapy does not have an established role in this setting, but it is under investigation. In patients with unresectable and/or multiple metastatic sites, clinical factors will guide therapy. Performance status is the most important and major predictor of outcome and can therefore be used for decision making. In patients with good (ECOG 0 or 1) and borderline (ECOG 2) performance status, therapeutic approaches dependent

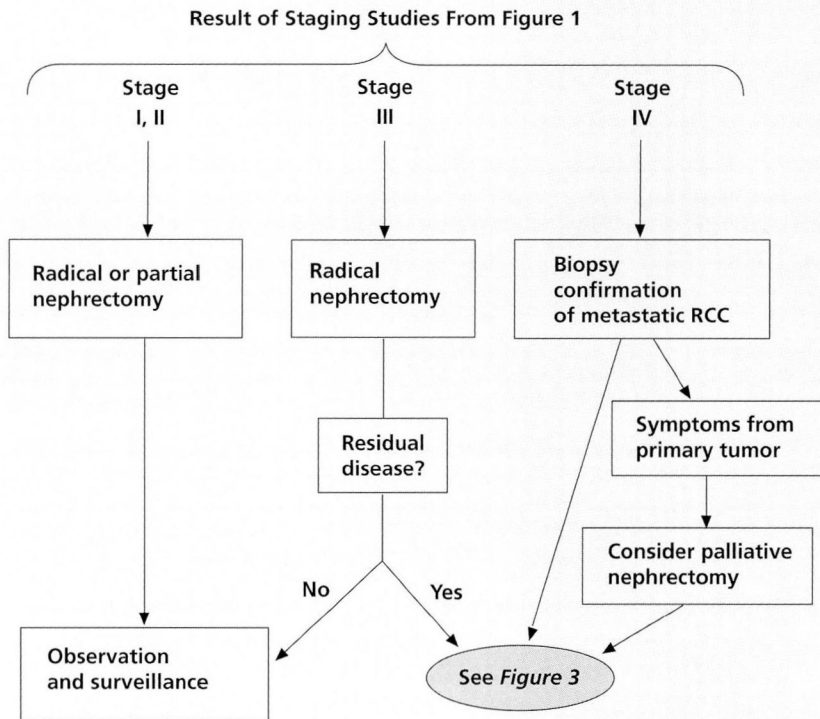


FIGURE 2. Therapy for renal cell carcinoma (RCC).

upon patient factors and outcome expectations may involve cytokine therapy. The best therapy is not yet defined, and the choice will reflect comorbid disease, patient age, and patient acceptance. The use of less toxic and outpatient regimens is clearly of interest, and these are reasonable alternatives. The majority of patients with metastatic RCC are incurable; therefore, palliative measures and/or observation are also important considerations. In patients with poor performance status or severe comorbid disease, this approach may represent the best alternative. Clearly, the best therapeutic option is not yet defined, but it appears that the use of cytokines such as rHuIFN- α , rHuIL-2, or a combination of these cytokines represents the optimal approach available.²⁹⁰ As treatment outcome is very limited, the use of investigational approaches should also be a strong consideration.

As is always the case in the practice of medicine, the optimal care of a given patient requires consideration of a variety of individual patient factors that cannot easily be represented on a clinical decision flow chart. The physician must be knowledgeable about the natural course of the disease, prognostic

factors, potential complications of surgical resection, predictable adverse experiences associated with administration of drugs and biologics, and the nature of patient rehabilitation following surgery and/or medical treatment.

CONCLUSION

In conclusion, metastatic RCC remains an incurable disease and a major therapeutic challenge despite the large number of laboratory and clinical studies conducted during the past several decades by researchers in many different countries. A wide variety of approaches has yielded disappointing results and has provided

experimental support for the contention that metastatic RCC is a disease resistant to both chemotherapy and hormonal therapy. By contrast, immunotherapy with BRMs such as rHuIFN- α and rHuIL-2 has been associated with meaningful anti-tumor responses in selected patients. Combination therapy with rHuIFN- α , rHuIL-2, and 5-FU appears to offer considerable promise, and the SC administration of rHuIFN- α and rHuIL-2 may improve the tolerability and convenience of these cancer treatments by reducing side effects and permitting outpatient administration. In general, PR rates of less than 20% and CR rates of less than 10% are unsatisfactory, yet the results in an individual patient may be excellent.

Unfortunately, a universally accepted treatment regimen for cytokine therapy has not yet been established and, as such, a thorough evaluation of each patient is required when considering the use of cytokines. Clinical responses appear to correlate with good performance status, a long disease-free interval, previous nephrectomy, and the presence of lung-predominant disease.^{4,57,142,148,165,199} The role of tumor-associated immune suppression in the abro-

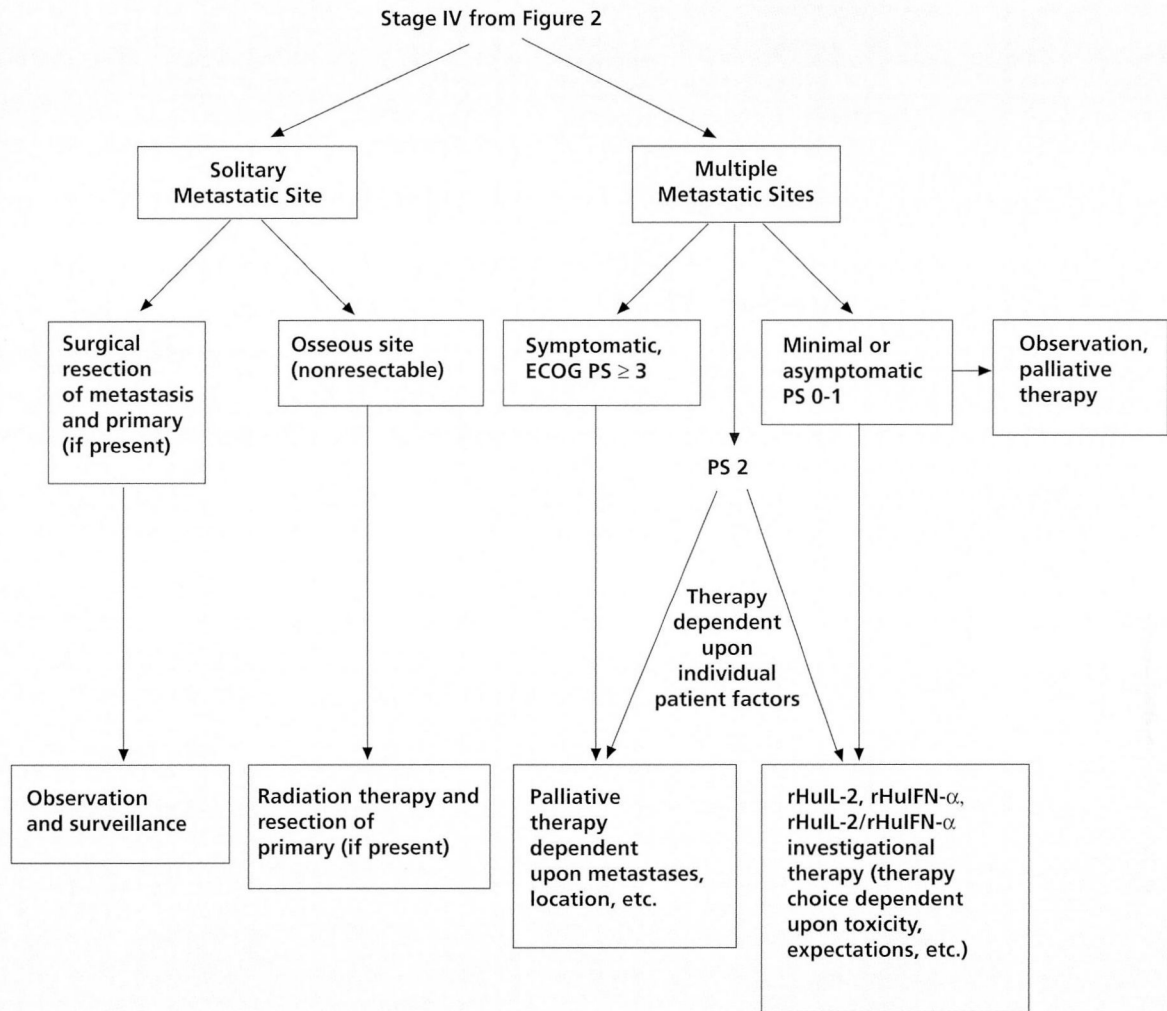


FIGURE 3. Therapy for metastatic renal cell carcinoma (RCC).

ECOG = Eastern Cooperative Oncology Group; PS = performance status; rHuIL-2 = recombinant human interleukin-2; rHuIFN- α = recombinant human interferon alfa.

gation of response is also under investigation. Cytokine administration must always be accompanied by particular diligence on behalf of the healthcare team, whether these agents are administered in the hospital or in an outpatient setting. In the outpatient setting, it is particularly important to provide the necessary patient education that will permit prompt identification of emerging problems of clinical significance. Pretreatment screening to confirm adequate renal, hepatic, cardiovascular, and pulmonary function is essential. The physician must have a comprehensive knowledge of the pharmacology and toxicology of cytokines. Even though many

of the adverse reactions to cytokine administration are self-limiting and may often be reversible within 2 or 3 days following cessation of therapy, patients should be advised of the importance of maintaining good communication with the physician and the remainder of the healthcare team. Effective communication in both directions helps to diminish patient concerns about the emergence of predictable side effects. Finally, the need for consistent and frequent patient follow-up cannot be overemphasized. Patient visits should include a careful physical examination as well as routine laboratory evaluation and special tests where indicated.

Modern molecular genetics represents a powerful tool that may have enormous value in elucidating the pathogenetic basis of RCC, thereby opening the doorway for a potential cure for this devastating illness. A compelling use of molecular genetics in the treatment of RCC may involve the insertion of specific cytokine genes into neoplastic cells in an effort to activate the immune system against the cancer.²⁹¹ Notwithstanding the sophistication and promise of gene therapy, it may be possible to exploit the potential of specific monoclonal antibodies and the combination of immunotherapy with novel chemotherapeutic agents or radiation therapy in approaching this disease. Finally, evaluation of the mechanisms and causes of tumor-associated immunosuppression may lead to strategies enhancing the effectiveness of various immunotherapeutic approaches. Regardless of the relative emphasis on any given therapeutic agent, however, it will be crucial to gain an enhanced understanding of the biochemistry and molecular biology of RCC.

REFERENCES

1. Cancer facts & figures—1996. Atlanta, GA: American Cancer Society, Inc.; 1996.
2. Boring CC, Squires TS, Tong T. Cancer statistics: 1993. *CA Cancer J Clin* 1993; **43**:7–26.
3. Stenzl A, DeKernion JB. Pathology, biology, and clinical staging of renal cell carcinoma. *Semin Oncol* 1989; **16**(Suppl 1):3–11.
4. Linehan WM, Shipley W, Parkinson D. Cancer of the kidney and ureter. In: DeVita VT Jr, Hellman S, Rosenberg SA, editors. *Cancer: principles and practice of oncology*. Philadelphia: JB Lippincott, 1993:1023–1051.
5. Linehan WM, Lerman MI, Zbar B. Identification of the von Hippel-Lindau (VHL) gene: its role in renal cancer. *JAMA* 1995; **273**:564–570.
6. Reiter R, Zbar B, Linehan WM. Molecular genetic studies of renal cell carcinoma: potential biologic and clinical significance for genitourinary malignancy. In: Walsh PC, Retik AB, Vaughan ED, Stamey TA, editors. *Campbell's urology: Update 7*. Philadelphia: WB Saunders, 1993:1–15.
7. Yu MC, Mack TM, Hanisch R, Cicioni C, Henderson BE. Cigarette smoking, obesity, diuretic use, and coffee consumption as risk factors for renal cell carcinoma. *J Natl Cancer Inst* 1986; **77**:351–356.
8. La Vecchia C, Negri E, D'Avanzo B, Franceschi S. Smoking and renal cell carcinoma. *Cancer Res* 1990; **50**:5231–5233.
9. McLaughlin JK, Lindblad P, Møller A, et al. International renal-cell cancer study. I. Tobacco use. *Int J Cancer* 1995; **60**:194–198.
10. Benhamou S, Lenfant MH, Ory-Paoletti C, Flamant R. Risk factors for renal-cell carcinoma in a French case-control study. *Int J Cancer* 1993; **55**:32–36.
11. Lew EA, Garfinkel L. Variations in mortality by weight among 750,000 men and women. *J Chronic Dis* 1979; **32**:563–576.
12. Maclure M, Willett W. A case-control study of diet and risk of renal adenocarcinoma. *Epidemiology* 1990; **1**:430–440.
13. Wynder EL, Mabuchi K, Whitmore WF. Epidemiology of adenocarcinoma of the kidney. *J Natl Cancer Inst* 1974; **53**:1619–1634.
14. Lornoy W, Becaus I, De Vleeschouwer M. Renal cell carcinoma, a new complication of analgesic nephropathy. *Lancet* 1986; **1**:1271–1272.
15. Malker HR, Malker BK, McLaughlin JK, Blot WJ. Kidney cancer among leather workers [letter]. *Lancet* 1984; **1**:56–57.
16. Maclure M. Asbestos and renal adenocarcinoma. A case-control study. *Environ Res* 1987; **42**:353–361.
17. Enterline PE, Viren J. Epidemiologic evidence for an association between gasoline and kidney cancer. *Environ Health Perspect* 1985; **62**:303–312.
18. Bretan PN, Busch MP, Hricak H. Development of acquired renal cysts and renal cell carcinoma. *Cancer* 1986; **57**:1871–1879.
19. Chung-Park M, Parveen T, Lam M. Acquired cystic disease of the kidneys and renal cell carcinoma in chronic renal insufficiency without dialysis treatment. *Nephron* 1989; **53**:157–161.
20. Matson MA, Cohen EP. Acquired cystic kidney disease: occurrence, prevalence, and renal cancers. *Medicine (Baltimore)* 1990; **69**:217–226.
21. Brennan JF, Stilmant MM, Babayan RK, Siroky MB. Acquired renal cystic disease: implications for the urologist. *Br J Urol* 1991; **67**:342–348.
22. McLaughlin JK, Gao YT, Gao RN, et al. Risk factors for renal-cell cancer in Shanghai, China. *Int J Cancer* 1992; **52**:562–565.
23. Møller A, Lindblad P, Schlehofer B, et al. International renal-cell cancer study. III. Role of weight, height, physical activity, and use of amphetamines. *Int J Cancer* 1995; **60**:350–354.
24. Robbins SL, Cotran RS. *Pathologic basis of disease*, 2nd edition. Philadelphia: WB Saunders, 1979.
25. Sternberg SS, editor. *Diagnostic surgical pathology*. New York: Raven Press, 1994:1714–1717.
26. Bertoni F, Ferri C, Benati A, Bacchini P, Corrado F. Sarcomatoid carcinoma of the kidney. *J Urol* 1987; **137**:25–28.
27. Ro JY, Ayala AG, Sella A, Samuels ML, Swanson DA. Sarcomatoid renal cell carcinoma: a clinicopathologic study of 42 cases. *Cancer* 1987; **59**:516–526.
28. Sella A, Hinshaw WM, Woodard BH, Paulson DF. Stratification of risk factors in renal cell carcinoma. *Cancer* 1983; **52**:899–903.
29. Sella A, Logothetis J, Ro JY, Swanson DA, Samuels ML. Sarcomatoid renal cell carcinoma: a treatable entity. *Cancer* 1987; **60**:1313–1318.
30. Cohen AJ, Li FP, Berg S, et al. Hereditary renal-cell carcinoma associated with a chromosomal translocation. *N Engl J Med* 1979; **301**:592–595.
31. Pathak S, Strong LC, Ferrell RE, Trindade A. Familial renal cell carcinoma with a 3:11 chromosome translocation limited to tumor cells. *Science* 1982; **217**:939–941.
32. Kovacs G, Brusa P, deRiese W. Tissue-specific expression of a constitutional 3;6 translocation: development of multiple bilateral renal-cell carcinomas. *Int J Cancer* 1989; **43**:422–427.
33. DeJong B, Oosterhuis JW, Idenburg VJ, Castedo SM, Dam A, Mensink HJ. Cytogenetics of 12 cases of renal adenocarcinoma. *Cancer Genet Cytogenet* 1988; **30**:53–61.
34. Yoshida HA, Ohyashiki K, Ochi H, et al. Cytogenetic studies of tumor tissue from patients with nonfamilial renal cell carcinoma. *Cancer Res* 1986; **46**:2139–2147.
35. Kovacs G, Frisch S. Clonal chromosome abnormalities in tumor cells from patients with sporadic renal cell carcinomas. *Cancer Res* 1989; **49**:651–659.
36. Presti JC, Rao PH, Chen Q, et al. Histopathological, cytogenetic, and molecular characterization of renal cortical tumors. *Cancer Res* 1991; **51**:1544–1552.
37. Maher ER, Iselius L, Yates JR, et al. Von Hippel-Lindau disease: a genetic study. *J Med Genet* 1991; **28**:443–447.
38. Seizinger BR, Rouleau GA, Ozelius LJ, et al. Von Hippel-Lindau disease maps to the region of chromosome 3 associated with renal cell carcinoma. *Nature* 1988; **332**:268–269.
39. Chen F, Kishida T, Yao M, et al. Germline mutations in the von Hippel-Lindau disease tumor suppressor gene: correlations with phenotype. *Hum Mutat* 1995; **5**:66–75.

40. Gnarra JR, Tory K, Weng Y, et al. Mutation of the VHL tumor suppressor gene in renal carcinoma. *Nat Genet* 1994; 7:85-90.
41. Shuin T, Kondo K, Torigoe S, et al. Frequent somatic mutations and loss of heterozygosity of the von Hippel-Lindau tumor-suppressor gene in primary human renal cell carcinomas. *Cancer Res* 1994; 54:2852-2855.
42. Shimizu M, Yokota J, Mori N, et al. Introduction of normal chromosome 3p modulates the tumorigenicity of a human renal cell carcinoma cell line YCR. *Oncogene* 1990; 5:185-194.
43. Oshimura M, Kugoh H, Koi M, et al. Transfer of a normal human chromosome 11 suppresses tumorigenicity of some but not all tumor cell lines. *J Cell Biochem* 1990; 42:135-142.
44. Schmidt L, Li F, Brown RS, et al. Mechanism of tumorigenesis of renal carcinomas associated with the constitutional chromosome 3;8 translocation. *Cancer J Sci Am* 1995; 1:191-195.
45. Kovacs G, Ishikawa I. High incidence of papillary renal cell tumors in patients on chronic haemodialysis. *Histopathology* 1993; 22:135-139.
46. Bard RH, Lord B, Fromowitz F. Papillary adenocarcinoma of kidney. *Urology* 1982; 19:16-20.
47. Duan DR, Pause A, Burgess WH, et al. Inhibition of transcription elongation by the VHL tumor suppressor protein. *Science* 1995; 269:1402-1406.
48. Kibel A, Iliopoulos O, DeCaprio JA, Kaelin WG. Binding of the von Hippel-Lindau tumor suppressor protein to Elongin B and C. *Science* 1995; 269:1444-1446.
49. Oka H, Chatani Y, Hoshino R, et al. Constitutive activation of mitogen-activated protein (MAP) kinases in human renal cell carcinoma. *Cancer Research* 1995; 55:4182-4187.
50. DeKernion JB. Renal tumors. In: Walsh PC, Gittes RF, Perlmutter AD, editors. *Campbell's urology*. Philadelphia: WB Saunders, 1986:1294-1342.
51. Cherukuri SV, Johanning PW, Ram MD. Systemic effects of hypernephroma. *Urology* 1977; X:93-97.
52. Utz DW, Warren MM, Gregg JA. Reversible hepatic dysfunction associated with hypernephroma. *Mayo Clin Proc* 1970; 45:161.
53. Pinals RS, Krane SM. Medical aspects of renal carcinoma. *Postgrad Med J* 1962; 38:507-529.
54. Samaan NA. Paraneoplastic syndromes associated with renal carcinoma: a pilot study. *J Clin Oncol* 1987; 6:862.
55. Hanash KA, Utz DC, Ludwig J, Wakim KG, Ellefson RD, Kelalis PP. Syndrome of reversible hepatic dysfunction associated with hypernephroma: an experimental study. *Invest Urol* 1971; 8:399-404.
56. Skinner DG, Calvin RB, Vermillion CD, Pfister RC, Leadbetter WE. Diagnosis and management of renal cell carcinoma. *Cancer* 1971; 28:1165-1177.
57. Maldazys JD, DeKernion JB. Prognostic factors in metastatic renal carcinoma. *J Urol* 1986; 136:376-379.
58. Suftrin G, Mink I, Moore FR. Coagulation factors in renal adenocarcinoma. *J Urol* 1978; 119:727-730.
59. Dawson NA, Barr CE, Alving BM. Acquired dysfibrinogenemia. *Am J Med* 1985; 78:682-686.
60. DaSilva JL, Lacombe C, Bruneval P, et al. Tumor cells are the site of erythropoietin synthesis in human renal cancers associated with polycythemia. *Blood* 1990; 75:577-582.
61. Thiede MA, Strewler GJ, Nissenson RA, Rosenblatt M, Rodan GA. Human renal carcinoma expresses two messages encoding a parathyroid hormone-like peptide: evidence for the alternative splicing of a single-copy gene. *Proc Natl Acad Sci USA* 1988; 85:4605-4609.
62. Nissenson RA, Strewler GJ, Williams RD, Leung SC. Activation of the parathyroid hormone receptor-adenylate cyclase system in osteosarcoma cells by a human renal carcinoma factor. *Cancer Res* 1985; 45:5358-5363.
63. Strewler GJ, Williams RD, Nissenson RA. Human renal carcinoma cells produce hypercalcemia in the nude mouse and a novel protein recognized by parathyroid hormone receptors. *J Clin Invest* 1983; 71:769-773.
64. Robson CJ, Churchill BM, Anderson W. The results of radical nephrectomy for renal cell carcinoma. *J Urol* 1969; 101:297-301.
65. American Joint Committee on Cancer. Staging and end reporting. Manual for staging of cancer, 3rd edition. Philadelphia: JB Lippincott; 1988.
66. International Union Against Cancer (UICC). TNM classification of malignant tumors, 4th edition. New York: Springer-Verlag; 1987:83-88.
67. Keller JW, McCune CS, Sahasrabudhe DM. Urologic and male genital cancers. In: Rubin P, editor. *Clinical oncology*, 7th edition. Philadelphia: WB Saunders, 1993: chap 23.
68. American Joint Committee on Cancer. Manual for staging of cancer, 4th edition. Philadelphia: JB Lippincott, 1992: 201-202.
69. Boxer RJ, Waisman J, Leiber MM et al. Renal carcinoma: computer analysis of 96 patients treated by nephrectomy. *J Urol* 1979; 122:598-601.
70. McNichols DW, Segrura JW, DeWeerd JH. Renal cell carcinoma: long-term survival and late recurrence. *J Urol* 1981; 126:17-23.
71. Cheri RJ, Goldman GG, Lindner A, et al. Prognostic implications of vena caval extension of renal cell carcinoma. *J Urol* 1982; 128:910-912.
72. Seli C, Hinshaw WM, Woodward BH, et al. Stratification of risk factors in renal cell carcinoma. *Cancer* 1983; 52:899-903.
73. Bassil B, Dosoretz DE, Prout GR Jr. Validation of the tumor, nodes and metastasis classification of renal cell carcinoma. *J Urol* 1985; 134:450-454.
74. Golimbu M, Joshi P, Sperber A, Tessler A, Al-Askari S, Morles P. Renal cell carcinoma: survival and prognostic factors. *Urology* 1986; 27:291-301.
75. Tsukamoto T, Kumamoto Y, Yamazaki K, et al. Clinical analysis of incidentally found renal cell carcinomas. *Eur Urol* 1991; 19:109-113.
76. Patel, NP, Lavengood RW. Renal cell cancer: natural history and results of treatment. *J Urol* 1977; 119:722-726.
77. Ljungberg B, Grankvist K, Rasmuson T. Serum acute phase reactants and prognosis in renal cell carcinoma. *Cancer* 1995; 76:1435-1439.
78. Ljungberg B, Larsson P, Stenling R, Roos G. Flow cytometric deoxyribonucleic acid analysis in stage I renal cell carcinoma. *J Urol* 1991; 146:697-699.
79. Currin SM, Lee SE, Walther PJ. Flow cytometric assessment of deoxyribonucleic acid content in renal adenocarcinoma: does ploidy status enhance prognostic stratification over stage alone? *J Urol* 1990; 143:458-463.
80. Nativ O, Sabo E, Raviv G, Medalia O, Moskovitz B, Goldwasser B. The role of nuclear morphometry for predicting disease outcome in patients with localized renal cell carcinoma. *Cancer* 1995; 76:1440-1444.
81. Lang EK. Asymptomatic space-occupying lesions of the kidney: a programmed sequential approach and its impact on quality and cost of health care. *South Med J* 1977; 70:277-285.
82. Campbell SC, Novick AC. Screening for renal cell carcinoma. In: Ernstoff MC, Heaney JA, Peschel RE, editors. *Urologic cancer*. New York: WW Norton and Co., 1996.
83. Montie JE, Pontes JE, Bukowski RM, editors. *Clinical management of renal cell cancer*. Chicago: Year Book Medical Publishers, 1990.
84. Frohmuller HGW, Grups JW, Heller V. Comparative value of ultrasonography, computerized tomography, angiography and excretory urography in the staging of renal cell carcinoma. *J Urol* 1987; 138:482-484.
85. Lang EK. Comparison of dynamic and conventional computed tomography, angiography, and ultrasonography in the staging of renal cell carcinoma. *Cancer* 1984; 54:2205-2214.
86. Karp W, Ekelung L, Olafsson G, Olsson A. Computed tomography, angiography and ultrasound in staging of renal carcinoma. *Acta Radiol* 1981; 22:625-633.
87. Richie JP, Garnick MB, Seltzer S, Bettman, MA. Computerized

- tomography scan for diagnosis and staging of renal cell carcinoma. *J Urol* 1983; **129**:1114-1116.
88. **Medenica R, Slack N.** Clinical results of leukocyte interferon-induced tumor regression in resistant human metastatic cancer resistant to chemotherapy and/or radiotherapy-pulse therapy schedule. *Cancer Drug Deliv* 1985; **2**:53-76.
 89. **Yokoyama M, Watanabe K, Inatsuki S.** Computerized tomography of the kidney: tissue-plasma ratio of contrast enhancement with bolus injection and renal function. *J Urol* 1982; **127**:721-723.
 90. **Karstaedt N, McCullough DL, Wolfman NT, Dyer RB.** Magnetic resonance imaging of the renal mass. *J Urol* 1986; **136**:566-570.
 91. **Goldfarb DA, Novick AC, Lorig R, et al.** Magnetic resonance imaging for assessment of vena caval tumor thrombi: a comparative study with venacavography and computerized tomography scanning. *J Urol* 1990; **144**:1100-1103.
 92. **Mauro MA, Wadsworth DE, Stanley RJ, McClenna BL.** Renal cell carcinoma: angiography in the CT era. *Amer J Radiol* 1982; **139**:1135-1138.
 93. **Horan JJ, Robertson CN, Choyke PL, et al.** The detection of renal carcinoma extension into the renal vein and inferior vena cava: a prospective comparison of venacavography and magnetic resonance imaging. *J Urol* 1989; **142**:943-948.
 94. **Herts BR, Baker ME.** The current role of percutaneous biopsy in the evaluation of renal masses. *Semin Urol Oncol* 1995; **13**:254-261.
 95. **McDonald MW.** Current therapy for renal cell carcinoma. *J Urol* 1982; **127**:211-217.
 96. **Novick AC.** Radical nephrectomy: anterior approach. In: Marshall FF, editor. *Textbook of operative urology*. Philadelphia: WB Saunders, 1996:1-15.
 97. **Novick AC.** Current surgical approaches, nephron-sparing surgery, and the role of surgery in the integrated immunologic approach to renal-cell carcinoma. *Semin Oncol*, 1995; **22**:29-33.
 98. **Butler BP, Novick AC, Miller DP, Campbell SA, Licht MR.** Management of small unilateral renal cell carcinomas: radical versus nephron-sparing surgery. *Urology* 1995; **45**:34-40.
 99. **Novick AC.** Management of the incidentally detected solid renal mass. *Semin Nephrol* 1994; **14**:519-522.
 100. **Licht MR, Novick AC, Goormastic M.** Nephron sparing surgery in incidental versus suspected renal cell carcinoma. *J Urol* 1994; **152**:39-42.
 101. **Licht MR, Novick AC.** Nephron sparing surgery for renal cell carcinoma. *J Urol* 1993; **149**:1-7.
 102. **Novick AC.** Partial nephrectomy. In: Montie JE, Pontes JE, Bukowski RM, editors. *Clinical management of renal cell cancer*. Chicago: Year Book Medical Publishing, 1990: chap 4.
 103. **Gonick P.** Surgical therapy of renal adenocarcinoma. *Semin Oncol* 1983; **10**:413-416.
 104. **Buzaid AC, Todd MB.** Therapeutic options in renal cell carcinoma. *Semin Oncol* 1989; **16**(Suppl 1):12-19.
 105. **Novick AC, Kaye MC, Cosgrove DM, et al.** Experience with cardiopulmonary bypass and deep hypothermic circulatory arrest in the management of retroperitoneal tumors with large vena caval thrombi. *Ann Surg* 1990; **212**:472-476.
 106. **Glazer AA, Novick AC.** Long-term follow-up after surgical treatment for renal cell carcinoma extending into the right atrium. *J Urol* 1996; **155**:448-450.
 107. **Tolia BM, Whitmore WE.** Solitary metastasis from renal cell carcinoma. *J Urol* 1975; **114**:836-838.
 108. **Rafila S.** Renal cell carcinoma: natural history and results of treatment. *Cancer* 1970; **25**:26-40.
 109. **O'Dea MJ, Zincke H, Utz DC.** The treatment of renal cell carcinoma with solitary metastasis. *J Urol* 1978; **120**:540-542.
 110. **Walther MM, Alexander RB, Weiss GH, et al.** Cytoreductive surgery prior to interleukin-2-based therapy in patients with metastatic renal cell carcinoma. *Urol* 1993; **42**:250-258.
 111. **Sella A, Swanson DA, Ro JY, et al.** Surgery following response to interferon-alpha-based therapy for residual renal cell carcinoma. *J Urol* 1993; **149**:19-22.
 112. **Sella A, Swanson D, Amato R, et al.** Evidence for a favorable effect of surgical resection of residual metastatic renal cell carcinoma (RCC) following biological therapy (BT) [abstract]. *Proc Am Soc Clin Oncol* 1993; **12**:246.
 113. **Rackley R, Novick A, Klein E, Bukowski R, McLain D, Goldfarb D.** The impact of adjuvant nephrectomy on multimodality treatment of metastatic renal cell carcinoma. *J Urol* 1994; **152**:1399-1403.
 114. **Finney R.** Radiotherapy in the treatment of hypernephroma: a clinical trial. *Br J Urol* 1973; **45**:26-40.
 115. **van der Werf-Messing B.** Carcinoma of the kidney. *Cancer* 1973; **32**:1056-1062.
 116. **Kjaer M, Frederiksen PL, Engelholm SA.** Postoperative radiotherapy in stage II and III renal adenocarcinoma: a randomized trial by the Copenhagen renal cancer study group. *Int J Radiat Oncol Biol Phys* 1987; **13**:665-672.
 117. **Juusela H, Malmio K, Alfthan D.** Preoperative irradiation in the treatment of renal adenocarcinoma. *Scand J Urol Nephrol* 1977; **11**:277-281.
 118. **Peeling WB, Mantell BS, Shephard BCE.** Postoperative irradiation in the treatment of renal cell carcinoma. *Br J Urol* 1969; **41**:23-31.
 119. **Halperin EC, Harisiadis L.** The role of radiation therapy in the management of metastatic renal cell carcinoma. *Cancer* 1983; **51**:614-617.
 120. **Onufrey V, Mohiuddin M.** Radiation therapy in the treatment of metastatic renal cell carcinoma. *Int J Radiat Oncol Biol Phys* 1985; **11**:2007-2009.
 121. **Harris DT.** Hormonal therapy and chemotherapy of renal cell carcinoma. *Semin Oncol* 1983; **10**:422-430.
 122. **Yagoda A, Bander NH.** Failure of cytotoxic chemotherapy, 1983-1988, and the emerging role of monoclonal antibodies for renal cancer. *Urol Int* 1989; **44**:338-345.
 123. **Yagoda A, Abi-Rached B, Petrylak D.** Chemotherapy for advanced renal-cell carcinoma: 1983-1993. *Semin Oncol* 1995; **22**:42-60.
 124. **Denis L, Van Oosterom A.** Chemotherapy of metastatic renal cancer. *Semin Surg Oncol* 1988; **4**:91-94.
 125. **Fojo AT, Shen DW, Mickley LA, Pastan I, Gottesman MM.** Intrinsic drug resistance in kidney cancers is associated with expression of a human multidrug resistance gene. *J Clin Oncol* 1987; **5**:1922-1927.
 126. **Goldstein L, Galski H, Fojo A, et al.** Expression of a multi-drug resistance gene in human tumors [abstract]. *Proc Am Assoc Cancer Res* 1988; **29**:298.
 127. **Krown SE.** Therapeutic options in renal cell carcinoma. *Semin Oncol* 1985; **12**:13-17.
 128. **Warner E, Tobe S, Pei Y, Trachtenberg J, Skorecki K.** Phase I trial of vinblastine (VBL) with oral cyclosporine-A (CSA) as a multidrug resistance modifier in renal cell carcinoma (RCC) [abstract]. *Proc Am Soc Clin Oncol* 1992; **11**:204.
 129. **Lemon S, Meadows B, Fojo A, et al.** A phase I study of infusional vinblastine with the P-glycoprotein antagonist PSC 833 in patients with metastatic cancer [abstract]. *Proc Am Soc Clin Oncol* 1995; **14**:479.
 130. **La Rocca RV, Stein CA, Danesi R, Cooper MR, Uhrich M.** A pilot study of suramin in the treatment of metastatic renal cell carcinoma. *Cancer* 1991; **67**:1509-1513.
 131. **Guimaraes JL, Ghosn M, Ostronoff M, Azab M, Theodore C, Droz JP.** Phase II trial of methyl-gag and melphalan in metastatic adult renal cell carcinoma. *Cancer Invest* 1990; **8**:623-624.
 132. **Wilding G, Kirkwood J, Clamon G, et al.** Phase II trial of navelbine in metastatic renal cancer [abstract]. *Proc Am Soc Clin Oncol* 1993; **12**:253.
 133. **Canobbio L, Boccardo F, Guarnieri D, et al.** Phase II study of navelbine in advanced renal cell carcinoma. *Eur J Cancer* 1991; **27**:804-805.

134. Von Roemeling R, Hrushesky WJM. Circadian patterning of continuous floxuridine infusion reduces toxicity and allows higher dose intensity in patients with widespread cancer. *J Clin Oncol* 1989; 7:1710-1719.
135. Dexeus FH, Logothetis CJ, Sella A, et al. Circadian infusion of floxuridine in patients with metastatic renal cell carcinoma. *J Urol* 1991; 146:709-713.
136. Damascelli B, Pizzacaro G, Spreadico C, et al. Improved survival in patients with continuous systemic infusion of FUdR [abstract]. *Proc AACR* 1989; 30:259.
137. Kjaer M. The role of medroxyprogesterone acetate (MPA) in the treatment of renal adenocarcinoma. *Cancer Treat Rev* 1988; 15:195-209.
138. Muss HB. The use of interferon in renal cell carcinoma. *Eur J Cancer* 1991; 27(Suppl 4):S84-S87.
139. Haas GP, Hillman GG, Redman BG, Pontes JE. Immunotherapy of renal cell carcinoma. *CA Cancer J Clin* 1993; 43:177-187.
140. Reese JH. Renal cell carcinoma. *Curr Opin Oncol* 1992; 4:427-434.
141. Swanson DA. Is cytotoxic chemotherapy effective in the treatment of advanced renal cell carcinoma? *Semin Urol* 1993; 11:1:35-40.
142. Figlin RA, Abi-Aad AS, Belldegrun A, DeKernion JB. The role of interferon and interleukin-2 in the immunotherapeutic approach to renal cell carcinoma. *Semin Oncol* 1991; 18(Suppl 7):102-107.
143. DeMulder PHM, DeBruyne FMJ, Beniers AJMC. Interferons in renal cell carcinoma: status and prospects. EORTC Genitourinary Group Monograph 9: Basic research and treatment of renal cell carcinoma metastasis. Wiley-Liss, Inc., 1990:49-59.
144. Gilewski T, Vogelzang NJ. Cost effectiveness and reimbursement issues in renal cell carcinoma. *Semin Oncol* 1989; 16(Suppl 1):20-26.
145. Merinsky O, Chaitchik S. Our experience with interferon alpha: renal cell carcinoma. *Mol Biother* 1992; 4:130-134.
146. Ebert T, Schmitz-Dräger BJ, Ackermann R. The role of cytokines in the therapy of renal cell carcinoma. *Recent Results Cancer Res* 1993; 126:113-118.
147. Stahl M, Wilke HJ, Seeber S, Schmoll HJ. Cytokines and cytotoxic agents in renal cell carcinoma: a review. *Semin Oncol* 1992; 19(Suppl 4):70-79.
148. Choudhury M, Efron M, Mittelman A. Interferons and interleukins in metastatic renal cell carcinoma. *Urology* 1993; 41:67-72.
149. Wirth MP. Immunotherapy for metastatic renal cell carcinoma. *Urol Clin N Am* 1993; 20:283-295.
150. Finke JH, Tubbs R, Conelly B, Pontes E, Montie J. Tumor-infiltrating lymphocytes in patients with renal cell carcinoma. *Ann NY Acad Sci* 1987; 532:387-394.
151. Belldegrun A, Pierce W, Kaboo R, et al. Interferon-alpha primed tumor-infiltrating lymphocytes combined with interleukin-2 and interferon-alpha as therapy for metastatic renal cell carcinoma. *J Urol* 1993; 150:1384-1390.
152. Bernhard H, Karbach J, Wölfel T, et al. Cellular immune response to human renal-cell carcinoma: definition of a common antigen recognized by HLA-A2-restricted cytotoxic T-lymphocyte (CTL) clones. *Int J Cancer* 1994; 59:837-842.
153. Dorr RT. Interferon-alpha in malignant and viral diseases: a review. *Drugs* 1993; 45:177-211.
154. Czarniecki CW, Fennie CW, Powers DB, et al. Synergistic antiviral and antiproliferative activities of *E coli* derived human alpha, beta, and gamma interferons. *J Virol* 1984; 49:490-496.
155. Nanus DM, Pfeffer LM, Bander NH, et al. Antiproliferative and antitumor effect of alpha-interferon in renal cell carcinoma: correlation to the expression of a kidney-associated differentiation glycoprotein. *Cancer Res* 1990; 50:4190-4194.
156. Quesada JR, Swanson DA, Trindale A, et al. Renal cell carcinoma: antitumor effects of leukocyte interferon. *Cancer Res* 1983; 43:940-947.
157. DeKernion JB, Sarna JB, Figlin R, et al. The treatment of renal cell carcinoma with human leukocyte alpha-interferon. *J Urol* 1983; 130:1063-1066.
158. Horoszewicz JS, Murphy GP. An assessment of the current use of human interferons in therapy of urological cancers. *J Urol* 1989; 142:1173-1180.
159. Quesada JR, Rios A, Swanson D, et al. Antitumor activity of recombinant-derived interferon alpha in metastatic renal cell carcinoma. *J Clin Oncol* 1985; 3:1522-1528.
160. Tsavaris N, Mylonakis N, Bacoyiannis Ch, Tsoutsos H, Karabelis A, Kosmidis P. Treatment of renal cell carcinoma with escalating doses of alpha-interferon. *Chemotherapy* 1993; 39:361-366.
161. Kosmidis PA, Baxevanis CN, Tsavaris N, et al. The prognostic significance of immune changes in patients with renal cell carcinoma treated with interferon-alfa-2b. *J Clin Oncol* 1992; 10:1153-1157.
162. Marshall ME, Simpson W, Butler K, Fried A, Fer M. Treatment of renal cell carcinoma with daily low-dose alpha-interferon. *J Biol Resp Modif* 1989; 8:453-461.
163. Bono AV, Reali L, Benvenuti C, et al. Recombinant alpha interferon in metastatic renal cell carcinoma. *Urology* 1991; 38:60-63.
164. Muss HB, Costanzi JJ, Leavitt R, et al. Recombinant alfa interferon in renal cell carcinoma: a randomized trial of two routes of administration. *J Clin Oncol* 1987; 5:286-291.
165. Minasian LM, Motzer RJ, Gluck L, Mazumdar M, Vlamis V, Krown SE. Interferon alfa-2a in advanced renal cell carcinoma: treatment results and survival in 159 patients with long-term follow-up. *J Clin Oncol* 1993; 11:1368-1375.
166. Umeda T, Niijima T. Phase II study of alpha-interferon in renal cell carcinoma: summary of three collaborative trials. *Cancer* 1986; 58:1231-1235.
167. Schnall SF, Davis C, Ziyadeh T, et al. Treatment of metastatic renal cell carcinoma (RCC) with intramuscular (IM) recombinant interferon alpha A (IFN, Hoffman-LaRoche) [abstract]. *Proc Am Soc Clin Oncol* 1986; 5:227.
168. Sarna G, Figlin R, DeKernion J. Interferon in renal cell carcinoma: the UCLA experience. *Cancer* 1987; 59:610-612.
169. Kempf RA, Grunberg SM, Daniels JR, et al. Recombinant interferon alpha-2 (Intron A) in a phase II study of renal cell carcinoma. *J Biol Resp Modif* 1986; 5:27-35.
170. Einzig AI, Krown SE, Oettgen HF. Recombinant leukocyte A interferon (rIFN-alpha) in renal cell cancer (RCC) [abstract]. *Proc Am Soc Clin Oncol* 1984; 3:54.
171. Steineck G, Strander H, Carbin B-E, et al. Recombinant leukocyte interferon alpha-2a and medroxyprogesterone in advanced renal cell carcinoma: a randomized trial. *Acta Oncol* 1990; 29:155-162.
172. Levens W, Ruebben H, Ingenhag W. Long-term interferon treatment in metastatic renal cell carcinoma. *Eur Urol* 1989; 16:378-381.
173. Creagan ET, Twito DI, Johansson SL, et al. A randomized prospective assessment of recombinant leukocyte A human interferon with or without aspirin in advanced renal cell adenocarcinoma. *J Clin Oncol* 1991; 9:2104-2109.
174. Krown SE, Einzig AI, Abramson JD, et al. Treatment of advanced renal cell cancer (RCC) with recombinant leukocyte A interferon (rIFN-alpha A) [abstract]. *Proc Am Soc Clin Oncol* 1983; 2:58.
175. Otto U, Schneider A, Denkhau H, et al. Die behandlung des metastasierten nierenkarzinoms mit rekombinantem alpha-2 oder gamma-Interferon: ergebnisse zweier klinischer phase-II-bzw.-Studien. *Onkologie* 1988; 11:185-191.
176. Rinehart J, Malspeis L, Young D, et al. Phase I/II trial of human recombinant beta-interferon serine in patients with renal cell carcinoma. *Cancer Res* 1986; 46:5364-5367.
177. Kish J, Ensley J, Al-Sarraf M, et al. Activity of serine inhibited recombinant DNA beta interferon (IFN beta) in patients with metastatic and recurrent renal cell cancer [abstract]. *Proc Am*

- Assoc Cancer Res 1986; 27:184.
178. Kinney P, Triozzi P, Young D, et al. Phase II trial of interferon-beta-serine in metastatic renal cell carcinoma. *J Clin Oncol* 1990; 8:881-885.
 179. DeMulder PHM, DeBruyne FMJ, Franssen MPH, et al. Phase I/II study of recombinant interferon-alpha and gamma in advanced progressive renal cell carcinoma. *Cancer Immunol Immunother* 1990; 34:321-324.
 180. Barna BP, Thomassen MJ, Sergi J, Murthy S, Bukowski RM. Immunologic changes in renal cell carcinoma patients receiving gamma interferon. *Oncology* 1991; 48:464-468.
 181. Ellerhorst J, Jones E, Kilbourn R, et al. Fixed low dose gamma interferon (IFN) is active against metastatic renal cell carcinoma (RCC) [abstract]. *Proc Am Soc Clin Oncol* 1992; 11:220.
 182. Heider A, Moritz T, Elmaagli A, Kreß M, Seeber S, Niederle N. Interferon (IFN) gamma in the treatment of metastatic renal cell carcinoma [abstract]. *Proc Am Soc Clin Oncol* 1993; 12:239.
 183. Bruntsch U, DeMulder PH, ten Bokkel Huinink WW, et al. Phase II study of recombinant human interferon-gamma in metastatic renal cell carcinoma. *J Biol Resp Modif* 1990; 9:335-338.
 184. Aulitzky W, Gastl G, Aulitzky WE, et al. Successful treatment of metastatic renal cell carcinoma with a biologically active dose of recombinant interferon-gamma. *J Clin Oncol* 1989; 7:1875-1884.
 185. Grups JW, Frohmüller HG. Cyclic interferon gamma treatment of patients with metastatic renal cell carcinoma. *Br J Urol* 1989; 64:218-220.
 186. Garnick MB, Reich SD, Maxwell B, et al. Phase I/II study of recombinant interferon gamma in advanced renal cell carcinoma. *J Urol* 1988; 139:251-255.
 187. Rinehart JJ, Young D, Laforge J, et al. Phase I/II trial of recombinant gamma-interferon in patients with renal cell carcinoma: immunologic and biologic effects. *J Biol Resp Modif* 1987; 6:302-312.
 188. Koiso K. Recombinant Human Interferon Gamma (S-6810) Research Group on Renal Cell Carcinoma: Phase II study of recombinant human interferon gamma (S-6810) on renal cell carcinoma. *Cancer* 1987; 60:929-933.
 189. Kuzmits R, Kokoschka EM, Micksche M, et al. Phase II results with recombinant interferons: renal cell carcinoma and malignant melanoma. *Oncology* 1985; 42:26-32.
 190. Quesada JR, Kurzrock R, Sherwin SA, et al. Phase II studies of recombinant human interferon gamma in metastatic renal cell carcinoma. *J Biol Resp Modif* 1987; 6:20-27.
 191. Huber C, Aulitzky W, Gastl G, et al. Treatment of metastasizing renal cell carcinoma with an "optimum" biological response modifying dose of r-IFN-gamma. *J Biol Resp Modif* 1989; 8:335.
 192. Mattijssen V, Van Moorselaar J, DeMulder PH, Schalkwijk L, Ruiter DJ. Human leukocyte antigen expression in renal cell carcinoma lesions does not predict the response to interferon therapy. *J Immunother* 1992; 12:64-69.
 193. Prümmer O. Interferon-alpha antibodies in patients with renal cell carcinoma treated with recombinant interferon-alpha-2A in an adjuvant multicenter trial. *Cancer* 1993; 71:1828-1834.
 194. Morgan DA, Ruscetti FW, Gallo RC. Selective in vitro growth of T-lymphocytes from normal bone marrows. *Science* 1976; 193:1007-1008.
 195. Stadler WM, Vogelzang NJ. Low-dose interleukin-2 in the treatment of metastatic renal-cell carcinoma. *Semin Oncol* 1995; 22:67-73.
 196. Parkinson DR, Sznol M. High-dose interleukin-2 in the therapy of metastatic renal-cell carcinoma. *Semin Oncol* 1995; 22:61-66.
 197. Yang JC, Topalian SL, Parkinson D, et al. Randomized comparison of high-dose and low-dose intravenous interleukin-2 for the therapy of metastatic renal cell carcinoma: an interim report. *J Clin Oncol* 1994; 12:1572-1576.
 198. Sleijfer DTh, Janssen RAJ, Buter J, deVries EGE, Willemse PHB, Mulder NH. Phase II study of subcutaneous interleukin-2 in unselected patients with advanced renal cell cancer on an outpatient basis. *J Clin Oncol* 1992; 10:1119-1123.
 199. Lissoni P, Barni S, Ardizzoia A, et al. Prognostic factors of the clinical response to subcutaneous immunotherapy with interleukin-2 alone in patients with metastatic renal cell carcinoma. *Oncology* 1994; 51:59-62.
 200. Buter J, Sleijfer DTh, van der Graaf WTA, deVries EGE, Willemse PHB, Mulder NH. A progress report on the outpatient treatment of patients with advanced renal cell carcinoma using subcutaneous recombinant interleukin-2. *Semin Oncol* 1993; 20(Suppl 9):16-21.
 201. Caligiuri MA. Low-dose recombinant interleukin-2 therapy: rationale and potential clinical applications. *Semin Oncol* 1993; 20(Suppl 9):3-10.
 202. Atzpodiën J, Kirchner H, Hänninen EL, et al. European studies of interleukin-2 in metastatic renal cell carcinoma. *Semin Oncol* 1993; 20(Suppl 9):22-26.
 203. Rosenberg SA, Yang JC, Topalian SL, et al. Treatment of 283 consecutive patients with metastatic melanoma or renal cell cancer using high-dose bolus interleukin-2. *JAMA* 1994; 271:907-913.
 204. Rosenberg SA. The development of new immunotherapies for the treatment of cancer using interleukin-2: a review. *Ann Surg* 1988; 208:121-135.
 205. Whitehead RP, Ward DL, Hemingway LL, et al. Phase I-II trial of intravenous bolus recombinant interleukin-2 in patients with disseminated renal cell carcinoma [abstract]. *Proc Am Soc Clin Oncol* 1988; 7:128.
 206. Sosman JA, Kohler PC, Hank J, et al. Repetitive weekly cycles of recombinant human interleukin-2: responses of renal carcinoma with acceptable toxicity. *J Natl Cancer Inst* 1988; 80:60-63.
 207. Marumo K, Muraki J, Ueno M, et al. Immunologic study of human recombinant interleukin-2 (low-dose) in patients with advanced renal cell carcinoma. *Urology* 1989; 33:219-225.
 208. Negrier S, Philip T, Stoter G, et al. Interleukin-2 with or without LAK cells in metastatic renal cell carcinoma: a report of a European multi-centre study. *Eur J Cancer Clin Oncol* 1989; 25(Suppl 3):S21-S28.
 209. Bukowski RM, Goodman P, Crawford ED, et al. Phase II trial of high-dose intermittent interleukin-2 in metastatic renal cell carcinoma: a Southwest Oncology Group study. *J Natl Cancer Inst* 1990; 82:143-146.
 210. Geertsens PF, Hermann GG, Maase H, et al. Treatment of metastatic renal cell carcinoma by continuous intravenous infusion of recombinant interleukin-2: a single-center phase II study. *J Clin Oncol* 1992; 10:753-759.
 211. Lissoni P, Barni S, Ardizzoia A, et al. Second line therapy with low-dose subcutaneous interleukin-2 alone in advanced renal cancer patients resistant to interferon-alpha. *Eur J Cancer* 1992; 28:92-96.
 212. von der Maase H, Geertsens P, Thatcher N, et al. Recombinant interleukin-2 in metastatic renal cell carcinoma: a European multicentre phase II study. *Eur J Cancer* 1991; 27:1583-1589.
 213. Negrier S, Mercatello A, Bret M, et al. Intravenous interleukin-2 in patients over 65 with metastatic renal cell carcinoma. *Br J Cancer* 1992; 65:723-726.
 214. Perez EA, Scudder SA, Meyers FA, et al. Weekly 24-hour continuous infusion interleukin-2 for metastatic melanoma and renal cell carcinoma: a phase I study. *J Immunother* 1991; 10:57-62.
 215. Vlasveld LT, Rankin EM, Hekman A, et al. A phase I study of prolonged continuous infusion of low dose recombinant interleukin-2 in melanoma and renal cell cancer I: clinical aspects. *Br J Cancer* 1992; 65:744-750.
 216. Fisher RI. Interleukin-2—advances in clinical research and treatment. *Semin Oncol* 1993; 20(Suppl 9):1-2.
 217. Package Insert for PROLEUKIN® (aldesleukin for injection). CHIRON Therapeutics, Emeryville, CA. May 1994.
 218. Fyfe G, Fisher RI, Rosenberg SA, Sznol M, Parkinson DR, Louie AC. Results of treatment of 255 patients with metastatic

- renal cell carcinoma who received high-dose recombinant interleukin-2 therapy. *J Clin Oncol* 1995; 13:688-696.
219. Siegel JP, Puri RK. Interleukin-2 toxicity. *J Clin Oncol* 1991; 9:694-704.
 220. Hellman S. Immunotherapy for metastatic cancer: establishing a proof of principle [editorial]. *JAMA* 1994; 271:945.
 221. Cameron RB, McIntosh JK, Rosenberg SA. Synergistic antitumor effects of combination immunotherapy with recombinant interleukin-2 and recombinant hybrid alpha-interferon in the treatment of established murine hepatic metastases. *Cancer Res* 1988; 48:5810-5817.
 222. Feruglio C, Zambello R, Trentin L, et al. Cytotoxic in vitro function in patients with metastatic renal cell carcinoma before and after alpha-2b-interferon therapy. Effects of activation with recombinant interleukin-2. *Cancer* 1992; 69:2525-2531.
 223. Palmer PA, Atzpodien J, Philip T, et al. A comparison of 2 modes of administration of recombinant interleukin-2: continuous intravenous infusion alone versus subcutaneous administration plus interferon alpha in patients with advanced renal cell carcinoma. *Cancer Biother* 1993; 8:123-136.
 224. Vogelzang NJ, Lipton A, Figlin RA. Subcutaneous interleukin-2 plus interferon alfa-2a in metastatic renal cancer: an outpatient multicenter trial. *J Clin Oncol* 1993; 11:1809-1816.
 225. Gitlitz BJ, Pierce W, Moldawer N, DeKernion J, Belldegrun A, Figlin R. Long term follow-up and patterns of relapse in metastatic renal cell carcinoma (RCCA) using an outpatient regimen of low dose interleukin-2 (IL-2) and interferon-alpha (IFN) [abstract]. *Proc Am Soc Clin Oncol* 1994; 13:254.
 226. Figlin RA, Belldegrun A, Moldawer N, Zeffren J, DeKernion J. Concomitant administration of recombinant human interleukin-2 and recombinant interferon alfa-2A: an active outpatient regimen in metastatic renal cell carcinoma. *J Clin Oncol* 1992; 10:414-421.
 227. Figlin RA, Pierce WC, Belldegrun A. Combination biologic therapy with interleukin-2 and interferon-alfa in the outpatient treatment of metastatic renal cell carcinoma. *Semin Oncol* 1993; 20(Suppl 9):11-15.
 228. Atzpodien J, Poliwoda H, Kirchner H. Alpha-interferon and interleukin-2 in renal cell carcinoma: studies in nonhospitalized patients. *Semin Oncol* 1991; 18(Suppl 7):108-112.
 229. Atzpodien J, Kirchner H, DeMulder P, et al. Subcutaneous recombinant interleukin-2 and α -interferon in patients with advanced renal cell carcinoma: results of a multicenter phase II study. *Cancer Biother* 1993; 8:289-300.
 230. Atzpodien J, Körfer A, Franks CR, Poliwoda H, Kirchner H. Home therapy with recombinant interleukin-2 and interferon- α 2b in advanced human malignancies. *Lancet* 1990; 335:1509-1512.
 231. Atzpodien J, Kirchner H. Cancer, cytokines, and cytotoxic cells: interleukin-2 in the immunotherapy of human neoplasms. *Klin Wochenschr* 1990; 68:1-11.
 232. Atzpodien J, Kirchner H. The out-patient use of recombinant human interleukin-2 and interferon alfa-2b in advanced malignancies. *Eur J Cancer* 1991; 27(Suppl 4):S88-S92.
 233. Lipton A, Harvey H, Givatt E, et al. Interleukin-2 and interferon- α -2a outpatient therapy for metastatic renal cell carcinoma. *J Immunother* 1993; 13:122-129.
 234. Atkins MB, Sparano J, Fisher RI, et al. Randomized phase II trial of high-dose interleukin-2 either alone or in combination with interferon alfa-2b in advanced renal cell carcinoma. *J Clin Oncol* 1993; 11:661-670.
 235. Thomas H, Barton C, Saini A, Dalglish A, Waxman J. Sequential interleukin-2 and alpha interferon for renal cell carcinoma and melanoma. *Eur J Cancer*, 1992; 28A:1047-1049.
 236. Maxwell W, McDevitt J, Reid I, et al. Changes in immunological parameters during interleukin-2 and interferon 2 alpha treatment of recurrent renal cell carcinoma and malignant melanoma. *Eur J Surg Oncol* 1993; 19:265-272.
 237. Fosså SD, Aune H, Baggerud E, Granerud T, Heilo A, Theodorsen L. Continuous intravenous interleukin-2 infusion and subcutaneous interferon- α in metastatic renal cell carcinoma. *Eur J Cancer* 1993; 29A:1313-1315.
 238. Veelken H, Rosenthal FM, Schneller F, et al. Combination of interleukin-2 and interferon- α in renal cell carcinoma and malignant melanoma: a phase II clinical trial. *Biotech Therap* 1992; 3:1-14.
 239. Pichert G, Jost LM, Fierz W, Stahel RA. Clinical and immune modulatory effects of alternative weekly interleukin-2 and interferon alfa-2a in patients with advanced renal cell carcinoma and melanoma. *Br J Cancer* 1991; 63:287-292.
 240. Bergmann L, Fenchel K, Weidmann E, et al. Daily alternating administration of high-dose alpha-2b-interferon and interleukin-2 bolus infusion in metastatic renal cell cancer. A phase II study. *Cancer* 1993; 72:1733-1742.
 241. Wersäll P. Interleukin-2 and interferon in renal cell carcinoma. *Med Oncol Tumor Pharmacother* 1992; 9:71-76.
 242. Bergmann L, Weidmann E, Mitrou PS, et al. Interleukin-2 in combination with interferon-alpha in disseminated malignant melanoma and advanced renal cell carcinoma. A phase I/II study. *Oncologia* 1990; 13:137-140.
 243. Ratain MJ, Priest ER, Janisch L, Vogelzang NJ. A phase I study of subcutaneous recombinant interleukin-2 and interferon alfa-2a. *Cancer* 1993; 71:2371-2376.
 244. Rosenberg SA, Lotze MT, Yang JC, et al. Combination therapy with interleukin-2 and alpha-interferon for the treatment of patients with advanced cancer. *J Clin Oncol* 1989; 7:1863-1874.
 245. Atzpodien J, Hänninen EL, Kirchner H, et al. Multiinstitutional home-therapy trial of recombinant human interleukin-2 and interferon alfa-2 in progressive metastatic renal cell carcinoma. *J Clin Oncol* 1995; 13:497-501.
 246. Negrier S, Escudier B, Lasset C, et al. The FNCLCC Crecy trial: interleukin 2 (IL2) + interferon (IFN) is the optimal treatment to induce responses in metastatic renal cell carcinoma (MRCC) [abstract]. *Proc Am Soc Clin Oncol* 1996; 15:248.
 247. Elson PJ, Witte RS, Trump DL. Prognostic factors for survival in patients with recurrent or metastatic renal cell carcinoma. *Cancer Res* 1988; 48:7310-7313.
 248. Jones M, Philip T, Palmer P, et al. The impact of interleukin-2 on survival in renal cancer: a multivariate analysis. *Cancer Biother* 1993; 8:275-288.
 249. Favrot MC, Combaret V, Negrier S, et al. Functional and immunophenotypic modifications induced by interleukin-2 did not predict response to therapy in patients with renal cell carcinoma. *J Biol Resp Modif* 1990; 9:167-177.
 250. Bukowski RM, Murthy, Sergi JS, et al. Phase I trial of continuous infusion recombinant interleukin-2 and intermittent recombinant interferon-alpha-2a: toxicity and immunologic effects. *J Biol Resp Modif* 1990; 9:538-545.
 251. Atzpodien J, Kirchner H, Körfer A, et al. Expansion of peripheral blood natural killer cells correlates with clinical outcome in cancer patients receiving recombinant subcutaneous interleukin-2 and interferon α -2. *Tumor Biol* 1993; 14:354-359.
 252. Krigel RL, Padavic-Shaller KA, Rudolph AR, Konrad M, Bradley EC, Comis RL. Renal cell carcinoma: treatment with recombinant interleukin-2 plus beta-interferon. *J Clin Oncol* 1990; 8:460-467.
 253. Escudier B, Farace F, Angevin E, et al. Combination of interleukin-2 and gamma interferon in metastatic renal cell carcinoma. *Eur J Cancer* 1993; 29A:724-728.
 254. Murphy BR, Rynard SM, Einhorn LH, Loehrer PJ. A phase II trial of interferon alfa-2A plus fluorouracil in advanced renal cell carcinoma. A Hoosier Oncology Group study. *Invest New Drugs* 1992; 10:225-230.
 255. Atzpodien J, Kirchner H, Hänninen EL, Deckert M, Fenner M, Poliwoda H. Interleukin-2 in combination with interferon- α and 5-fluorouracil for metastatic renal cell cancer. *Eur J Cancer* 1993; 29A(Suppl 5):S6-S8.
 256. Atzpodien J, Kirchner H, Hänninen EL, Fenner M, Poliwoda

- H. Alpha-interferon, interleukin-2 and 5-fluorouracil as a promising biochemotherapy regimen for the management of advanced renal cell carcinoma [abstract]. *Proc Am Soc Clin Oncol* 1993; 12:230.
257. **Atzpodien J, Kirchner H, Hänninen EL, Deckert M, Franzke A, Poliwooda H.** European studies of interleukin-2 in metastatic renal cell cancer [abstract]. *Proc Am Soc Clin Oncol* 1994; 13:247.
 258. **Sella A, Zukiwski A, Robinson E, et al.** Interleukin-2 (IL-2) with interferon- α (IFN- α) and 5-fluorouracil (5-FU) in patients (PTS) with metastatic renal cell cancer (RCC) [abstract]. *Proc Am Soc Clin Oncol* 1994; 13:237.
 259. **Lopez HE, Kirchner H, Atzpodien J.** Interleukin-2 based home therapy of metastatic renal cell carcinoma: risks and benefits in 215 consecutive single institution patients. *J Urol* 1996; 155:19-25.
 260. **Sertoli MR, Brunetti I, Ardizzoni A, et al.** Recombinant α -2a interferon plus vinblastine in the treatment of metastatic renal cell carcinoma. *Am J Clin Oncol (CTT)* 1989; 12:43-45.
 261. **Merimsky O, Shnider BI, Chaichik S.** Does vinblastine add to the potency of alpha interferon in the treatment of renal cell carcinoma? *Mol Biother* 1991; 3:34-37.
 262. **Jekunen A, Stengård J, Hietanen P, Pyrhönen S.** Activity of vinblastine and adriamycin with/without interferon α in advanced renal cell carcinoma. [abstract]. *Proc Am Soc Clin Oncol* 1993; 12:240.
 263. **Fossá SD, Martinelli G, Otto U, et al.** Recombinant interferon alfa-2a with or without vinblastine in metastatic renal cell carcinoma: results of a European multi-center phase III study. *Ann Oncol* 1992; 3:301-305.
 264. **Fink KI, Valone FH, Myers FJ, et al.** Interleukin-2 and vinblastine for advanced renal cell carcinoma: a phase I-II study [abstract]. *Proc Am Soc Clin Oncol* 1992; 11:A664.
 265. **Pyrhönen S, Salminen E, Lehtonen, et al.** Recombinant interferon alpha-2a with vinblastine vs. vinblastine alone in advanced renal cell carcinoma. A phase III study [abstract]. *Proc Am Soc Clin Oncol* 1996; 15:244.
 266. **Waxman J, Flanders J, Hyatt D, Sikora K.** The synergy of recombinant tumour necrosis factor (r -TNF) and alpha interferon (α IFN) in renal cell carcinoma [abstract]. *Proc Am Soc Clin Oncol* 1992; 11:208.
 267. **Sohn M, Markos-Pusztai S, Kempeni J, Jakse G, van Broen G.** Tumor necrosis factor alpha and interferon gamma or alpha multicenter trials in metastatic renal cell carcinoma [abstract]. *Proc Am Soc Clin Oncol* 1992; 11:206.
 268. **Linehan WM, Walther MM, Alexander RB, Rosenberg SA.** Adoptive immunotherapy of renal cell carcinoma: studies from the surgery branch, National Cancer Institute. *Semin Urol* 1993; 11:41-43.
 269. **Ross SD, Lavin PT, Martin J, Miesowicz F, Osband ME.** Extended survival of clinically favorable patients with metastatic renal cell carcinoma (RCC) treated with ex vivo activated memory T-cells (autolymphocyte therapy, ALT) [abstract]. *Proc Am Soc Clin Oncol* 1993; 12:242.
 270. **Sznol M, Clark JW, Smith JW II, et al.** Pilot studies of interleukin-2 and lymphokine-activated killer cells combined with immunomodulatory doses of chemotherapy and sequenced with interferon alfa-2a in patients with metastatic melanoma and renal cell carcinoma. *J Natl Cancer Inst* 1992; 84:929-937.
 271. **Figlin R, Belldgrun A, DeKernion J.** Immunotherapy of patients with metastatic renal cell carcinoma (RCCa) using an outpatient regimen of interleukin-2 (IL-2) and interferon-alpha (IFN) administered either alone or with in vivo primed tumor infiltrating lymphocytes (pTIL): the UCLA experience [abstract]. *Proc Am Soc Clin Oncol* 1992; 11:197.
 272. **Rosenberg SA.** The immunotherapy and gene therapy of cancer. *J Clin Oncol* 1992; 10:180-199.
 273. **Law TM, Motzer RJ, Mazumdar M, et al.** Phase III randomized trial of interleukin-2 with or without lymphokine-activated killer cells in the treatment of patients with advanced renal cell carcinoma. *Cancer* 1995; 76:824-832.
 274. **Pierce WC, Belldgrun A, Figlin RA.** Cellular therapy: scientific rationale and clinical results in the treatment of metastatic renal-cell carcinoma. *Semin Oncol* 1995; 22:74-80.
 275. **Rosenberg SA, Speiss P, Lafreniere R.** A new approach to the adoptive immunotherapy of cancer with tumor-infiltrating lymphocytes. *Science* 1986; 233:1318-1321.
 276. **Bukowski RM, Sharfman W, Murthy S, et al.** Clinical results and characterization of tumor-infiltrating lymphocytes with or without recombinant interleukin-2 in human metastatic renal cell carcinoma. *Cancer Res* 1991; 51:4199-4205.
 277. **Rosenberg SA, Packard BS, Aebersold PM, et al.** Use of tumor-infiltrating lymphocytes and interleukin-2 in the immunotherapy of patients with metastatic melanoma. *N Engl J Med* 1988; 319:1676-1680.
 278. **Rayman P, Finke JH, et al.** Adoptive immunotherapy utilizing IL-2 and IL-4 for expansion of tumor-infiltrating lymphocytes in renal cell carcinoma. In: AE Chang and S Shu, editors. *Immunotherapy of cancer with sensitized T lymphocytes*. Boca Raton: RG Landes Co, 1994:123-129.
 279. **Belldgrun A, Steger G, Tso CL, et al.** Adoptive immunotherapy for renal cell carcinoma using cytokine-modulated tumor-infiltrating lymphocytes: The UCLA experience. UCLA School of Medicine. In: Klein EA, Bukowski RM, Finke JH, editors. *Renal cell carcinoma*. New York: Marcel Dekker, Inc., 1993: chap 15.
 280. **Jaffee EM, Marshall F, Weber C, et al.** Bioactivity of a human GM-CSF tumor vaccine for the treatment of metastatic renal cell carcinoma [abstract]. *Proc Am Soc Clin Oncol* 1996; 15:237.
 281. **Osband ME, Lavin PT, Babayan RK, et al.** Effect of autolymphocyte therapy on survival and quality of life in patients with metastatic renal-cell carcinoma. *Lancet* 1990; 335:994-998.
 282. **Miescher S, Stoeck M, Qiao L, Barras C, Barrelet L, von Flidner V.** Proliferative and cytolytic potentials of purified human tumor-infiltrating lymphocytes. Impaired response to mitogen-driven stimulation despite T-cell receptor expression. *Int J Cancer* 1988; 42:659-666.
 283. **Miescher S, Stoeck M, Qiao L, Barras C, Barrelet L, von Flidner V.** Preferential clonogenic deficit of CD8-positive T-lymphocytes infiltrating human solid tumors. *Cancer Res* 1988; 48:6992-6998.
 284. **Finke JH, Zea AH, Stanley J, et al.** Loss of T-cell receptor ζ chain and p56^{lck} in T-cell infiltrating human renal cell carcinoma. *Cancer Res* 1993; 53:5613-5616.
 285. **Li X, Liu J, Park J-K, et al.** T cells from renal cell carcinoma patients exhibit an abnormal pattern of specific DNA-binding activity: a preliminary report. *Cancer Res* 1994; 54:5424-5429.
 286. **Miescher S, Whiteside TL, Carrel S, von Flidner V.** Functional properties of tumor-infiltrating and blood lymphocytes in patients with solid tumors: effects of tumor cells and their supernatants on proliferative responses of lymphocytes. *J Immunol* 1986; 136:1899.
 287. **Wang Q, Redovan C, Tubbs R, et al.** Selective cytokine gene expression in renal cell carcinoma tumor cells and tumor infiltrating lymphocytes. *Int J Cancer* 1995; 61:780-785.
 288. **Motzer RJ, Bander NH, Nanus DM.** Renal-cell carcinoma. *N Engl J Med* 1996; 335:865-875.
 289. **Sandock DS, Seftel AD, Resnick MI.** A new protocol for the follow-up of renal cell carcinoma based on pathological stage. *J Urol* 1995; 154:28.
 290. **Sokoloff MH, deKernion JB, Figlin RA, Belldgrun A.** Current management of renal cell carcinoma. *CA Cancer J Clin* 1996; 46:284-302.
 291. **Jaffee EM, Pardoll DM.** Gene therapy: its potential applications in the treatment of renal-cell carcinoma. *Semin Oncol* 1995; 22:81-91.