



# Laser Treatment of Acne, Psoriasis, Leukoderma, and Scars

Divya Railan, MD, and Tina S. Alster, MD

**Lasers frequently are used by dermatologists for their multiple aesthetic applications, but they also can be used to treat a variety of medical dermatology conditions. Conditions such as acne vulgaris, psoriasis, and vitiligo can all be successfully treated with laser, thereby providing the patient with additional therapeutic options. Lasers have also been used for years to improve the appearance of scars. The newer fractionated lasers have been especially effective in enhancing the clinical outcomes of scar revision.**

**Semin Cutan Med Surg 27:285-291 © 2008 Elsevier Inc. All rights reserved.**

Lasers are widely known for their multiple aesthetic applications, but they also can be used to treat a variety of medical dermatology conditions. For example, recent advances in laser technology have expanded viable treatment options for acne vulgaris, psoriasis, and vitiligo. Although laser scar revision has been advocated for years, the newest fractionated lasers have further enhanced clinical outcomes.

## Acne

Acne is a common pilosebaceous disease characterized by comedones, inflammatory papules, pustules, nodules, and cysts. Lesions most commonly occur on the face, but the neck, shoulders, chest, and back also can be affected. It is estimated that at least 80% of teenagers experience acne at some point. Although acne predominantly affects adolescents, it can often continue into adulthood. Poorly controlled acne can cause permanent scarring and psychological distress for the patient, highlighting the importance of initiating effective acne treatment in a timely manner.

The factors that contribute to acne pathogenesis include (1) *Propionibacterium acnes* activity, (2) excess sebum production, (3) inflammatory tissue response, and (4) hyperproliferation of the sebaceous follicle. Acne can be classified into the following categories: (1) comedonal acne (comedones only; no inflammatory lesions or cysts), (2) mild inflammatory acne (inflammatory papules and comedones), (3) moderate inflammatory acne (inflammatory papules, pustules, comedones in overall greater number than mild disease), and

(4) severe nodulocystic acne (inflammatory papules, comedones and cysts with residual scarring).

The aim of acne treatment is to reduce the number of inflammatory and noninflammatory lesions and to halt the scarring process. Traditional acne therapies include topical medications such as benzoyl peroxide, retinoids, and antibiotics, as well as oral medications such as tetracycline-class antibiotics and isotretinoin (Table 1). Although traditional therapies remain the first line of treatment, there are several laser and light-based therapies that have become available. Blue light targets *Propionibacterium acnes*, whereas infrared lasers and radiofrequency devices target the sebaceous gland. Many laser and light-based therapies have been investigated (Table 2),<sup>1-16</sup> but here we will review only those that are currently in use for acne treatment or those with the greatest potential for future application.

Although Table 2 classifies the lasers and light devices according to their primary mechanism of action, the clinical improvement observed can generally be attributed to more than a single mechanism. For example, the 1450-nm diode targets the pilosebaceous gland in the treatment of acne, but because of the effect of bulk tissue heating, neocollagenesis is also initiated, which may be beneficial in minimizing the future risk of scarring secondary to acne.<sup>2</sup> Thus, laser and light-based therapies may be beneficial to acne treatment in 2 ways: (1) the immediate treatment of acne, either alone or in combination with a topical or systemic acne regimen, and (2) the potential to minimize scarring due to the ability to regulate neocollagenesis.

Examples of patients who can benefit from acne laser treatment include those who prefer treatment with topicals alone or those in whom isotretinoin is contraindicated (Table 3). In either scenario, laser and light-based therapies become valuable tools in maximizing acne control.

Washington Institute of Dermatologic Laser Surgery, Washington, DC.  
Address correspondence to Divya Railan, Washington Institute of Dermatologic Laser Surgery, 1430 K Street, Suite 200, Washington, DC, 20005.  
E-mail: [drailan@yahoo.com](mailto:drailan@yahoo.com)

**Table 1** Traditional Acne Therapies

Oral medications
Tetracycline class antibiotics
Isotretinoin
Topical medications
Benzoyl peroxide
Retinoids
Antibiotics (Clindamycin, Erythromycin)
Salicylic acid
Glycolic acid
Intralesional steroid injections

## Recent Developments

One of the limiting factors of acne or acne scar treatment using a 1450-nm diode laser has been the discomfort associated with the procedure. A low-energy, double-pass treatment protocol has shown pain reduction without compromising treatment benefits.<sup>7</sup>

Similarly, although a variety of lasers and intense pulsed light systems have been used to reduce the redness associated with acne outbreaks, the recent introduction of a specialized device that combines negative pressure (or suction) with the concomitant delivery of broadband pulsed light has been shown to enhance the effective delivery of the light (by elevation of the sebaceous target closer to the skin's surface).<sup>9-12</sup> In addition the pneumatic portion of the device causes the sebaceous target's contents to be mechanically removed which also contributes to its treatment efficacy. (Fig. 1a and b).

The use of aminolevulinic acid (ALA) has long been advocated for photodynamic therapy, but application of other topical agents (eg, indocyanine green or ICG) has recently been described. The topical application of ICG is followed by its uptake by the sebaceous glands, which when exposed to

**Table 2** Summary of Laser and Light Based Acne Therapies

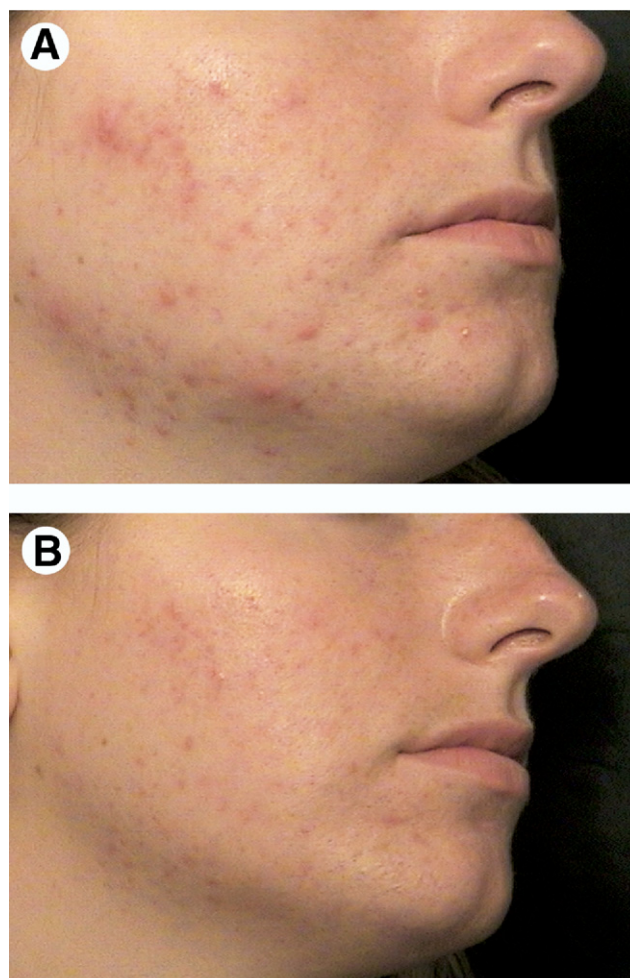
Device/Primary Mechanism	Sampling of Associated Literature
Targeting the sebaceous gland	
1450-nm diode laser	Perez-Maldonado et al <sup>3</sup> Paithankar et al <sup>4</sup> Friedman et al <sup>5</sup> Glaich et al <sup>6</sup> Bernstein <sup>7</sup>
1540-nm erbium glass Photopneumatic therapy	Lloyd and Mirkov <sup>8</sup> Omi et al <sup>9</sup> Shamban et al <sup>10</sup> Wanithphakdeedecha et al <sup>11</sup> Ortiz et al <sup>12</sup>
Selective destruction of <i>Propionibacterium acnes</i>	
Photodynamic therapy (PDT) with ALA (aminolevulinic acid)	Hongcharu et al <sup>13</sup> Alexiades-Armenakas <sup>14</sup>
With ICG (indocyanine green)	Rho et al <sup>15</sup> Tuchin et al <sup>16</sup>

**Table 3** Situations in Which to Consider Laser or Light-Based Therapy for Acne

In concert with topical therapies when a patient is adverse to ingestion of systemic medications
Contraindications to use of isotretinoin or oral antibiotics in a patient with moderate to severe acne vulgaris

near-infrared light, has demonstrated a 76% reduction in acne lesion count after 3 monthly treatments.<sup>15</sup> To enhance the effect of photodynamic therapy in the treatment of acne, both microdermabrasion and light-emitting diode therapy have been applied with positive results.<sup>16</sup>

Radiofrequency application is another promising treatment for acne and acne scars. Unlike a laser, which uses light energy to generate heat in a target chromophore, radiofrequency produces an electric current that generates heat through resistance in the dermis and subcutaneous tissue, thereby stimulating neocollagenesis and collagen remodeling.<sup>17,18</sup>

**Figure 1** Pre- (a) and post- (b) Aesthera® photopneumatic treatment for acne vulgaris.

## Psoriasis

Psoriasis is a chronic inflammatory skin disorder that affects approximately 2% of the U.S. population. There are several manifestations of the disease, but plaque psoriasis is the most common. Traditional therapies for psoriasis include topical corticosteroids and vitamin D3 analogues, systemic medications, biologic agents, and phototherapy such as PUVA or narrowband UVB. Despite the vast array of therapeutic options, some psoriatic plaques remain resistant to treatment. This latter situation is the correct setting in which to incorporate laser therapy in the treatment plan (Table 4).

Given the ability of lasers to provide more precise treatment of lesional skin while sparing surrounding nonaffected skin, laser treatment is a superb therapeutic option for localized psoriatic disease in areas such as the scalp, gluteal crease, or the palms and soles. Psoriatic plaques in the gluteal crease, in particular, can be problematic with possible development of intergluteal fissures, infection and discomfort. Laser therapy can be applied in combination with other treatment modalities to facilitate clearance of difficult to treat areas or resistant lesions.

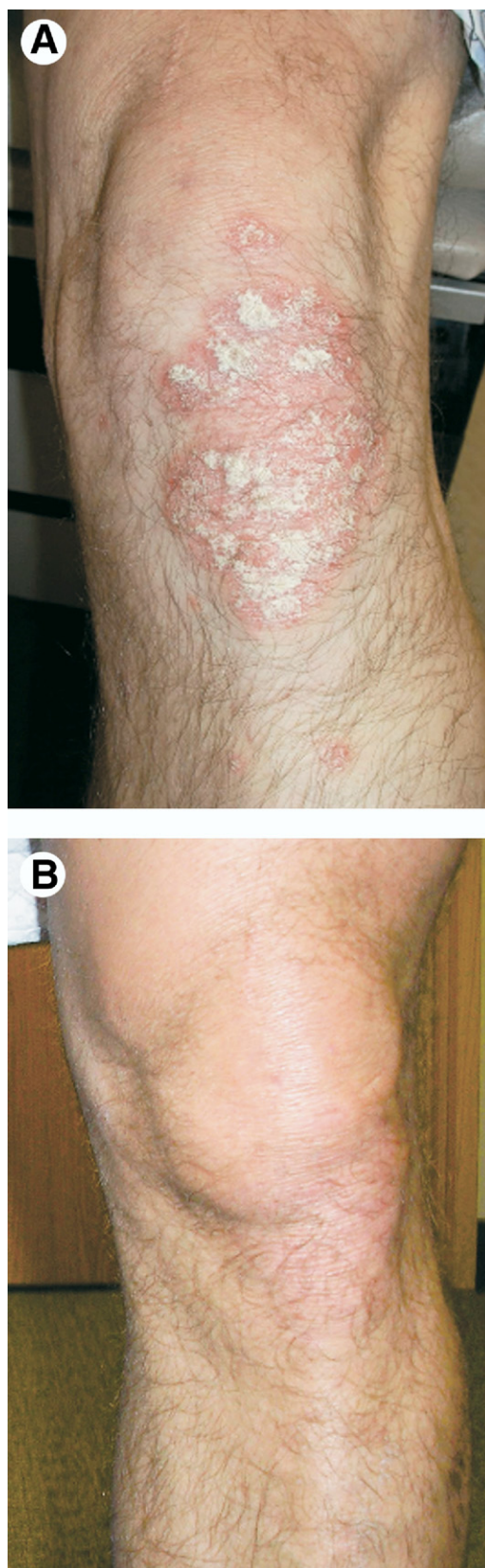
The most commonly used laser in the treatment of psoriasis is the excimer laser which selectively emits light at a 308-nm wavelength.<sup>19-24</sup> Excimer laser treatment, not surprisingly, yields clinical results similar to those obtained after NB-UVB treatment (both emitting UVB wavelengths). The laser prevents replication of epidermal cells and induces localized suppression of immune function to facilitate clearance of the inflammation associated with psoriasis (Fig. 2a and b).

A 585-nm pulsed dye laser (PDL) that targets the underlying vasculature in psoriatic plaques has also resulted in their clinical clearance.<sup>25,26</sup> In some cases, remission has lasted as long as 2 years. Slightly greater response has been noted in truncal plaques compared with those on the extremities.<sup>27</sup>

In a study that compared the excimer and pulsed dye lasers in the treatment of psoriasis in 22 patients, 13 patients responded best to the excimer system, two patients had better responses to PDL irradiation, and no notable difference between the two systems was observed in 7 patients.<sup>28</sup> The excimer laser, therefore, appears to be superior to PDL in many patients with psoriasis. Combining PDL treatment with topical calcipotriol, salicylic acid, or both has also been found to enhance the therapeutic benefit.<sup>29</sup>

**Table 4** Situations in Which to Consider Laser or Light-Based Therapy for Psoriasis

Disease resistant to conventional therapies
Localized disease only
Adjunctive therapy in problematic areas prone to skin breakdown (eg, gluteal crease)
Adjunctive therapy in cosmetically-sensitive areas (eg, scalp lesions extending onto facial skin)



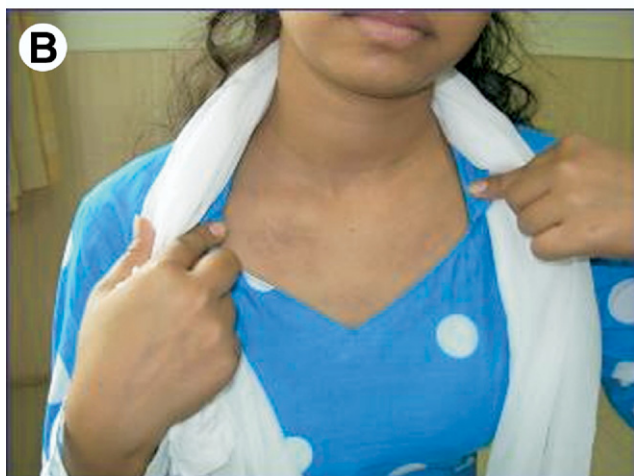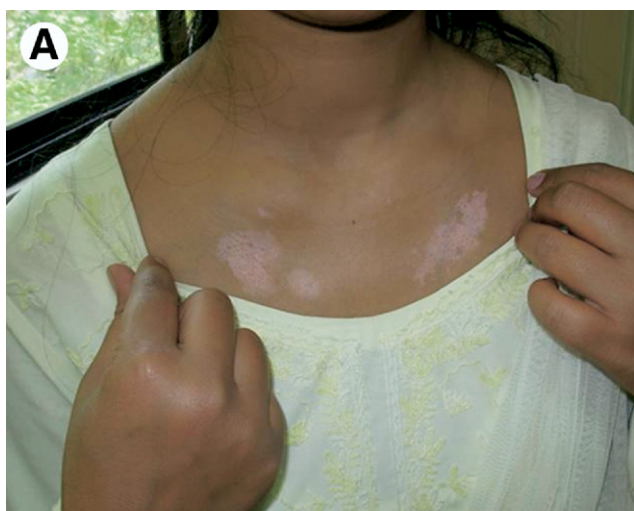**Figure 2** Pre- (a) and post- (b) excimer laser treatment of psoriasis. Courtesy of Bernard Goffe, MD.

## Vitiligo

Vitiligo is an acquired pigmentary disorder of the skin, affecting between 0.5 to 2% of the population worldwide. Traditional treatments for vitiligo include topical corticosteroids, tacrolimus, and PUVA or NB-UVB phototherapy. Localized hypopigmented lesions have shown good response to 308-nm excimer laser irradiation.<sup>30</sup> Similar to clinical findings reported with 311-nm NB-UVB treatment, patches of vitiligo on the face and neck appear to be the most responsive to 308-nm excimer laser therapy (Figs. 3a and b). Studies also suggest that 0.1% tacrolimus ointment in combination with 308-nm excimer laser treatment is superior to 308-nm excimer laser monotherapy for the treatment of UV-resistant vitiliginous lesions (Table 5).<sup>31-33</sup>

## Scars

The use of lasers and light devices in the treatment of scars has been well documented.<sup>34</sup> Laser treatment has been applied across the entire spectrum of scars, including scars resulting from surgery, injury, or disease (eg, acne). As such,



**Figure 3** Pre- (a) and post- (b) excimer laser treatment of vitiligo. Photos courtesy of Sanjay Dubey, MD.

**Table 5** Clinical Advantages of 308-nm Excimer Laser over NB-UVB in the Treatment of Vitiligo

<b>Disease resistant to conventional therapies</b>
<b>Treatment of localized disease</b>
<b>Faster repigmentation with treatment frequency of 2× to 3× per week<sup>33</sup></b>
<b>Treatment of cosmetically-sensitive areas (face, hands)</b>

lasers have become an integral component of scar therapy, with several options available (Table 6). Before treatment initiation, it is important to properly classify the type of scar present to determine which laser would produce optimal improvement.

## Pulsed Dye Laser

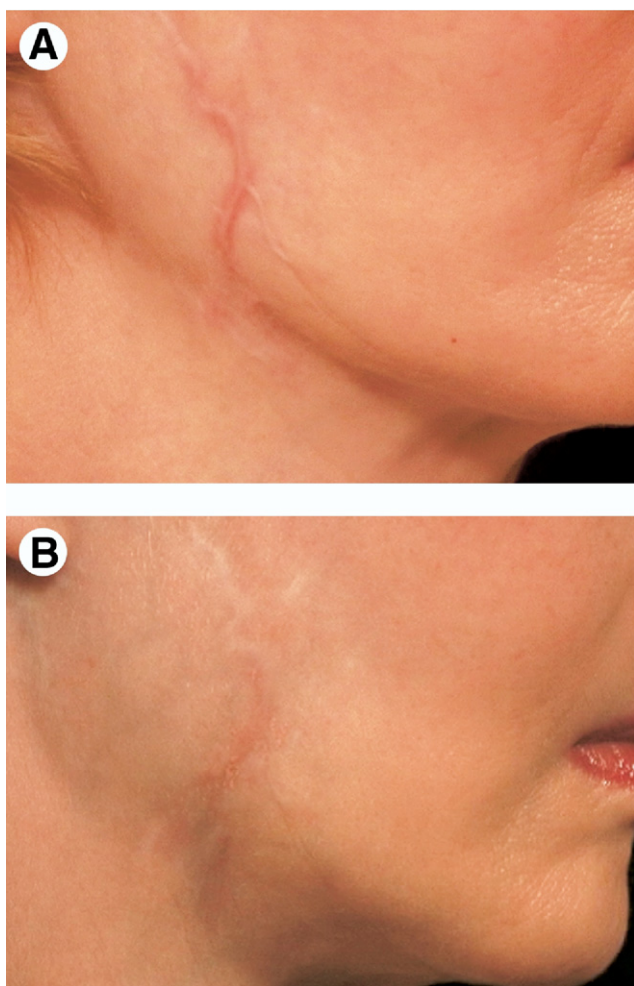
The PDL is one of the mainstays in the treatment of scarring. Published studies using a 585-nm PDL have demonstrated its utility for a wide range of scars, ranging from hypertrophic/keloid scars to erythematous or atrophic scars.<sup>35-39</sup> In addition to the obvious cosmetic enhancement after PDL laser irradiation, measurable improvement of scar erythema, pliability, bulk, and dysesthesia with minimal side effects and treatment discomfort has been reported (Fig. 4a and b).

## Ablative Laser Skin Resurfacing

Carbon dioxide (CO<sub>2</sub>) laser skin resurfacing of moderate atrophic scars yields a mean improvement of 50% to 80%.<sup>40-42</sup> Because collagen remodeling and progressive scar effacement has been reported to occur for up to 12 to 18 months postoperatively, re-treatment of skin areas should be postponed for at least 1 year postoperatively to better gauge the degree of clinical improvement. The Er:YAG laser is also effective in the treatment of atrophic scars, but often does not produce the same amount of collagen remodeling and clinical improvement as does the CO<sub>2</sub> laser and, thus, should be reserved for sculpting of individual scar edges and in the treatment of mild acne scarring.<sup>43,44</sup> Both CO<sub>2</sub> and Er:YAG laser ablative proce-

**Table 6** Laser Selection for Different Scar Types

Scar Type	Clinical	
	Characteristics	Preferred Laser
Hypertrophic	Raised, pink-red limited to site of original trauma	585-nm or 595-nm PDL
Keloid	Raised, deep red-purple, extend beyond original traumatic border	585-nm or 595-nm PDL
Atrophic	Saucer-like or ice-pick indentations	10,600-nm CO <sub>2</sub> 2940-nm erbium 1550-nm erbium-doped fiber 1450-nm diode laser 1320-nm Nd:YAG



**Figure 4** Pre- (a) and post- (b) PDL laser treatment of scar.

dures require a prolonged recovery process (at least 7 to 10 days) in order for re-epithelialization to be completed and several more weeks for erythema to resolve. During the protracted recovery process, a variety of side effects and complications have been reported, including skin dyspigmentation, infection, and even scarring.<sup>45,46</sup>

### Nonablative Laser Skin Remodeling

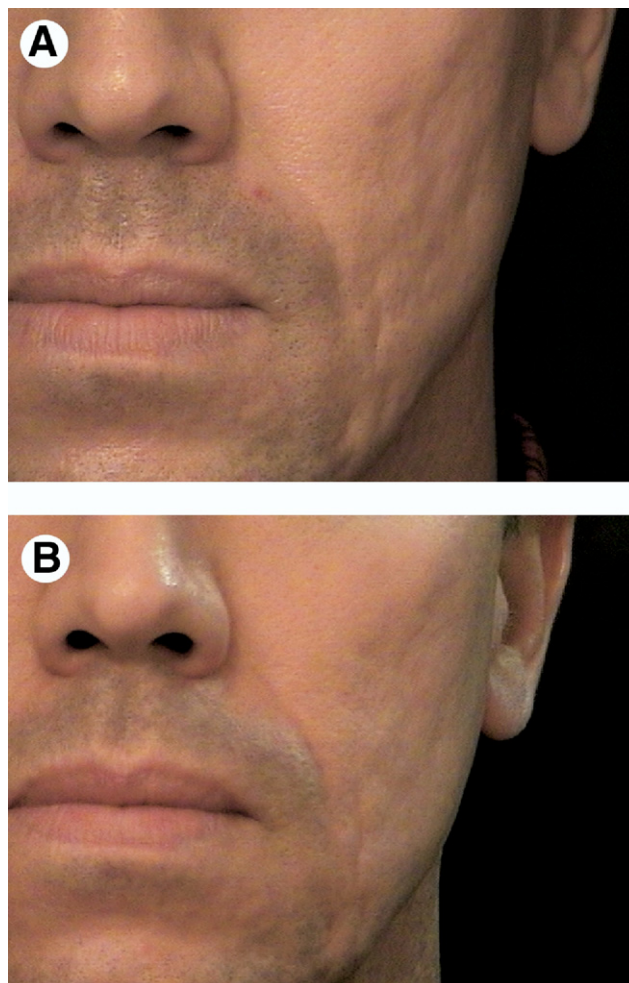As a consequence of the risks associated with ablative laser resurfacing, nonablative laser devices have been studied in the treatment of atrophic facial scars. The most popular and widely used are the 1320-nm Nd:YAG and the 1450-nm diode laser.<sup>47,48</sup> Both systems combine epidermal surface cooling with deeply penetrating infrared wavelengths that selectively target water containing tissues, thereby targeting the dermis while sparing the epidermis. Improvement in scars by 40 to 50% has been observed after 1320-nm Nd:YAG or 1450-nm diode laser treatment (Fig. 5a and b) as assessed by patient satisfaction surveys, histological evaluation, and skin surface (profilometry) measurements.<sup>47</sup>

Although a series of nonablative laser treatments can effect modest improvement in atrophic scars with minimal side effects, the degree of clinical effect does not equal that

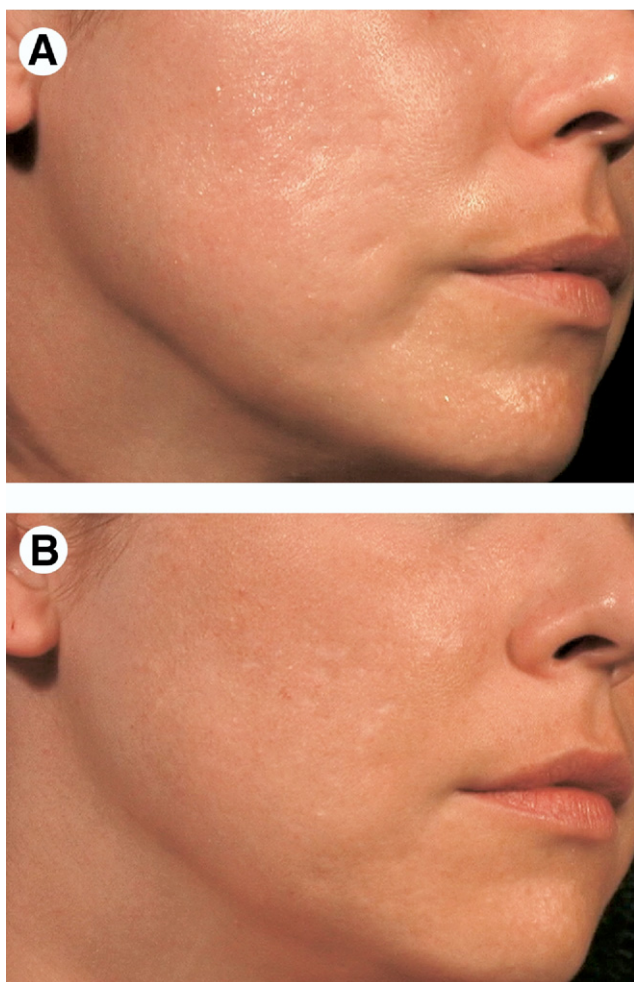of ablative laser resurfacing or fractional laser treatments. It is therefore critical to determine which patients are best suited for nonablative procedures to optimize patient satisfaction.

### Fractional Laser Skin Treatment

Because of a need for more noticeable clinical improvement than these latter nonablative systems can provide, fractional photothermolysis has most recently been introduced into the skin resurfacing market (Fig. 6a and b). These fractionated laser systems involve the use of mid-infrared wavelengths ranging 1440 nm to 1550 nm that create microscopic noncontiguous columns of thermal injury in the dermis (referred to as microscopic thermal zones or MTZ) surrounded by zones of viable tissue.<sup>49</sup> The spatially precise columns of thermal injury produce localized epidermal necrosis and collagen denaturation. Because the tissue surrounding each MTZ is intact, residual epidermal and dermal cells contribute to rapid healing. Maintenance of the stratum corneum ensures continued epidermal barrier function. After a series of three monthly treatments with minimal postoperative recovery, patients



**Figure 5** Pre- (a) and post- (b) Smoothbeam® treatment for atrophic acne scars.



**Figure 6** Pre- (a) and post- (b) Fraxel® laser treatment of atrophic acne scars.

average 50% to 75% improvement in the clinical appearance of their scars.<sup>50</sup>

## References

1. Taub AF: Procedural treatments for acne vulgaris. *33:1005-26*, 2007
2. Tanzi EL, Williams CM, Alster TS: Treatment of Facial rhytides with a nonablative 1,450-nm diode laser: A controlled clinical and histologic study. *Dermatol Surg* 29:124-128, 2003
3. Perez-Maldonado A, Runger TM, Krejci-Papa N: The 1,450-nm diode laser reduces sebum production in facial skin: A possible mode of action of its effectiveness for the treatment of acne vulgaris. *Lasers Surg Med* 39:189-92, 2007
4. Paithankar DY, Ross EV, Saleh BA, et al: Acne treatment with a 1,450-nm wavelength laser and cryogen spray cooling. *Lasers Surg Med* 31:106-114, 2002
5. Friedman PM, Jih MH, Kimyai-Asadi A, et al: Treatment of inflammatory facial acne vulgaris with the 1450-nm diode laser: A pilot study. *Dermatol Surg* 30:147-151, 2004
6. Glaich A, Friedman PM, Jih MH, et al: Treatment of inflammatory facial acne vulgaris with combination 595-nm pulsed dye laser with dynamic-cooling-device and 1,450-nm diode laser. *Lasers Surg Med* 38:177-180, 2006
7. Bernstein EF: A pilot investigation comparing low-energy, double pass 1,450 nm laser treatment of acne to conventional single-pass, high-energy treatment. *Lasers Surg Med* 39:193-198, 2007
8. Lloyd JR, Mirkov M: Selective photothermolysis of the sebaceous glands for acne treatment. *Lasers Surg Med* 31:115-120, 2002.
9. Omi T, Munavalli GS, Kawana S, et al: Ultrastructural evidence for thermal injury to pilosebaceous units during the treatment of acne using photopneumatic (PPX) therapy. *J Cosmet Laser Ther* 10:7-11, 2008
10. Shamban AT, Enokibori M, Narurkar V, et al: Photopneumatic technology for the treatment of acne vulgaris *J Drugs Dermatol* 7:139-145, 2008
11. Wanitphakdeedecha R, Tanzi EL, Alster TS: Treatment of acne with photopneumatic therapy. *J Drugs Dermatol*, in press
12. Ortiz A, Van Vliet M, Lask G, et al: A review of lasers and light sources in the treatment of acne vulgaris. *J Cosmet Laser Ther* 7:69-75, 2005
13. Hongcharu W, Taylor CR, Chang Y, et al: Topical ALA-photodynamic therapy for the treatment of acne vulgaris. *J Invest Dermatol* 115:183-192, 2000
14. Alexiades-Armenakas M: Long-pulsed dye laser-mediated photodynamic therapy combined with topical therapy for mild to severe comedonal, inflammatory, or cystic acne. *J Drugs Dermatol* 2:393-396, 2003
15. Rho NK, Lee DK, Kim S, et al: Efficacy of acne treatment using a combination of radiofrequency energy and indocyanine green-mediated pulsed light phototherapy. *Lasers Surg Med* 40:32, 2008
16. Tuchin V, Genina E, Baskatov, et al: A pilot study of ICG laser therapy of acne vulgaris: Photodynamic and photothermolysis treatment. *Lasers Surg Med* 33:296-310, 2003
17. Barolet D, Boucher A: Pre-PDT use of radiant infrared LED exposure as skin preparation to enhance acne treatment outcome. *Lasers Surg Med* 40:32, 2008
18. Ruiz-Esparza J, Gomez JB: Nonablative radiofrequency for active acne vulgaris: The use of deep dermal heat in the treatment of moderate to severe acne vulgaris (thermotherapy) a report in 22 patients. *Dermatol Surg* 29:333-339, 2003
19. Taneja A, Trehan M, Taylor CR: 308-nm excimer laser for the treatment of psoriasis: induration-based dosimetry. *Arch Dermatol* 139:759-764, 2003
20. Trehan M, Taylor CR: High-dose 308-nm excimer laser for the treatment of psoriasis. *J Am Acad Dermatol* 46:732-737, 2002
21. Tournas JA, Lowe NJ, Yamauchi PS: Laser and novel light source treatments for psoriasis. *Lasers Surg Med* 35:165-173, 2004
22. Gattu S, Rashid R, Wu J: 308-nm excimer laser in psoriasis vulgaris, scalp psoriasis, and palmoplantar psoriasis. *J Eur Acad Dermatol Venereol*, in press
23. Rodewald EJ, Housman TS, Mellen BG, et al: Follow-up survey of 308-nm laser treatment of psoriasis. *Lasers Surg Med* 31:202-206, 2002
24. Taylor CR, Racette AL: A 308-nm excimer laser for the treatment of scalp psoriasis. *Lasers Surg Med* 34:36-140, 2004
25. Ros AM, Garden JM, Bakus AD, et al: Psoriasis response to the pulsed dye laser. *Lasers Surg Med* 19:331-35, 1996
26. Zelickson BD, Mehregan DA, Wendelschfer-Crabb G, et al: Clinical and histologic evaluation of psoriatic plaques treated with a flashlamp pulsed dye laser. *J Am Acad Dermatol* 35:64-68, 1996
27. Reiko N, Keiko K, Akimichi M: Efficacy of the 585 nm pulsed dye laser for treatment of psoriasis. *Jpn J Dermatol* 116:449-54, 2006
28. Taibjee SM, Cheung ST, Lanigan SW: Controlled study of excimer and pulsed dye lasers in the treatment of psoriasis. *Br J Dermatol* 153:960-966, 2005
29. De Leeuw J, Tank B, Bjerring PJ, et al: Concomitant treatment of psoriasis of the hands and feet with pulsed dye laser and topical calcipotriol, salicylic acid, or both: A prospective open study in 41 patients. *J Am Acad Dermatol* 54:266-271, 2006
30. Rivard J, Lim HW: The use of 308-nm excimer laser for dermatoses: experience with 34 patients. *J Drugs Dermatol* 5:550-554, 2006
31. Shen Z, Gao TW, Chen L, et al: Optimal frequency of treatment with the 308-nm excimer laser for vitiligo on the face and neck. *Photomed Laser Surg* 25:418-427, 2007
32. Passeron T, Ostovari N, Zakaria W, et al: Topical tacrolimus and the 308-nm excimer laser: A synergistic combination for the treatment of vitiligo. *Arch Dermatol* 140:1065-1069, 2004

33. Lotti T, Prignano F, Buggiani G: New and experimental treatments of vitiligo and other hypomelanoses. *Dermatol Clin* 25:393-400, 2007
34. Alster TS, Zauyanov-Scanlon L: Laser scar revision: A review. *Dermatol Surg* 33:131-140, 2007
35. Alster TS, Kurban AK, Grove GL, et al: Alteration of argon laser-induced scars by the pulsed dye laser. *Lasers Surg Med* 13:368-373, 1993
36. Alster TS: Improvement of erythematous and hypertrophic scars by the 585-nm flashlamp-pumped pulsed dye laser. *Ann Plast Surg* 32:186-190, 1994
37. Alster TS, Nanni CA: Pulsed dye laser treatment of hypertrophic burn scars. *Plast Reconstr Surg* 102:2190-2195, 1998
38. Dierickx C, Goldman MP, Fitzpatrick RE: Laser treatment of erythematous/hypertrophic and pigmented scars in 26 patients. *Plast Reconstr Surg* 95:84-90, 1995
39. Alster TS, Williams CM: Treatment of keloid sternotomy scars with the 585 nm flashlamp-pumped pulsed-dye laser. *Lancet* 345:1198-1200, 1995
40. Alster TS, West TB: Resurfacing atrophic facial scars with a high-energy pulsed carbon dioxide laser. *Dermatol Surg* 22:151-155, 1996
41. Bernstein LJ, Kauvar ANB, Grossman MC, et al: Scar resurfacing with high-energy, short-pulsed and flash scanning carbon dioxide lasers. *Dermatol Surg* 24:101-107, 1998
42. Walia S, Alster TS: Prolonged clinical and histological effects from CO<sub>2</sub> laser resurfacing of atrophic scars. *Dermatol Surg* 25:926-930, 1999
43. Tanzi EL, Alster TS: Treatment of atrophic facial acne scars with a dual-mode Er:YAG laser. *Dermatol Surg* 28:551-555, 2002
44. Alster TS: Cutaneous resurfacing with CO<sub>2</sub> and erbium:YAG lasers: Preoperative, intraoperative and postoperative considerations. *Plast Reconstr Surg* 103:619-632, 1999
45. Nanni CA, Alster TS: Complications of CO<sub>2</sub> laser resurfacing: An evaluation of 500 patients. *Dermatol Surg* 24:315-320, 1998
46. Tanzi EL, Alster TS: Single-pass CO<sub>2</sub> vs. multiple-pass Er:YAG laser skin resurfacing: A comparison of postoperative wound healing and side effect rates. *Dermatol Surg* 29:80-84, 2003
47. Tanzi EL, Alster TS: Comparison of 1450 nm diode laser and 1320 nm Nd:YAG laser in the treatment of atrophic facial scars: A prospective clinical and histological study. *Dermatol Surg* 30:152-157, 2004
48. Rogachefsky AS, Hussain M, Goldberg DJ: Atrophic and mixed pattern of acne scars with a 1320 nm Nd:YAG laser. *Dermatol Surg* 29:904-908, 2003
49. Manstein D, Herron GS, Sink RK, et al: Fractional photothermolysis: A new concept for cutaneous remodeling using microscopic patterns of thermal injury. *Lasers Surg Med* 34:426-438, 2004
50. Alster TS, Tanzi EL, Lazarus M: The use of fractional photothermolysis in the treatment of atrophic acne scars. *Dermatol Surg* 33:295-299, 2007