



---

# High-Intensity Focused Ultrasound Effectively Reduces Adipose Tissue

Afschin Fatemi, MD

---

Liposonix is considered to be a nonsurgical treatment for body contouring that uses high-intensity focused ultrasound (HIFU) to disrupt adipocytes percutaneously. We wanted to find out about its efficacy, effectiveness, and so forth. The technique delivers energy across the skin surface at a relatively low intensity, but brings this energy to a sharp focus in the subcutaneous fat. At the skin surface, the intensity of the ultrasound energy is low enough so that no damage occurs. The focusing of the ultrasound beam at specific depths beneath the epidermis, combined with proprietary application techniques, results in adipose tissue disruption. Once adipocytes have been disrupted, chemotactic signals activate the body's inflammatory response mechanisms. Macrophage cells are attracted to the area to engulf and transport the lipids and cell debris. This results in an overall reduction in local adipose tissue volume. Our clinical and histologic studies will show exactly what happens under the skin. We did a series of studies on gross pathology and histology, and we tried to correlate these with the clinical results. The histologies show clearly that adipocytes are disrupted by HIFU. The pathologies show the lesions, but they are always at a safe distance from dermis or the epidermis. The correlation between focal depth, energy levels, and clinical results is evident. The average circumference reduction after treatment of the abdomen and waist is 4-5 cm. Liposonix turns out to be a safe and effective technique for nonsurgical body sculpting by reduction of fat deposits.

Semin Cutan Med Surg 28:257-262 © 2009 Elsevier Inc. All rights reserved.

---

A wide range of technologies are available to perform esthetic body sculpting. Some of these are low-energy devices which use low frequency ultrasound, radio frequency,<sup>1</sup> light energy,<sup>2</sup> or a combination of these with<sup>3,4</sup> or without<sup>5</sup> mechanical manipulation to improve body appearance. While noninvasive, they require multiple treatments and can only achieve relatively superficial or temporary effects.<sup>1,2,4,5</sup> An alternative is liposuction, which is proven to be effective but is also invasive and there are possibly serious complications.<sup>6</sup> Further developments in liposuction techniques, such as subdermal,<sup>7</sup> ultrasound, power assisted, and laser-assisted liposuction<sup>8</sup> have become popular but their effect on safety and efficacy is debatable. Serious local and systemic complications are still possible.<sup>9</sup>

Recently, high-intensity focused ultrasound (HIFU) technology is being used for performing noninvasive body sculpting by disrupting unwanted adipose cells. There are 2 mechanisms that result in ablating the adipose tissue. One is

mechanical effects that disrupt the cell membranes immediately. The other mechanism is heat that destroys additional fat cells at temperatures above 58°C, and occurs in the focal spot of HIFU. The result is coagulative necrosis and almost immediate cell death within the targeted area, while the surrounding tissue remains mostly unaffected.<sup>10</sup>

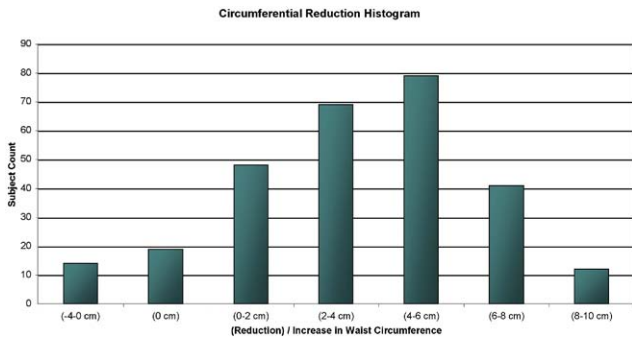
Following HIFU treatment, the dead cells induce a wound healing response, and attract macrophages (along with other cells), which engulf and transport lipids and cellular debris away from the treatment area. Most of the destroyed adipocytes are resorbed within 12 weeks after treatment and 95% are resorbed after 18 weeks. This results in an overall reduction in local fat volume. These changes occur with no significant increases in plasma lipids.<sup>11</sup> The wound healing cascade results in attraction of inflammatory cells, followed by fibroblast induction. This, and collagen denaturation by heat, result in new collagen formation which is followed by tightening of septal fibers and skin.

Possible side effects are sensations of prickling, tingling, warmth, heat, discomfort, or pain during treatment, and temporary erythema, ecchymosis, discomfort, paresthesia, and edema after treatment.

---

S-thetic Clinic Düsseldorf, Düsseldorf, Germany.

Address reprint requests to Afschin Fatemi, MD, S-thetic Clinic Düsseldorf, Kaiserswerther Markt 25 40489, Düsseldorf, Germany. E-mail: fatemi@s-thetic.de

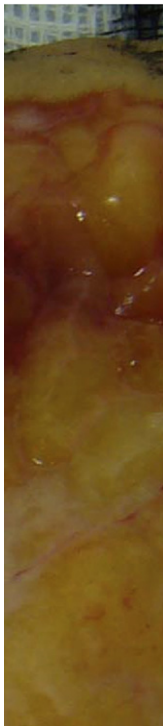


**Figure 1** Change in waist circumference 3 months after a single high-intensity focused ultrasound (HIFU) treatment applied to the abdomen and flank.

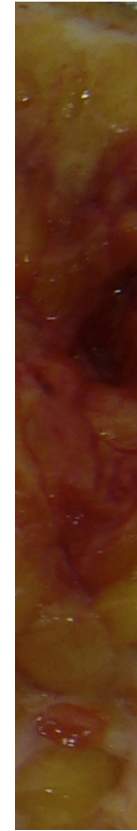## Methods

The S-thetic Clinic, Düsseldorf, is a multidisciplinary clinic offering a wide range of surgical and nonsurgical esthetic procedures. A device which delivers HIFU for noninvasively ablating adipose tissue (the LipoSonix system, Medicis Technologies Corporation, Bothell, WA) was installed in our clinic. The device uses a programmable pattern generator which automatically moves the HIFU to successive focal points within the chosen treatment area, resulting in a uniform matrix of lesions.

To date, more than 350 patients have been safely treated with HIFU by our staff in areas such as the abdomen, waist, hips, outer thighs, inner thighs, buttocks, male lipomastia, and mostly with positive results.



**Figure 2** Gross pathology of abdominoplasty tissue, lesser energy, defined lesion.



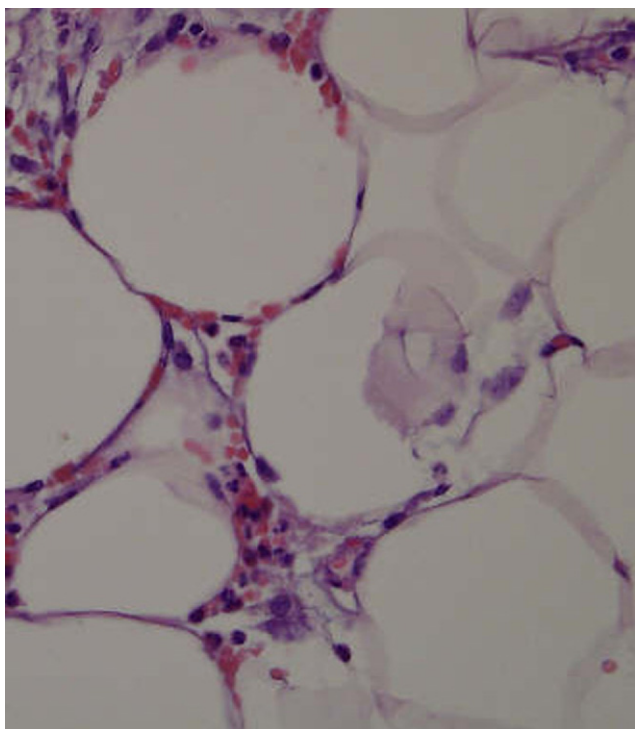
**Figure 3** Gross pathology of abdominoplasty tissue, higher energy, larger defined lesion.

We also treated a group of patients before abdominoplasty. The tissue was then examined in gross pathology, to determine which parameter settings produce which lesion formations. The aim was to determine how to optimize the treatment, and how to produce larger, consistent lesions while keeping the treatment safe.

Several histologies were taken to identify cellular and collagen reactions after HIFU.

The patients described were healthy adults who expressed a desire to undergo elective body sculpting with HIFU. Before performing any procedures, the treating physician carefully evaluated each patient and confirmed that they had a minimum of 1.5 cm adipose tissue beyond the planned HIFU focal depth to be used, and there were no existing contraindications for using HIFU, such as pre-existing abdominal hernias, severe diabetes, or autoimmune diseases. Each patient was counseled with respect to anticipated treatment results to set the appropriate expectations, explain the time required for results to occur, and the potential for the occurrence of adverse events during and after treatment.

The HIFU device was calibrated to deliver a total energy ranging around 140 J/cm<sup>2</sup> or higher, at a focal depth of 1.1-1.8 cm. In all cases, the focal depth was determined by the individual thickness of the adipose tissue being treated. To deliver the appropriate amount of energy, at least 2 passes with the HIFU device were made over the area to be treated.

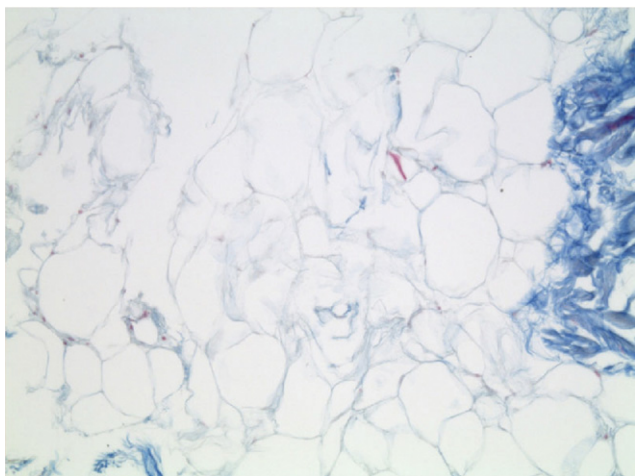


**Figure 4** Histology of adipocytes after treatment with high-intensity focused ultrasound (HIFU), disrupted cells (HE stain).

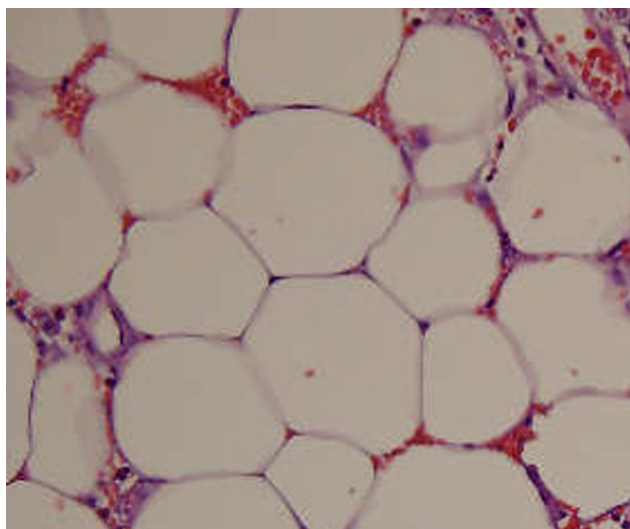
Waist circumference was measured before treatment and again after 12 weeks.

## Results

For this report, a total of 282 patients with a mean age of 41.3 years underwent a single HIFU treatment, which included areas of the anterior abdomen and flanks. The time required to complete treatment was approximately 45-60 minutes. Using different treatment protocols, the waist circumference decreased by an average of 4.7 cm after 1 treatment with 2 different focal depths after 3 months. A



**Figure 5** Histology of adipocytes after treatment with high-intensity focused ultrasound (HIFU), collapsed membranes (Azan stain).

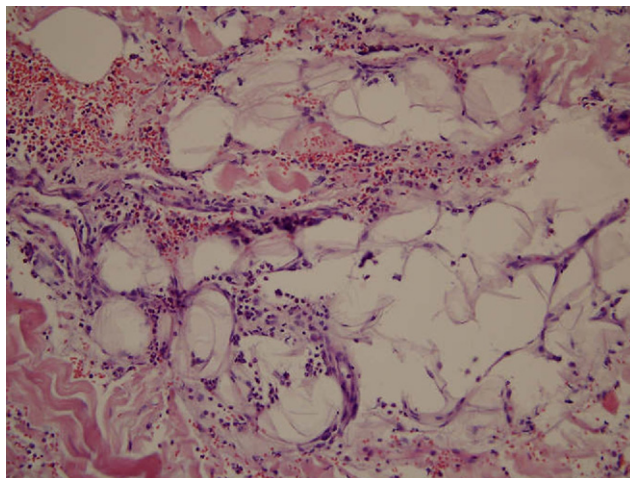


**Figure 6** Histology of adipocytes after treatment with a low-energy ultrasonic device, adipocytes are still intact.

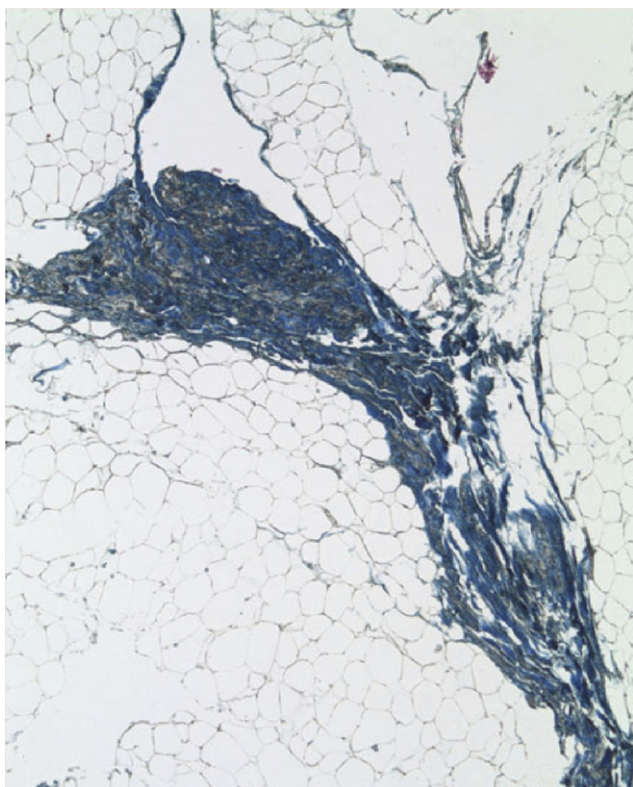
histogram showing the results achieved in all 282 patients is provided in Fig. 1.

The abdominoplasty tissues showed very well-defined impact zones in gross pathology. The lesions always had a safe and consistent distance from the epidermis and dermis. More energy produced larger lesions. The treatment with HIFU resulted in predictable lesions depending on energy levels, as seen in Figures 2 and 3.

The histologies showed disrupted adipocytes with collapsed membranes immediately after HIFU treatment as shown in Figures 4 and 5, vs no visibly damaged cells after a treatment with a low-energy ultrasonic device, as seen in Figure 6. The induced and expected wound healing response was seen in tissues 2 weeks after the treatment, as seen in Figure 7. Histologies also showed impacts on septal fibers, and collagen fibers were disrupted or denatured as shown in Figure 8.



**Figure 7** Histology of adipose tissue, 2 weeks after treatment with high-intensity focused ultrasound (HIFU), influx of inflammatory cells, macrophages engulf cellular debris, and free lipids.



**Figure 8** Histology of septal fibers after treatment with high-intensity focused ultrasound (HIFU), denatured collagen fibers, next to disrupted adipocytes.

## Safety

Among the patients undergoing HIFU treatment, 38 (13.5%) reported one or more adverse events, including prolonged tenderness after treatment ( $n = 10$ ), edema ( $n = 6$ ), hard lumps ( $n = 3$ ), significant ecchymosis ( $n = 28$ ), and significant pain during treatment ( $n = 5$ ). However, none of these events were serious, all were temporary, and there was no

**Table 1** Case Reports. Each Patient Received a Single High-Intensity Focused Ultrasound (HIFU) Treatment

<b>Case 1. 27-year-old female— abdomen and flank</b>	
Energy level	74 and 52 J/cm <sup>2</sup>
Focal depth	1.3 cm
Passes	2
Change in waist circumference	−5.5 cm over 12 wk
<b>Case 2. 32-year-old female— outer thighs</b>	
Energy level	74 J/cm <sup>2</sup>
Focal depth	1.1 and 1.3 cm
Passes	2
Change in thigh circumference	−3.0 cm over 12 wk
<b>Case 3. 38-year-old female— outer and inner thighs</b>	
Energy level	74 and 52 J/cm <sup>2</sup>
Focal depth	1.3 and 1.6 cm
Passes	2 (3)
Change in thigh circumference	−5.4 cm over 12 wk

**Table 2** Analysis of Energy Level Applied and Change in Waist Circumference

Energy level applied	≤126 J/cm <sup>2</sup> n = 50	>133 J/cm <sup>2</sup> n = 57
Change in waist circumference (cm)	−4.2	−4.6
	<i>P</i> = 0.42	

The highest and lowest energy doses were compared using the median energy dose as the cut-off.

evidence to suggest these adverse events were dose-related. The 5 reports of significant pain immediately resolved when treatment was completed. The hard lumps, tenderness, and ecchymosis resolved in ≤4 weeks and edema resolved in ≤12 weeks.

## Case Studies

The results of HIFU body sculpting achieved by several representative patients are described below (Table 1). These data are also summarized in Table 2.

Case 1 was a 27-year-old woman who received a single treatment to her abdomen and flanks. The HIFU parameters used were 2 passes of 74 and 52 J/cm<sup>2</sup> at a focal depth of 1.3 cm. This patient experienced a 4.5-cm reduction in waist circumference after 8 weeks and 5.5 cm after 12 weeks (Fig. 9).

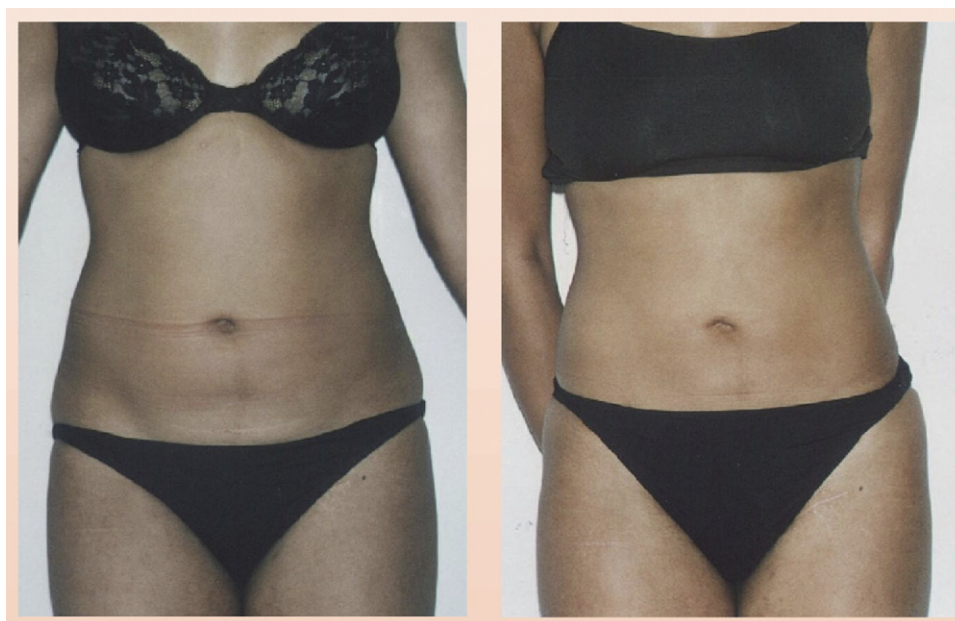Case 2 was a 32-year-old woman who received a single treatment to her outer thighs. The HIFU parameters used were 2 passes of 74 J/cm<sup>2</sup> at a focal depth of 1.1 and 1.3 cm. This patient experienced a 3.0-cm reduction in circumference after 12 weeks (Fig. 10).

Case 3 was a 38-year-old woman who received a single treatment to her outer and inner thighs. The HIFU parameters used were 2 passes of 74 J/cm<sup>2</sup> at a focal depth of 1.3 and 1.6 cm, and a third pass of 52 J/cm<sup>2</sup> at a focal depth of 1.3 cm on the areas where more reduction was desired. This patient experienced a 5.4-cm reduction in circumference after 12 weeks (Fig. 11).

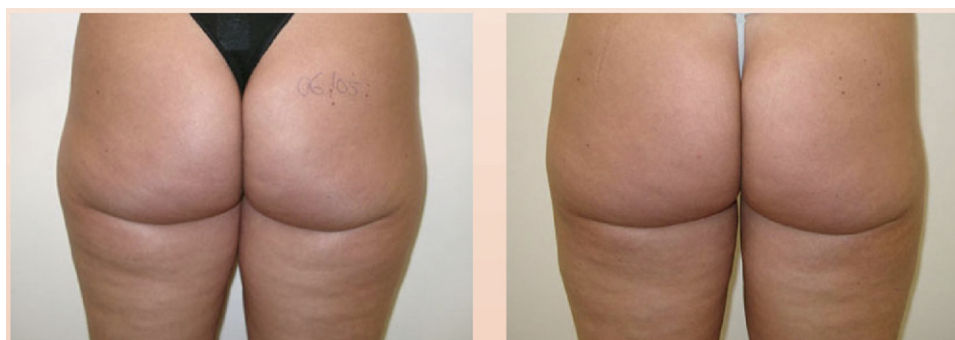## Discussion

To our knowledge, this is the largest case series of patients undergoing HIFU treatment for body sculpting reported to date. In our clinic, the HIFU system safely and effectively reduced patient body circumference by reducing some amount of excess subcutaneous adipose tissue from the abdomen and flanks, or from the thighs. Using this new device, a single HIFU treatment with 2 different focal depths reduced mean circumference by approximately 4.7 cm. A few patients did not achieve their desired results and in some instances this was due to changes in the patient's weight. For example, a 4 cm increase in waist circumference in 1 patient was associated with a 6 kg increase in body weight. In some other patients, the applied energy levels were too little.

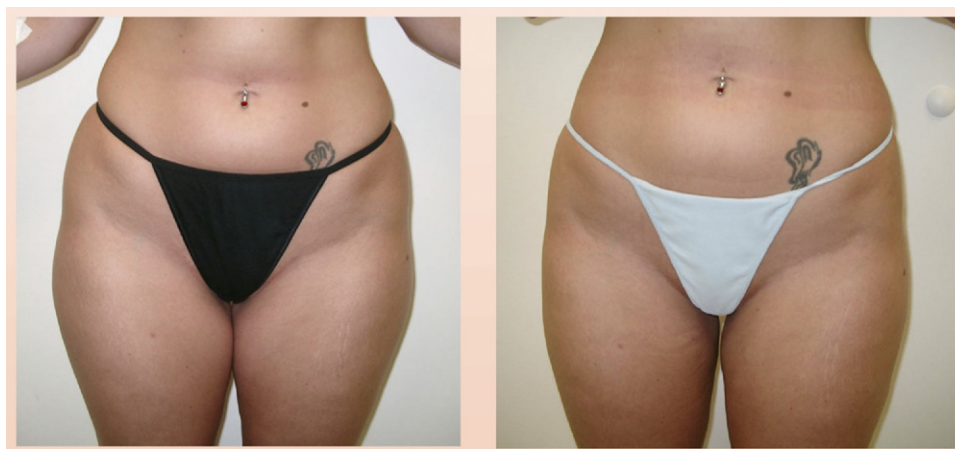
Overall, these results compare favorably with a smaller cohort of patients treated in our clinic using HIFU applied only to abdominal adipose tissue ( $n = 40$ ). These patients were treated with 2 passes of HIFU, calibrated to deliver a



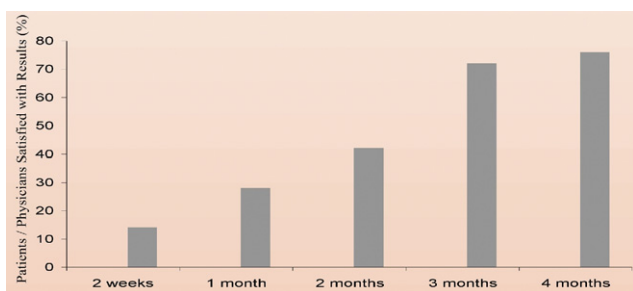
**Figure 9** A 27-year-old woman; abdomen and flanks treated.



**Figure 10** A 32-year-old woman; outer thighs treated.



**Figure 11** A 38-year-old woman; outer and inner thighs treated.



**Figure 12** Patient satisfaction with change in waist circumferences 3 months after a single high-intensity focused ultrasound (HIFU) treatment applied to the abdomen only or to the abdomen and flank.

total energy of 104-148 J/cm<sup>2</sup> (mean energy 127.9 J/cm<sup>2</sup>), to the anterior abdomen at a focal depth of 1.1-1.6 cm. Among these patients, the mean reduction in waist circumference was 2.9 cm (range, +2 to -7 cm) after 3 months.

During a 4-month post-treatment follow-up visit, 50 patients were randomly selected to complete an informal survey to assess their overall satisfaction with the procedure and achievements in the reduction of their waist circumference. Regardless of what areas were treated, more than 70% of patients were satisfied with the reduction in circumference after 3 months. It is noteworthy that the high satisfaction rates continued after 4 months (Fig. 12).

Using the median energy dose as a cut-off, a post hoc analysis of the data examined the highest and lowest amounts of energy applied vs changes in waist circumference. Patients treated with >133 J/cm<sup>2</sup> achieved an average waist reduction of 4.6 cm although this was not significantly greater than the 4.2-cm reduction achieved by patients treated with ≤126 J/cm<sup>2</sup> ( $P = 0.42$ ). Thus, our experience reveals that higher energy levels are not required to achieve satisfactory results. However, data from abdominoplasty tissue examination indicate that the minimum energy levels per pass should be >47 J/cm<sup>2</sup>.

Because of the noninvasive nature of HIFU therapy, patients require no recovery time. In addition, there is no need for general anesthesia and no risk of severe post-treatment complications, such as infection. A recent survey performed in Germany revealed 72 cases of severe complications and 23 deaths following cosmetic surgical liposuction over a 5-year

period. The most frequent serious complications were bacterial infections followed by hemorrhaging, visceral perforations, and pulmonary embolism.<sup>6</sup> Based on our initial results, HIFU represents a noninvasive and safe treatment option in reducing unwanted adipose tissue.

## Conclusions

HIFU applied to the abdomen and flanks, with a mean energy dose of 137 J/cm<sup>2</sup>, divided in 2 passes and 2 different focal depths resulted in a mean waist circumference reduction of 4.7 cm. Adverse events were mild and resolved spontaneously. HIFU appears to represent a safe, noninvasive, effective method of body sculpting.

## References

1. van der Lugt C, Romero C, Ancona D, et al: A multicenter study of cellulite treatment with a variable emission radio frequency system. *Dermatol Ther* 22:74-84, 2009
2. Nootheti PK, Magpantay A, Yosowitz G, et al: A single center, randomized, comparative, prospective clinical study to determine the efficacy of the VelaSmooth system versus the Triactive system for the treatment of cellulite. *Lasers Surg Med* 38:908-912, 2006
3. Kulick M: Evaluation of a combined laser-radio frequency device (Polaris WR) for the nonablative treatment of facial wrinkles. *J Cosmet Laser Ther* 7:87-92, 2005
4. Sadick N, Magro C: A study evaluating the safety and efficacy of the VelaSmooth system in the treatment of cellulite. *J Cosmet Laser Ther* 9:15-20, 2007
5. Romero C, Caballero N, Herrero M, et al: Effects of cellulite treatment with RF, IR light, mechanical massage and suction treating one buttock with the contralateral as a control. *J Cosmet Laser Ther* 10:193-201, 2008
6. Lehnhardt M, Homann HH, Daigeler A, et al: Major and lethal complications of liposuction: A review of 72 cases in Germany between 1998 and 2002. *Plast Reconstr Surg* 121:396e-403e, 2008
7. Gasperoni C, Gasperoni P: Subdermal liposuction: Long-term experience. *Clin Plast Surg* 33:63-73, 2006
8. Goldman A, Gotkin RH: Laser-assisted liposuction. *Clin Plast Surg* 36:241-253, 2009
9. Katz B, McBean J: Laser-assisted lipolysis: A report on complications. *J Cosmet Laser Ther* 10:2331-2333, 2008
10. Ter Haar G, Coussios C: High intensity focused ultrasound: Physical principles and devices. *Int J Hyperthermia* 23:89-104, 2007
11. Fodor PB, Smoller BR, Stecco KA, et al: Biochemical changes in adipocytes and lipid metabolism secondary to the use of high-intensity focused ultrasound for non-invasive body sculpting. Presented at the Annual Meeting of the American Society of Aesthetic Plastic Surgery, April, 2006, Orlando, FL