

GREGORY W. RUTECKI, MD, Section Editor

ZAID ZOUMOT, MBBS

Respiratory and Critical Care Institute,
Cleveland Clinic Abu Dhabi,
Abu Dhabi, UAE

ALI S. WAHLA, MBBS

Respiratory and Critical Care Institute,
Cleveland Clinic Abu Dhabi,
Abu Dhabi, UAE

SAMAR FARHA, MD

Respiratory and Critical Care Institute,
Cleveland Clinic Abu Dhabi,
Abu Dhabi, UAE

Rapidly progressive pleural effusion

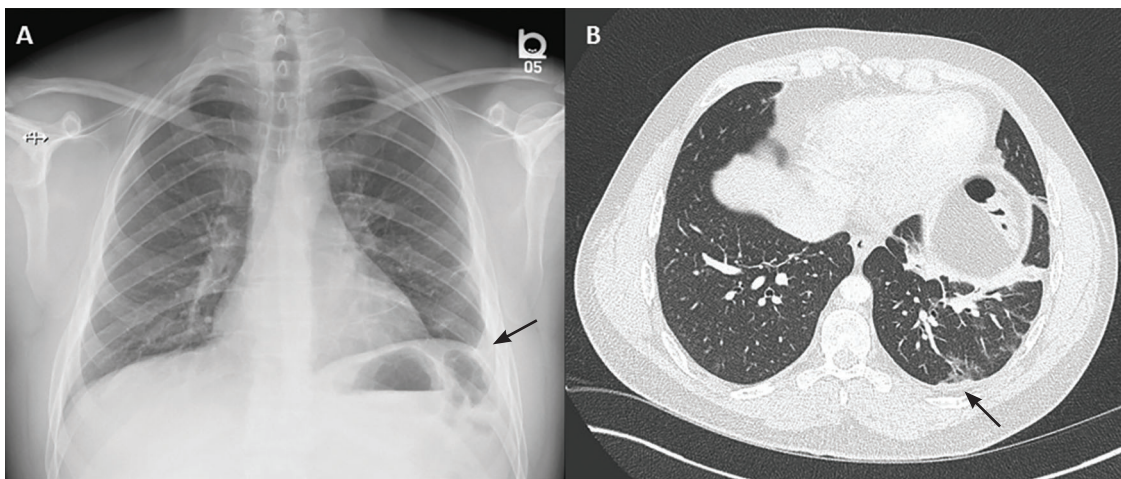


Figure 1. Chest radiography in the emergency department (A) showed a mild left-sided pleural reaction (arrow). Computed tomography (B) showed a mild pleural reaction (arrow) and parenchymal atelectatic and fibrotic changes.

A 33-YEAR-OLD MALE NONSMOKER with no significant medical history presented to the pulmonary clinic with severe left-sided pleuritic chest pain and mild breathlessness for the past 5 days. He denied fever, chills, cough, phlegm, runny nose, or congestion.

Five days before this visit, he had been seen in the emergency department with mild left-sided pleuritic chest pain. His vital signs at that time had been as follows:

- Blood pressure 141/77 mm Hg
- Heart rate 77 beats/minute
- Respiratory rate 17 breaths/minute
- Temperature 36.8°C (98.2°F)
- Oxygen saturation 98% on room air.

No abnormal findings on physical examination were noted at that time. Radiography and computed tomography (CT) (**Figure 1**) showed inflammatory and atelectatic changes in the left lower lobe, with mild pleural reac-

doi:10.3949/ccjm.86a.18067

tion, and results of laboratory testing were:

- White blood cell count $6.89 \times 10^9/L$ (reference range 3.70–11.00)
- Neutrophils 58% (40%–70%)
- Lymphocytes 29.6% (22%–44%)
- Monocytes 10.7% (0–11%)
- Eosinophils 1% (0–4%)
- Basophils 0.6% (0–1%)
- Troponin T and D-dimer levels normal.

DIFFERENTIAL DIAGNOSIS OF PLEURITIC CHEST PAIN

1 What is the most likely cause of his pleuritic chest pain?

- Pleuritis
- Pneumonia
- Pulmonary embolism
- Malignancy

The differential diagnosis of pleuritic chest pain is broad.

A 33-year-old nonsmoker presented with severe pleuritic chest pain; the differential diagnosis is broad

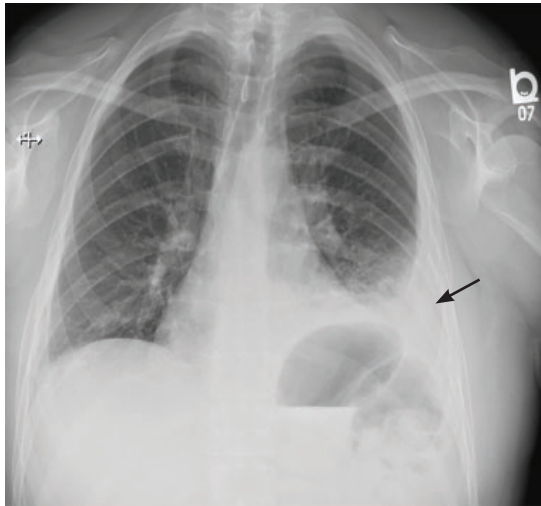


Figure 2. Chest radiography 5 days after the emergency department presentation showed development of a left-sided pleural effusion.

5 days after presentation: worsening pleuritic chest pain, elevated white blood cells, and a small pleural effusion

The patient’s symptoms at presentation to the emergency department did not suggest an infectious process. There was no fever, cough, or phlegm, and his white blood cell count was normal. Nonetheless, pneumonia could not be ruled out, as the lung parenchyma was not normal on radiography, and the findings could have been consistent with an early or resolving infectious process.

Pulmonary embolism was a possibility, but his normal D-dimer level argued against it. Further, the patient subsequently underwent CT angiography, which ruled out pulmonary embolism.

Malignancy was unlikely in a young non-smoker, but follow-up imaging would be needed to ensure resolution and rule this out.

The emergency department physician diagnosed inflammatory pleuritis and discharged him home on a nonsteroidal anti-inflammatory drug.

CLINIC VISIT 5 DAYS LATER

At his pulmonary clinic visit 5 days later, the patient reported persistent but stable left-sided pleuritic chest pain and mild breathlessness on exertion. His blood pressure was 137/81 mm Hg, heart rate 109 beats per minute, temperature 37.1°C (98.8°F), and oxygen saturation 97% on room air.

Auscultation of the lungs revealed rales and slightly decreased breath sounds at the left base. No dullness to percussion could be detected.

Because the patient had developed mild tachycardia and breathlessness along with clinical signs that suggested worsening infiltrates, consolidation, or the development of pleural effusion, he underwent further investigation with chest radiography, a complete blood cell count, and measurement of serum inflammatory markers.

Radiography revealed a left-sided pleural effusion (**Figure 2**). Laboratory testing results:

- White blood cell count $13.08 \times 10^9/L$
- Neutrophils 81%
- Lymphocytes 7.4%
- Monocytes 7.2%
- Eosinophils 0.2%
- Basophils 0.2%
- Procalcitonin 0.34 $\mu g/L$ (reference range < 0.09).

Bedside ultrasonography to assess the effusion’s size and characteristics and the need for thoracentesis indicated that the effusion was too small to tap, and there were no fibrinous strands or loculations to suggest empyema.

FURTHER TREATMENT

2 What was the best management strategy for this patient at this time?

- Admit to the hospital for thoracentesis and intravenous antibiotics
- Give oral antibiotics with close follow-up
- Perform thoracentesis on an outpatient basis and give oral antibiotics
- Repeat chest CT

The patient had worsening pleuritic pain with development of a small left pleural effusion. His symptoms had not improved on a nonsteroidal anti-inflammatory drug. He now had an elevated white blood cell count with a “left shift” (ie, an increase in neutrophils, indicating more immature cells in circulation) and elevated procalcitonin. The most likely diagnosis was pneumonia with a resulting pleural effusion, ie, parapneumonic effusion, requiring appropriate antibiotic therapy. Ideally, the pleural effusion should be sampled by thoracentesis,

TABLE 1

Prognostic assessment of pleural effusion: the American College of Chest Physicians guidelines

Pleural space anatomy		Pleural fluid bacteriology		Pleural fluid chemistry	Category	Risk of poor outcome	Drainage
Minimal, free-flowing effusion (< 10 mm on lateral decubitus image)	and	Culture and Gram stain results unknown	and	pH unknown	1	Very low	No
Small to moderate free-flowing effusion (> 10 mm and < 1/2 hemithorax)	and	Negative culture and Gram stain	and	pH \geq 7.20	2	Low	No
Large, free-flowing effusion (\geq 1/2 hemothorax), loculated effusion, or effusion with thickened parietal pleura	or	Positive culture and Gram stain	or	pH < 7.20	3	Moderate	Yes
		Pus			4	High	Yes

Reprinted from Coulice et al,¹ with permission from Elsevier; www.sciencedirect.com/science/journal/chest.

with management on an outpatient or inpatient basis.

Suspected parapneumonic effusion can be classified to help prognostication based on anatomic, bacteriologic, and chemical characteristics of the fluid, as described in the American College of Chest Physicians classification system (Table 1).¹ Although our patient's effusion was deemed to pose a low risk for a poor outcome, admission to the hospital was advised for intravenous antibiotics and close monitoring of the effusion with or without thoracentesis or drainage. However, the patient declined, preferring outpatient treatment. Levofloxacin was started, and he was scheduled to be seen in follow-up in the clinic a few days later.

■ 5 DAYS LATER, THE EFFUSION HAD BECOME MASSIVE

On follow-up 5 days later, the patient's chest pain was better, but he was significantly more short of breath. His blood pressure was 137/90 mm Hg, heart rate 117 beats/minute, respiratory rate 16 breaths/minute, oxygen saturation 97% on room air, and temperature 36.9°C (98.4°F). Chest auscultation revealed decreased breath

sounds over the left hemithorax, with dullness to percussion and decreased fremitus.

Repeat chest radiography showed complete opacification of the left hemithorax, and CT showed a massive pleural effusion causing mediastinal shift to the right (Figure 3).

■ RAPIDLY PROGRESSIVE PLEURAL EFFUSIONS

A rapidly progressive pleural effusion in a healthy patient suggests parapneumonic effusion. The most likely organism is streptococcal.²

Explosive pleuritis is defined as a pleural effusion that increases in size in less than 24 hours. It was first described by Braman and Donat³ in 1986 as an effusion that develops within hours of admission. In 2001, Sharma and Marrie⁴ refined the definition as rapid development of pleural effusion involving more than 90% of the hemithorax within 24 hours, causing compression of pulmonary tissue and a mediastinal shift. It is a medical emergency that requires prompt investigation and treatment with drainage and antibiotics. All reported cases of explosive pleuritis have been

**At day 10:
a massive
pleural effusion
causing
mediastinal
shift
to the right**

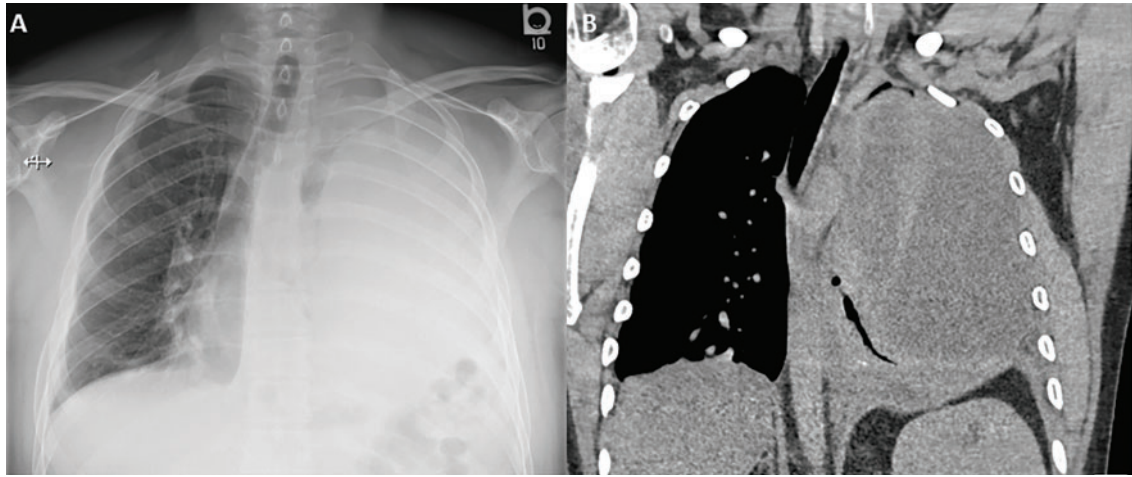


Figure 3. Complete opacification of the left hemithorax on chest radiography (A) and massive pleural effusion causing mediastinal shift to the right on computed tomography (B).

Explosive pleural effusion is a medical emergency that requires prompt investigation and treatment with drainage and antibiotics

parapneumonic effusion.

The organisms implicated in explosive pleuritis include gram-positive cocci such as *Streptococcus pneumoniae*, *S pyogenes*, other streptococci, staphylococci, and gram-negative cocci such as *Neisseria meningitidis* and *Moraxella catarrhalis*. Gram-negative bacilli include *Haemophilus influenzae*, *Klebsiella pneumoniae*, *Pseudomonas* species, *Escherichia coli*, *Proteus* species, *Enterobacter* species, *Bacteroides* species, and *Legionella* species.^{4,5} However, malignancy is the most common cause of massive pleural effusion, accounting for 54% of cases; 17% of cases are idiopathic, 13% are parapneumonic, and 12% are hydrothorax related to liver cirrhosis.⁶

■ **CASE CONTINUED**

Our patient’s massive effusion needed drainage, and he was admitted to the hospital for further management. Samples of blood and sputum were sent for culture. Intravenous piperacillin-tazobactam was started, and an intercostal chest tube was inserted into the pleural cavity under ultrasonographic guidance to drain turbid fluid.

The effusion was noted to be loculated on ultrasonography, strongly suggesting conversion from parapneumonic effusion to empyema.

Results of pleural fluid analysis and blood tests (Table 2) were consistent with an

exudate based on the criteria of Light et al (Table 3).⁷ The pH of the pleural fluid was 7, confirming empyema. (A pleural fluid pH < 7.2 indicates empyema requiring intervention, whereas a pH between 7.2 and 7.3 indicates parapneumonic effusion that can be either observed or drained, depending on the clinical picture, size, and prognostic features.)

Multiple pleural fluid samples sent for bacterial, fungal, and acid-fast bacilli culture were negative. Blood and sputum cultures also showed no growth. The administration of oral antibiotics for 5 days on an outpatient basis before pleural fluid culture could have led to sterility of all cultures.

Follow-up CT 2 days after the chest tube was inserted revealed a residual apical locule, which did not appear to be communicating with the pleural area where the existing drain sat (Figure 4).

Our patient had inadequate pleural fluid output through his chest tube, and radiography showed that the pleural collections failed to clear. In fact, an apical locule did not appear to be connecting with the lower aspect of the pleural collection. In such cases, instillation of intrapleural agents through the chest tube has become common practice in an attempt to lyse adhesions, to connect various locules or pockets of pleural fluid, and to improve drainage.

LOCULATED EMPYEMA: MANAGEMENT

3 What was the best management strategy for this loculated empyema?

- Continue intravenous antibiotics and existing chest tube drainage for 5 to 7 days, then reassess
- Continue intravenous antibiotics and instill intrapleural fibrinolytics (eg, tissue plasminogen activator [tPA]) through the existing chest tube
- Continue intravenous antibiotics and instill intrapleural fibrinolytics with deoxyribonuclease (DNase) into the existing chest tube
- Continue intravenous antibiotics, insert a second chest tube into the apical pocket under imaging guidance, and instill tPA and DNase
- Surgical decortication

Continuing antibiotics with existing chest tube drainage and the two options of using single-agent intrapleural fibrinolytics have been shown to be less effective than combining tPA and DNase when managing a loculated empyema. As such, surgical decortication, attempting intrapleural instillation of fibrinolytics and DNase (with or without further chest tube insertion into noncommunicating locules), or both were the most appropriate options at this stage.

MANAGEMENT OF PARAPNEUMONIC PLEURAL EFFUSION IN ADULTS

There are several options for managing parapneumonic effusion, and clinicians can use the classification system in **Table 1** to assess the risk of a poor outcome and to plan the management. Based on radiographic findings and pleural fluid sampling, a pleural effusion can be either observed or drained.

Options for drainage of the pleural space include repeat thoracentesis, surgical insertion of a chest tube, or image-guided insertion of a small-bore catheter. Although no randomized trial has been done to compare tube sizes, a large retrospective series showed that small-bore tubes (< 14 F) perform similarly to standard large-bore tubes.⁸ However, in another study, Keeling et al⁹ reported higher failure rates when tubes smaller than

TABLE 2

Our patient’s pleural fluid analysis

Test	Value
Pleural fluid analysis	
Glucose	0.8 mmol/L
Total protein	53 g/L
Lactate dehydrogenase	687 IU/L
Triglyceride	0.75 mmol/L
Cholesterol	2.41 mmol/L
pH	7.00
Gram stain	No organism seen
Culture (bacterial, fungal, acid-fast bacilli)	No growth
Serum levels	
Lactate dehydrogenase	228 IU/L
Protein	71 g/L

TABLE 3

Transudate or exudate? The Light criteria

The fluid is defined as an exudate if at least 1 of the following 3 criteria is met:

- Ratio of pleural fluid protein to serum protein > 0.5
- Ratio of pleural fluid lactate dehydrogenase (LDH) to serum LDH > 0.6
- Pleural fluid LDH more than 2/3 the upper limits of the laboratory normal serum LDH

Information from Light et al, reference 7.

12 F were used. Regular flushing of the chest tube (ideally twice a day) is recommended to keep it patent, particularly with small-bore tubes. Multiloculated empyema may require multiple intercostal chest tubes to drain completely, and therefore small-bore tubes are recommended.

In cases that do not improve radiographically and clinically, one must consider whether the antibiotic choice is adequate, review the position of the chest tube, and assess for loculations. As such, repeating chest CT within 24 to 48 hours of tube insertion and drainage

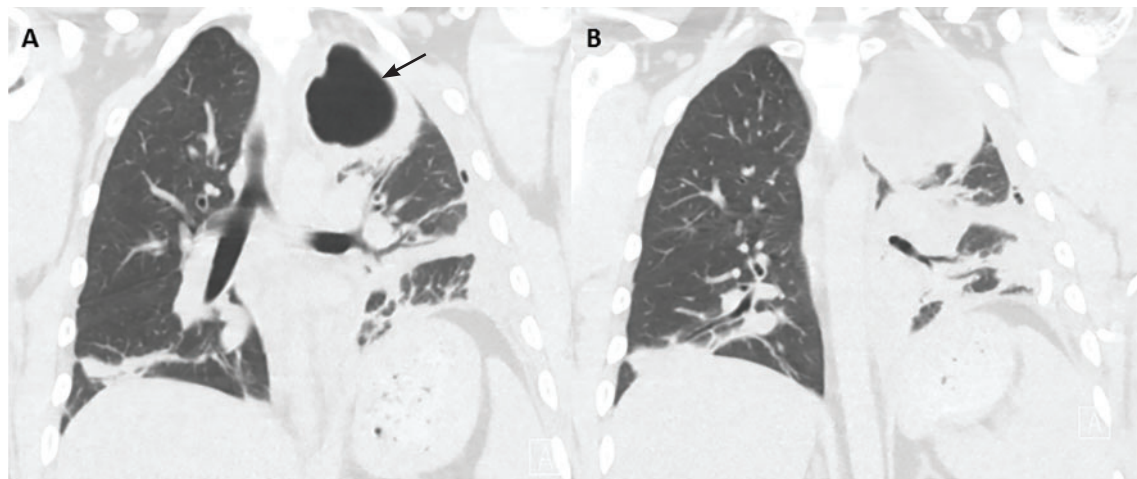


Figure 4. Computed tomography 2 days after initial chest tube placement showed a non-communicating apical pocket.

is recommended to confirm adequate tube positioning, assess effective drainage, look for different locules and pockets, and determine the degree of communication between them.

The largest well-powered randomized controlled trials of intrapleural agents in the management of pleural infection, the Multi-centre Intrapleural Sepsis Trial (MIST1)¹⁰ and MIST2,¹¹ clearly demonstrated that intrapleural fibrinolytics were not beneficial when used alone compared with placebo. However, in MIST2, the combination of tPA and DNase led to clinically significant benefits including radiologic improvement, shorter hospital stay, and less need for surgical decortication.

At our hospital, we follow the MIST2 protocol using a combination of tPA and DNase given intrapleurally twice daily for 3 days. In our patient, we inserted a chest tube into the apical pocket under ultrasonographic guidance, as 2 instillations of intrapleural tPA and DNase did not result in drainage of the apical locule.

Success rates with intrapleural tPA-DNase for complicated pleural effusion and empyema range from 68% to 92%.¹²⁻¹⁵ Pleural thickening and necrotizing pneumonia and abscess are important predictors of failure of tPA-DNase therapy and of the need for surgery.^{13,14}

Early surgical intervention was another reasonable option in this case. The decision to proceed with surgery is based on need to debride multiloculated empyemas or uniloculated empyemas that fail to resolve with

antibiotics and tube thoracostomy drainage. Nonetheless, the decision must be individualized and based on factors such as the patient's risks vs possible benefit from a surgical procedure under general anesthesia, the patient's ability to tolerate multiple thoracentesis procedures and chest tubes for a potentially lengthy period, the patient's pain threshold, the patient's wishes to avoid a surgical procedure balanced against a longer hospital stay, and cultural norms and beliefs.

Surgical options include video-assisted thoracoscopy, thoracotomy, and open drainage. Decortication can be considered early to control pleural sepsis, or late (after 3 to 6 months) if the lung does not expand. Debate continues on the optimal timing for video-assisted thoracoscopy, with data suggesting that when the procedure is performed later in the course of the disease there is a greater chance of complications and of the need to convert to thoracotomy.

A 2017 Cochrane review¹⁶ of surgical vs nonsurgical management of empyema identified 8 randomized trials, 6 in children and 2 in adults, with a total of 391 patients. The authors compared video-assisted thoracoscopy vs tube thoracotomy, with and without intrapleural fibrinolytics. They noted no difference in rates of mortality or procedural complications. However, the mean length of hospital stay was shorter with video-assisted thoracoscopy than with tube thoracotomy (5.9 vs 15.4 days). They could not assess the impact of fi-

Multiloculated empyema may require multiple intercostal chest tubes to drain completely

brinolytic therapy on total cost of treatment in the 2 groups.

A randomized trial is planned to compare early video-assisted thoracoscopy vs treatment with chest tube drainage and t-PA-DNase.¹⁷

At our institution, we use a multidisciplinary approach, discussing cases at weekly meetings with thoracic surgeons, pulmonologists, infectious disease specialists, and interventional radiologists. We generally try conservative management first, with chest tube drainage and intrapleural agents for 5 to 7 days, before considering surgery if the response is unsatisfactory.

THE PATIENT RECOVERED

In our patient, the multiloculated empyema was successfully cleared after intrapleural instillation of 4 doses of tPA and DNase over 3 days and insertion of a second intercostal chest tube into the noncommunicating apical locule. He completed 14 days of intravenous piperacillin-tazobactam treatment and, after discharge home, completed another 4 weeks of oral amoxicillin-clavulanate. He made a full recovery and was back at work 2 weeks after discharge. Chest radiography 10 weeks after discharge showed normal results.

REFERENCES

1. Colice GL, Curtis A, Deslauriers J, et al. Medical and surgical treatment of parapneumonic effusions: an evidence-based guideline. *Chest* 2000; 118(4):1158–1171. pmid:11035692
2. Bryant RE, Salmon CJ. Pleural empyema. *Clin Infect Dis* 1996; 22(5):747–762. pmid:8722927
3. Braman SS, Donat WE. Explosive pleuritis. Manifestation of group A beta-hemolytic streptococcal infection. *Am J Med* 1986; 81(4):723–726. pmid:3532794
4. Sharma JK, Marrie TJ. Explosive pleuritis. *Can J Infect Dis* 2001; 12(2):104–107. pmid:18159325
5. Johnson JL. Pleurisy, fever, and rapidly progressive pleural effusion in a healthy, 29-year-old physician. *Chest* 2001; 119(4):1266–1269. pmid:11296198
6. Jimenez D, Diaz G, Gil D, et al. Etiology and prognostic significance of massive pleural effusions. *Respir Med* 2005; 99(9):1183–1187. doi:10.1016/j.rmed.2005.02.022
7. Light RW, MacGregor MI, Luchsinger PC, Ball WC Jr. Pleural effusions: the diagnostic separation of transudates and exudates. *Ann Intern Med* 1972; 77:507–513. pmid:4642731
8. Rahman NM, Maskell NA, Davies CW, et al. The relationship between chest tube size and clinical outcome in pleural infection. *Chest* 2010; 137(3):536–543. doi:10.1378/chest.09-1044
9. Keeling AN, Leong S, Logan PM, Lee MJ. Empyema and effusion: outcome of image-guided small-bore catheter drainage. *Cardiovasc Intervent Radiol* 2008; 31(1):135–141. doi:10.1007/s00270-007-9197-0
10. Maskell NA, Davies CW, Nunn AJ, et al. UK controlled trial of intrapleural streptokinase for pleural infection. *N Engl J Med* 2005; 352(9):865–874. doi:10.1056/NEJMoa042473
11. Rahman NM, Maskell NA, West A, et al. Intrapleural use of tissue plasminogen activator and DNase in pleural infection. *N Engl J Med* 2011; 365(6):518–526. doi:10.1056/NEJMoa1012740
12. Piccolo F, Pitman N, Bhatnagar R, et al. Intrapleural tissue plasminogen activator and deoxyribonuclease for pleural infection. An effective and safe alternative to surgery. *Ann Am Thorac Soc* 2014; 11(9):1419–1425. doi:10.1513/AnnalsATS.201407-329OC
13. Khemasuwan D, Sorensen J, Griffin DC. Predictive variables for failure in administration of intrapleural tissue plasminogen activator/deoxyribonuclease in patients with complicated parapneumonic effusions/empyema. *Chest* 2018; 154(3):550–556. doi:10.1016/j.chest.2018.01.037
14. Abu-Daff S, Maziak DE, Alshehab D, et al. Intrapleural fibrinolytic therapy (IPFT) in loculated pleural effusions—analysis of predictors for failure of therapy and bleeding: a cohort study. *BMJ Open* 2013; 3(2):e001887. doi:10.1136/bmjopen-2012-001887
15. Bishwakarma R, Shah S, Frank L, Zhang W, Sharma G, Nishi SP. Mixing it up: coadministration of tPA/DNase in complicated parapneumonic pleural effusions and empyema. *J Bronchology Interv Pulmonol* 2017; 24(1):40–47. doi:10.1097/LBR.0000000000000334
16. Redden MD, Chin TY, van Driel ML. Surgical versus non-surgical management for pleural empyema. *Cochrane Database Syst Rev* 2017; 3:CD010651. doi:10.1002/14651858.CD010651.pub2
17. Feller-Kopman D, Light R. Pleural disease. *N Engl J Med* 2018; 378(8):740–751. doi:10.1056/NEJMra1403503

ADDRESS: Samar Farha, MD, Respiratory and Critical Care Institute, Cleveland Clinic Abu Dhabi, Abu Dhabi, UAE; farhas@clevelandclinicabudhabi.ae