

Procedures in Family Practice

Lumbar Puncture in Infants and Young Children

Louis W. Menachof, MD
Santa Rosa, California

Lumbar puncture is an important diagnostic procedure in infants and young children, particularly to rule out acute meningitis. Special problems are presented to the physician with respect to technique and interpretation in this age group. This paper discusses lumbar puncture in infants and young children with attention given to certain procedural details (including the use of the Butterfly Infusion Set) and to significant differences in interpretation of findings in the cerebrospinal fluid in the newborn.

Lumbar puncture, particularly in a newborn or young infant, is a difficult procedure and may result in no spinal fluid being obtained or spinal fluid which is difficult to interpret because of the presence of blood. There are several reasons for this difficulty.

1. Infants may not lie quietly, and movement during the procedure may produce bleeding. This is particularly disturbing when the initial fluid is clear and then becomes bloody during the procedure.

2. If a regular spinal needle is utilized, the dead space (volume of fluid from the needle tip to the hub) is relatively large, so that the needle may be advanced through the subarachnoid space before cerebrospinal fluid (CSF) is seen at the hub end of the needle.

3. Many physicians prefer to use a small size spinal needle. Therefore, the time required to fill the dead space with CSF is long enough to increase the risk of passing through the subarachnoid space before CSF is visualized.

Because of the difficulties encountered in obtaining clear spinal fluid, strict attention to small details of technique and equipment often determines success or failure of lumbar puncture. This article will present the indications, technique and interpretation of results of lumbar puncture in infants and young children.

Indications

Although examination of spinal fluid is indicated in a wide variety of clinical situations, the principal indication for the primary care physician dealing with children and infants is to rule out the presence of acute meningitis. In children, the history and physical examination may suggest this diagnosis by the presence of high fever, irritability, vomiting, lethargy, convulsion, full fontanelle (if patent), and signs of meningeal irritation. In marked contrast, meningitis in newborns or young infants frequently fails to display the classic findings associated with this disease. Frequently the onset is insidious with the symptoms and signs of a nonspecific character, including poor tone, poor cry, inactivity, loss of interest in feedings, and vomiting. More specific findings of apnea, convulsions, and vascular collapse associated with hyperthermia or

hypothermia may be very late in occurrence and incompatible with a favorable outcome.

For these reasons, it is imperative that an early diagnosis be made and prompt treatment instituted. In order to do this, the physician must be alert to the possibility of this diagnosis with any very sick child, particularly the neonate or young infant. It is with this admonition that we perform a lumbar puncture "whenever the possibility of this disease is considered." While some experienced, primary care physicians may consider this diagnosis and decide against lumbar puncture, the inexperienced physician should not be so inclined, and should not be discouraged by the performance of multiple lumbar punctures with normal results. When carefully done, the potential for valuable information far outweighs the risks of the procedure. Lumbar puncture is contraindicated only in patients with increased intracranial pressure caused by a space-occupying lesion and in the presence of an untreated clotting defect.

Technique

The use of Butterfly-21 Infusion Set (Abbott Laboratories), as described by Greensher,¹ significantly increases the success of lumbar puncture in young infants. This piece of equipment, regularly used for intravenous therapy in children, is composed of a thin-walled needle (20-gauge bore) with a 3.5 cm shaft, a center plastic grip for holding, a 30 cm plastic tube in which spinal fluid can be seen, and a standard hub. It has been my experience that the needle is long enough to reach the subarachnoid space in almost all infants of less than four months of age. The dead space with this needle approximates 0.02 ml, so that spinal fluid is seen in the plastic tube quickly upon entering the subarachnoid space, making it much less likely that the needle will be advanced through the subarachnoid space. Once this space has been entered, the operating hands are immediately removed from the needle and support is given to the plastic tube and hub. In this manner, the light needle is allowed to move freely with any movement in the patient. Thus, bleeding from penetration of veins by needle movement is less likely than with a

From the Community Hospital, Santa Rosa, California. Dr. Menachof is Assistant Clinical Professor, Ambulatory and Community Medicine and Pediatrics, University of California, San Francisco. Requests for reprints should be addressed to Dr. Louis W. Menachof, Community Hospital, 3325 Chanate Road, Santa Rosa, Calif 95402.

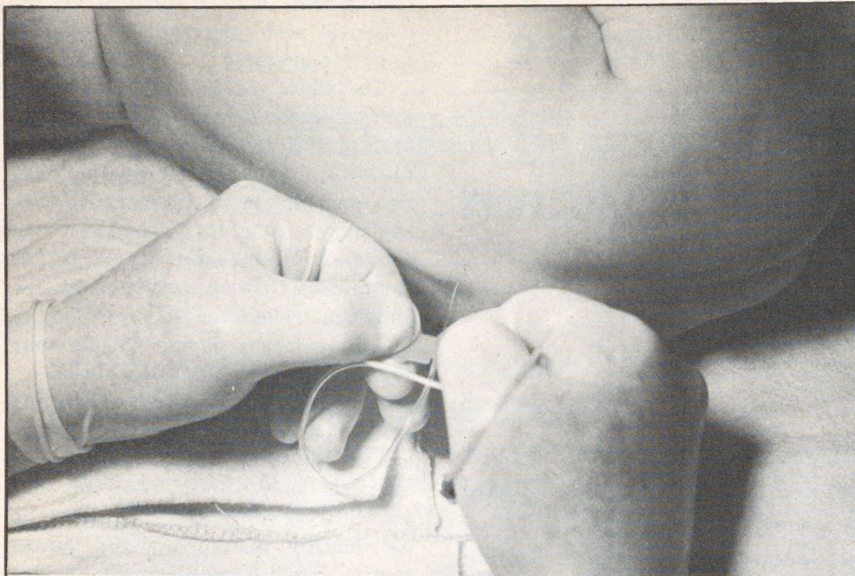


Figure 1. Lumbar puncture in the lying position. Note the plastic grip in the horizontal position so that the needle bevel is turned upwards.

relatively immobile standard spinal needle. In addition, the relatively large gauge needle insures rapid flow and prompt appearance of the CSF in the plastic tube. Although accurate manometric studies are normally difficult to obtain, they are somewhat easier to measure by this technique by simply raising the plastic tube and measuring the fluid level with a ruler. This could be done more simply if the plastic tube were calibrated.

Although this technique has proven to be more successful than any other by our house staff, strong objection has been raised because of the relationship between lumbar punctures utilizing needles without stylets and later development of epidermoid spinal cord tumors.² It seems probable that with the use of such a needle (without stylet) a plug of epidermis may be directly implanted into the subarachnoid space, showing up years later as an epidermoid tumor.

In order to avoid this, we have elected to puncture the skin with the point of a size 11 blade. Following penetration of the skin with the blade point, pressure is applied for approximately 30 seconds to stop any fresh

bleeding. The butterfly needle is then introduced through the skin opening as demonstrated in Figures 1 and 2. For infants over four months of age, a special spinal needle designed for children (1.5 inch, 22 gauge with clear hub) should be used.

Proper position of the patient and good maintenance in this position is of utmost importance. The procedure is difficult enough without attempting to introduce the needle into a moving target. This is especially applicable to an older infant or young child who is difficult to restrain. Frequently, but not necessarily, children who do have meningitis are too ill to effectively resist the procedure. Although it is often effective to explain and reason with an older child, this is rarely successful with an infant or toddler. It is my opinion that the kindest approach is to firmly and effectively restrain the patient (Figure 3), use local anesthetic infiltration, and "get in and out quickly." Trying to reason with a frightened and frantic child is useless and only prolongs the agony. The firm, but kind, restraint may be reassuring to the child, particularly if the parent has also reassured the child

with kind firmness, since this approach avoids the "mixed message" which so often leads to further fear and fighting by the child. During restraint, attention must be given to insure adequate airway exchange. In a young infant, the sitting position allows for easier entrance between the vertebral spaces, since flexion of the back is easier to obtain and maintain in this position (Figure 2).

The puncture should not be done through an area of infected skin. Careful cleansing of the skin is essential, but drapes are unnecessary. Introduction of the needle should be made at a point just above the intercrestal line, which will usually correspond with L3-4 interspace. The needle should not be introduced above the L2-3 interspace, because the spinal cord of the infant assumes a lower position in relation to the vertebral column. A common cause of failure is a low entrance of the needle. With the patient in the sitting position, the bevel of the needle should be turned to either side so that during introduction of the needle the dural connective tissue strands and veins are separated rather than cut (Figure 2). Similarly, if the procedure is done with the patient in a lying position, the bevel should be turned up (Figure 1). The needle is advanced so that the tip is pointed slightly cephalad with care given to remaining in the midline. The characteristic "pop," usually felt upon going through the dura, is often not realized in a young infant, so that close visual attention for spinal fluid in the plastic tube must be maintained.

Interpretation of CSF

Spinal fluid obtained from a child and infant is comparable to that of an adult. However, in newborns, there are significant differences.

Appearance

Xanthochromia, a yellow color, always abnormal past the newborn period, is normally present in the newborn, due either to elevation of the protein level, or to the presence of bilirubin.

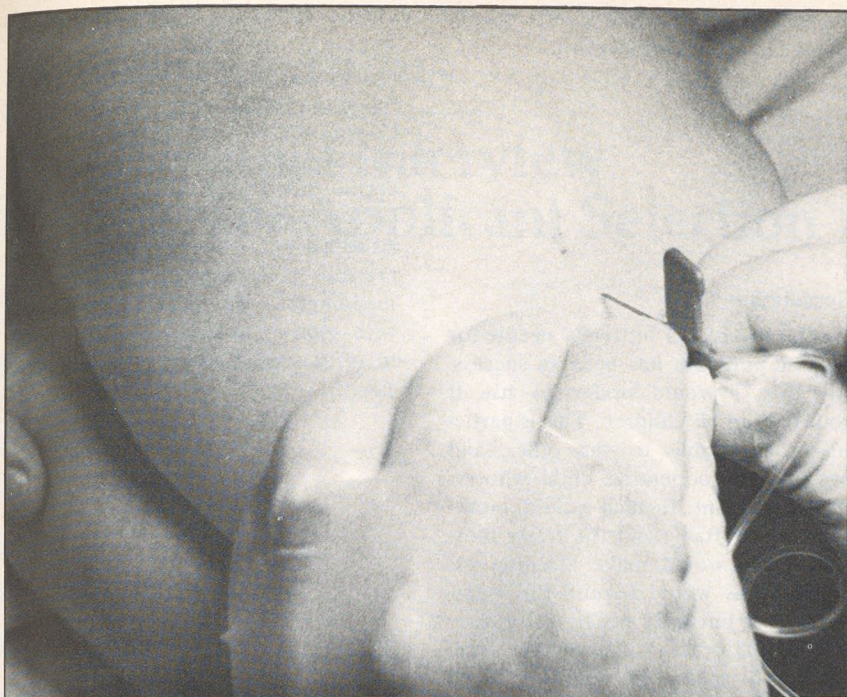


Figure 2. Lumbar puncture in the sitting position. Note the plastic grip in the vertical position so that the needle bevel is turned to either side.

Red Blood Cells

Up to approximately 500 red blood cells per ml is accepted as normal in newborns. It is rare in neonates to obtain spinal fluid without red blood cells, even when the procedure has been considered atraumatic. It is often difficult to evaluate the significance of larger numbers of red blood cells, particularly in an ill newborn where disseminated intravascular coagulation or intracranial hemorrhage is a possibility. In spite of attempts to differentiate fresh red blood cells, due to the procedure, from those originating from a true bleed by centrifugation and examination of the supernatant, and by red blood cell morphology such as crenation, the differentiation may have to be made on clinical grounds alone.

White Blood Cells

In contrast to older children and adults where up to five white blood cells per ml is considered normal, newborn spinal fluid may contain up to 20 white blood cells per ml including a significant portion as polymorphonuclear leukocytes. In the presence of bloody spinal fluid, increased numbers of white blood cells will be seen, but the count should be elevated only in the same RBC:WBC ratio seen in newborn blood (250-500:1).

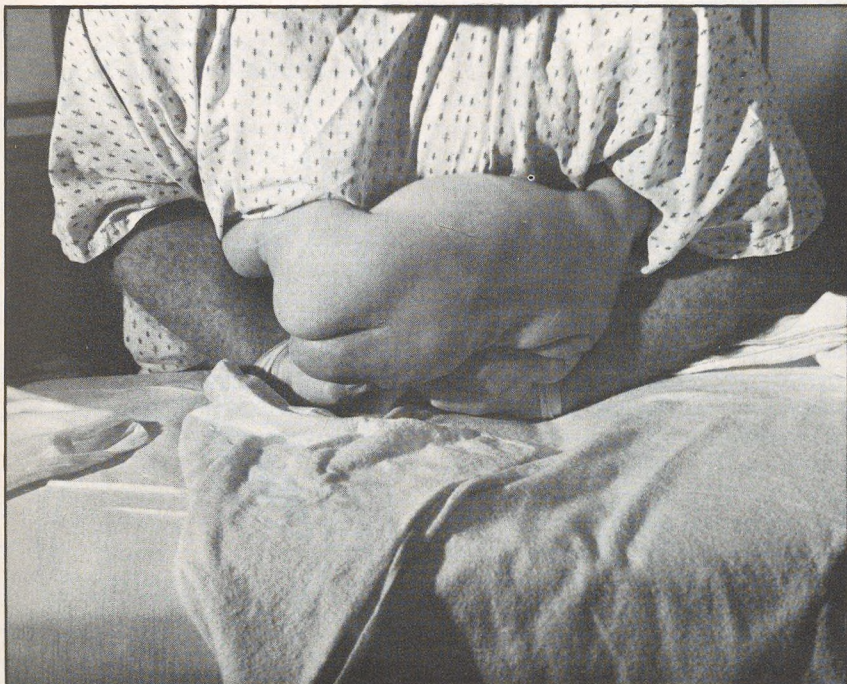

Figure 3. Technique for holding a struggling child.

Protein

In the neonatal period, protein content may be normal up to 120 mg/dl, but it should be less than 45 mg/dl by three months of age.

Glucose

CSF glucose level should be approximately one half to two thirds of the simultaneously drawn serum glucose concentration. The absolute value of CSF glucose is difficult to evaluate, particularly in the neonate whose serum glucose (and subsequent CSF glucose) concentrations may normally be low in relation to adult standards.

Bacteriology

Spinal fluid should always be examined directly by Gram's stain and cultured, both aerobically and anaerobically. This is true even when the spinal fluid is crystal clear without cells. Early meningitis may present with organisms and growth in the absence of elevated white blood count. Special cultures for fungi, tuberculosis, and viruses are done only as indicated.

Pressure Measurements

Pressure measurements are accurate only when the patient is relaxed. Relaxation is rarely obtained in struggling children, but can be accomplished in non-struggling, very ill patients, and in neonates. Normal pressures vary from 5 to 16 cm H₂O in the

recumbent position and approximately double in the sitting position.

Speculation

The use of the butterfly needle for lumbar puncture has been so successful that I would prefer to use it routinely in all children. This is particularly applicable to the older, and stronger, uncooperative child who requires restraint. In such a child, movement is inevitable and the freely moving needle would make bleeding less likely. This would require the manufacture of butterfly needles of greater length in order to reach the subarachnoid space. In addition, these suggested spinal needles could be shortened by reducing the plastic tube length from 30 cm to 2 cm so that a stylet could be incorporated, thus ob-

viating the need for penetrating the skin with the blade. Once the needle has been inserted through the skin into the ligamentous area, the stylet could be removed and the needle inserted in the manner described. The smaller plastic tube length will allow for comparable needle mobility and prompt visualization of the CSF; it will require pressure measurement by a separate manometer. We have experimented with such a prototype and it appears to offer similar advantages with equal ease.

References

1. Greensher J, Mofenson HC, Borofsky LG, et al: Lumbar puncture in the neonate: A simplified technique. *J Pediatr* 78:1034-1035, 1971
2. Shaywitz BA: Epidermoid spinal cord tumors and previous lumbar punctures. *J Pediatr* 80:638-640, 1972

