

---

# Problems in Family Practice

---

## Hand Ischemia

Bhagwan Satiani, MB, and David T. Sowden, MD  
Columbus, Ohio

Hand ischemia is an uncommon, but potentially catastrophic, clinical entity. The large number of etiologic factors and lack of universal agreement regarding treatment have created a confusing clinical situation. Diagnosis is most frequently made by a detailed history and physical examination. Both invasive and noninvasive tests are employed for diagnosis and in planning treatment. Growing experience and improved surgical techniques have enabled vascular surgeons to deal more effectively with the ischemic hand.

Ischemic arterial lesions of the hand are less frequent in comparison to the lower extremity. Consequently, the diagnosis is not considered, and the treatment is often inappropriate. The specialized functions of the hand do not require prolonged muscular activity; therefore, ischemic claudication is an uncommon symptom in contrast to the leg. When symptoms do occur in the form of constant pain or tissue necrosis, the consequences are devastating. Loss of fingers is more critical than loss of toes in terms of self-image, the ability to perform daily routines, and maintaining a job. Because the etiologic factors are diverse, an organized approach to the patient with hand ischemia is necessary.

It is the purpose of this paper to briefly review the etiologic factors, clinical features, noninvasive and invasive diagnostic methods, and principles of treatment in patients with hand ischemia.

### Etiology

Since Maurice Raynaud described digital gangrene in 1862,<sup>1</sup> the etiology of hand ischemia has remained a source of controversy. In 1893 Hutchi-

son<sup>2</sup> pointed out that many patients with arterial spasm had an underlying disease process and suggested that the term "Raynaud's phenomenon" be applied to this constellation of signs and symptoms. Although the idea of arteriolar spasm continues to appear in the literature to this day, it is now generally accepted that digital ischemia is not due to vasospasm alone. Some of the more frequent causes of hand and digital ischemia are summarized in Table 1.

### *Raynaud's Phenomenon and Raynaud's Disease*

Raynaud's phenomenon typically consists of digital color changes most frequently noted upon exposure to cold. Pallor of the digits or the entire hand is first observed. This progresses to cyanosis and finally to rubor. Paresthesia, numbness, and tingling may also be described. Local fingertip ulceration and fingernail infection may become a problem later, even though major amputation is rare. It is important to differentiate Raynaud's phenomenon, which implies intermittent color changes with no underlying systemic disorder, from Raynaud's disease, which is also referred to as secondary Raynaud's phenomenon. Raynaud's disease may be associated with a wide variety of disorders, including trauma, collagen vascular disease, neurogenic causes, and arterial occlusive

---

From the Department of Surgery, Grant Hospital, and the Department of Surgery, Ohio State University College of Medicine, Columbus, Ohio. Requests for reprints should be addressed to Dr. Bhagwan Satiani, 300 East Town Street, Suite 613, Columbus, OH 43215.



**Table 1. Etiology of Severe Hand Ischemia**

Degenerative Arterial Disease	Proximal atherosclerosis, digital atherosclerosis
Systemic Disorders	Scleroderma, thromboangiitis (Buerger's disease), uremic arteritis, lupus erythematosus, dermatomyositis, hypersensitivity arteritis, periarteritis nodosa
Trauma	Hypothenar hammer syndrome, ulnar artery aneurysm, drug injection, vascular interruption, traumatic arteriovenous fistula
Iatrogenic	Arterial puncture (diagnostic or therapeutic), drug toxicity (necrotizing arteritis), arteriovenous fistula for vascular access
Miscellaneous	Emboli, frostbite, cryoglobulinemia, monoclonal gammopathy, malignancy, thoracic outlet syndrome, phlegmasia cerulea dolens

disease. Spittell<sup>3</sup> states that if certain criteria are adhered to, the diagnosis of Raynaud's disease is excluded in over 95 percent of instances. These criteria include Raynaud's phenomena elicited by cold or emotional stimulus, bilaterality, minimal or no gangrene, absence of other underlying diseases, and symptoms for at least two years. Certainly, such autoimmune disorders as scleroderma, lupus erythematosus, periarteritis nodosa, dermatomyositis, and other collagen vascular diseases can occur in association with Raynaud's phenomenon. Porter and colleagues<sup>4</sup> have pointed out the importance of following such patients for the development of systemic disorders, often years after the onset of symptoms of Raynaud's phenomenon.

#### *Arteriosclerosis Obliterans*

Arteriosclerosis obliterans with or without Raynaud's phenomenon is relatively uncommon in the hand. Laws and colleagues<sup>5</sup> have clearly demonstrated that arteriosclerotic disease involving the small digital vessels is distinctly rare in patients under the age of 50 years. The implication is that in the younger patient, other causes must be seriously considered. Involvement of the male sex and

evidence of associated arteriosclerosis clearly differentiate this from other causes of hand ischemia.

#### *Thromboangiitis Obliterans (Buerger's Disease)*

Thromboangiitis obliterans (TAO) is a disease of young, male smokers with an incidence said to be about 8 per 100,000 people. Although tobacco may not be a primary causative factor, it certainly adversely affects the progress of the disease. The cause is unclear, but Gulati et al<sup>6</sup> have raised the possibility of an autoimmune process. Whereas arteriosclerosis frequently involves the more proximal large vessels, TAO does not usually do so. The disease is usually unilateral to start with and may or may not be associated with recurrent superficial venous thrombosis. Typically, the disease is one of acute exacerbations and remissions. The attacks in the upper extremity may commence as excruciatingly painful vesicles on the pulp of a digit with local hyperemia. This may progress to a small, punched-out ulcer, which may subsequently become infected and lead to gangrene. If the acute episode subsides, a small pitlike depression or, more commonly, pulp atrophy remains as



the aftermath. The diagnosis is certainly to be suspected in the absence of diabetes mellitus, hyperlipidemia, collagen vascular disease, or evidence of generalized arteriosclerosis.

### *Arteritis*

Takayasu's arteritis, or pulseless disease, is a nonspecific panarteritis involving the larger elastic arteries in young women usually under the age of 40 years. It occurs especially in the Orient, and the etiology is undetermined. An autoimmune basis has been suspected, although it has not been proven. A positive lupus erythematosus cell preparation and antinuclear antibodies have been reported with this form of arteritis. The majority of patients have constitutional symptoms, such as anorexia, malaise, multiple aches and pains, night sweats, and fever. Progressive involvement of the major arteries to the upper extremities can occur with the appearance of disabling arm claudication and hand ischemia. This may or may not be associated with cerebrovascular, mesenteric, or coronary artery insufficiency. Hand ischemia with absent or decreased blood pressure in the affected extremity, along with the systemic manifestations, can clinch the diagnosis.

### *Traumatic Disorders*

Upper extremity trauma in various forms may result in vascular interruption and ischemia of the hand and digits. Typical Raynaud's phenomena can occur with any occupation involving repeated trauma to or near major arteries of the upper extremity. The classical presentation is that of a manual laborer who has been working with pneumatic drilling tools in the rock-drilling or the chain-saw business. This type of work apparently elicits a vasomotor response in the digital vessels. Because the drilling tools are often gripped in the medial aspect of the hand, the third, fourth, and fifth digits are more commonly involved. Another form of injury is repetitive blunt trauma to the hypothenar area, which may cause degeneration of the ulnar artery with aneurysm formation or thrombosis of the ulnar artery (hypothenar hammer syndrome). These patients may have Raynaud's phenomenon brought on by exposure to cold weather and may develop painful ulcers on their fingertips.

### **Intra-arterial Drug Injection**

The problem of intra-arterial drug injection, once rarely seen and then only because of accidental barbiturate injection by anesthesia personnel, has now become a common problem in drug abusers. The injection may either be deliberately intra-arterial or resorted to when all superficial veins have been exhausted and accidental intra-arterial injection occurs in an attempt to inject a deeper vein. Drugs that have been injected include chlorpromazine, propoxyphene hydrochloride, hydroxyzine hydrochloride, pentazocine hydrochloride, and ergot. The pathogenesis is not clear but may be a result of severe vasospasm with resulting arterial obstruction.

The femoral triangle and antecubital fossa are the usual locations for injections. Severe pain occurs instantly, along with blanching, cyanosis, swelling, and occasionally gangrene.

### **Iatrogenic**

Iatrogenic causes of hand ischemia are most frequently related to arterial puncture for blood gas analysis, cardiac catheterization, and other invasive diagnostic or therapeutic procedures. Ischemic sequelae may be expected in 0.2 to 0.5 percent of patients who have radial artery catheterization. When the superficial palmar arch is anatomically complete, the ulnar artery is the major source of blood flow.<sup>7</sup> However, 1.6 percent of patients have an incomplete palmar arch and are therefore subject to ischemic finger necrosis after radial artery puncture and thrombosis.<sup>7</sup> In a recent study of 839 radial artery punctures in 282 patients by Gillies et al,<sup>8</sup> the safety of the smaller gauge needles was confirmed with no cases of arterial occlusion. Brachial artery thrombosis results in fairly acute hand ischemia, the severity depending upon the adequacy of collateral circulation. The hand may be extremely painful and numb, with sensory and motor changes occurring in advanced arterial ischemia. The hand is pale and cadaveric in severe ischemia. If there is adequate collateral circulation, the color gradually returns and may appear only slightly cyanotic. In time, some patients will develop a palpable weak radial or ulnar pulse some time after the acute event. In radial artery thrombosis, depending upon the adequacy of the palmar arch, the radial side of the hand in-



cluding the thumb and the index finger may appear pale and have diminished sensation. Bedford and Ashford<sup>9</sup> studied 100 patients with 105 radial artery cannulations and detected a 38 percent incidence of thrombosis. On follow-up, most vessels recanalized, and no major ischemic complications occurred. In contrast, Baker and colleagues<sup>10</sup> reported five patients seen over a 20-month period who developed severe ischemia of the hand following indwelling radial artery catheters, with loss of all or part of one or more digits.

### Arterial Emboli

Peripheral arterial embolism is being more frequently seen as a result of a more aging population and advanced arteriosclerosis. The source of the arterial embolus is most frequently cardiac in origin. Chronic atrial fibrillation associated with arteriosclerosis or rheumatic disease is the most common cause, followed by acute myocardial infarction. James and colleagues<sup>11</sup> reviewed 36 patients with upper extremity thromboembolism, constituting 15 percent of all patients with arterial thromboembolism. A cardiac origin was suspected in 88 percent of cases, and arteriosclerotic heart disease was documented in 80 percent of these patients. The brachial artery was the most common location of the arterial embolus. Bacterial endocarditis, prosthetic heart valves, atheroemboli, atrial myxoma, and paradoxical emboli are other causes of arterial emboli of the upper extremity causing hand ischemia. Sudden onset of pain, numbness, coolness, and occasional sensory or motor disturbances in the upper limb are the presenting features. The typical physical signs of acute arterial ischemia are present, which include absent or weak distal pulses, coolness, pallor, and motor or sensory deficits.

### Thoracic Outlet Syndrome

Although neurologic symptoms are the hallmark of thoracic outlet compression syndrome, 5 to 15 percent of patients will have hand or arm ischemia as the presenting complaint. This may occur from bony abnormalities such as a cervical rib or because of compression of the subclavian or axillary artery at the thoracic outlet. Mural thrombus develops intraluminally in the poststenotic aneurysmal segment beyond the site of compression of the artery. Thrombus has great potential for embolization, and the typical presentation is that

of digital or cutaneous microemboli. Ten to 15 percent of these patients also present with intermittent Raynaud's phenomenon. The importance of making the diagnosis early is that repeated digital microembolization will eventually lead to limb loss unless the proximal source is removed early.

### Miscellaneous Disorders

There are numerous miscellaneous causes of hand ischemia. Several malignancies have been associated with severe hand ischemia. The pathogenesis is not well understood, but tumor antigen and antibodies may form immune complexes and induce peripheral arteritis. An alternative theory implicates thrombogenic changes present in malignancy as the cause. Cryoglobulinemia in an essential form or in association with multiple myeloma, macroglobulinemia, chronic infection, or connective tissue disease has been linked with digital ischemia. Frostbite may produce intense vasospasm, sludging, and eventual thrombosis with loss of digits. Uremic calcific arteritis can also present with digital ischemia.

### Diagnosis

The clinical presentation of hand ischemia is unlike lower extremity ischemia. Hand ischemia is not only a less common clinical problem but, also, it seldom presents as claudication for obvious reasons. The fine movements of the hand seldom require prolonged activity, and secondly, arterial lesions of the wrist and hand are distal to the major muscle groups of the arm and forearm. When ischemic hand lesions occur in conjunction with more proximal arterial lesions, such as subclavian, axillobrachial artery obstruction, arm claudication may occur. This is similar to lower extremity claudication in that "aching" or a "tired feeling" is brought on by exercise, is relieved by rest, and is reproducible.

The history and physical examination are extremely valuable in assessing hand ischemia. A detailed history, including recent or remote trauma, the occupational history, a recent episode of radial artery cannulation, history of drug abuse, or systemic symptoms of collagen vascular disease, provides a basis for proceeding with diagnostic tests.

Examination of the upper extremity should start with inspection of the entire vascular system in-



cluding distant anatomic areas. Evidence of pallor, cyanosis, or ulceration is noted. Examination of the supraclavicular area should be performed to determine the presence of a mass, which is usually either the end of a cervical rib or a poststenotic dilated subclavian artery that may be palpable as a pulsatile mass. Subclavian, axillary, brachial, radial, and ulnar arteries should be palpated or checked with an ultrasonic Doppler. Allen's test is also useful in checking the patency of the palmar arch. Many variations of this exist, all directed toward determining the adequacy of ulnar artery perfusion of the hand. The authors prefer occluding both radial and ulnar arteries at the wrist and having the patient exercise the hand. Release of pressure over the ulnar artery with return of color to the palm within four to five seconds indicates an adequate palmar arch. Examination of the hand and fingertips should be carried out with particular attention to fingertip necrosis and nonhealing traumatic lesions of the fingers, which may be the first and only symptoms of rather advanced hand ischemia. Stretching of the skin is obvious in patients with scleroderma. Comparative capillary refilling time is also useful in estimating more distal occlusion. Following this, various maneuvers are carried out to determine the presence or absence of thoracic outlet syndrome. Hyperabduction and external rotation of the extremity at the shoulder is performed to try and reproduce the patient's arterial symptoms. At the same time auscultation over the supraclavicular fossa for bruits should be routine. This can be done with the arms at rest and also with hyperabduction. The disappearance of the radial pulse with the hyperabduction maneuver can and does occur even with normal people and does not by itself indicate arterial compression as the cause of the patient's symptoms.

Hematologic and immunologic workup for obvious or occult hand ischemia should include a complete blood count, SMA chemical screen, erythrocyte sedimentation rate, serum protein and immunoglobulin electrophoresis, complement C3 and C4, cold agglutinins, antinuclear antibodies, rheumatoid factor, VDRL, direct Coombs' test, lupus erythematosus cell preparation, and cryoglobulins. A chest x-ray examination and films of the cervical spine are useful in ruling out bony abnormalities of the upper thorax and neck. Radiologic evaluation of the urinary tract and upper and lower gastrointestinal tracts may be necessary in

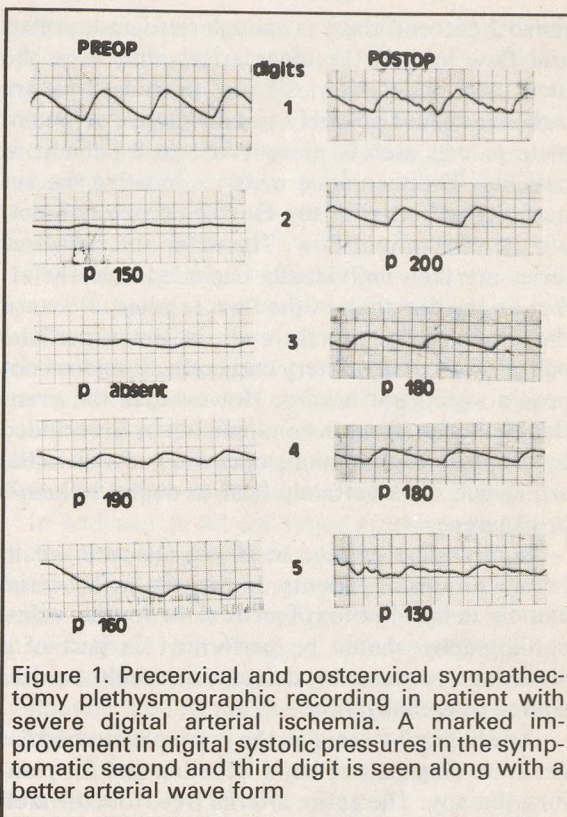


Figure 1. Precervical and postcervical sympathectomy plethysmographic recording in patient with severe digital arterial ischemia. A marked improvement in digital systolic pressures in the symptomatic second and third digit is seen along with a better arterial wave form

patients with suspected collagen vascular disease.

Noninvasive evaluation of the arterial system has come to the forefront in recent years. The percutaneous Doppler ultrasonic flowmeter is a valuable tool used to detect large vessel occlusive disease or assess palmar collateral circulation. Systolic pressures obtained with the Doppler at the brachial and the wrist level can help to quantitate large vessel disease using the opposite extremity and the lower limbs for comparison. Digital systolic pressures can also be measured, with the small cuffs and the wrist-to-digit gradients identified to localize the level of obstruction. Additional objective methods available include measuring the digital blood flow with digital plethysmography and pulse volume recordings. These are also of practical use to confirm the presence of organic lesions and document the response to treatment (Figure 1). The status of the palmar arch as determined by the Doppler is often useful prior to radial catheterization. The superficial palmar arch has as its major blood supply the ulnar artery in 80 to 90 percent of patients. In an addi-



tional 2 percent, there is enough retrograde collateral flow around the ulnar artery that were the ulnar and radial arteries to be occluded, severe ischemia would probably not develop. An incomplete palmar arch is present in 1 to 2 percent of patients. The technique involves locating the superficial palmar with the Doppler probe and noting the direction of flow. The ulnar and radial arteries are then individually occluded, and the effect on the direction of the flow is noted. Because the ulnar artery usually ends in the superficial palmar arch, radial artery catheterization does not pose a significant hazard. However, in the event that the ulnar artery is nondominant or is occluded by Doppler examination, occlusion of the radial artery can most certainly lead to digital ischemia or gangrene.

Noninvasive cardiac tests are also utilized in certain groups of patients. In patients with arterial emboli, in the absence of an obvious source, echocardiography should be performed as part of a screening process to detect an occult cardiac source of embolization.

Arteriography remains the principle method for accurate diagnosis of hand ischemia and for planning therapy. The entire arterial tree from the arch to the digital vessels can be visualized with transfemoral catheterization under local anesthesia. Percutaneous brachial cannulation can provide excellent visualization of the digital vessels in situations in which the proximal vessels are suspected to be normal.

Muscle biopsy in patients with cholesterol embolization may show small vessels occluded by cholesterol material. Skin and arterial biopsy is performed occasionally in suspected dermatomyositis. Histologic features of veins and arteries in TAO consist of nonspecific, cellular infiltration of the thrombotic material, well-preserved media with cellular infiltration, and a fibroblastic adventitial coat.

## Treatment

Nonoperative measures in the treatment of small vessel disease of the arm or hand include cessation of nicotine in any form and inculcating an obsession to protect the involved extremity from any form of injury. Often, cessation of tobacco and avoidance of cold is all that is necessary in younger patients with Raynaud's phenomena. Prevention of thermal damage to the digits in-

volves the use of heavy, warm gloves in even moderately cold weather, prevention of even minor trauma to the fingers, and a change in occupation if necessary, to avoid repetitive minor trauma to the digits. The role of orally administered vasodilators is limited, as they are invariably ineffective. Oral reserpine and guanethidine have been used in Raynaud's disease with mixed results. Oral anticoagulation (Coumadin) can be used in patients with small vessel thrombosis and in the absence of significant contraindications. This usually follows intravenous heparin administration. The prothrombin time is maintained at 2 to 2.5 times the control value. Intra-arterial brachial injection of reserpine (0.5 to 1.0 mg) in some cases will provide adequate relief, although the effect may be temporary. It may be particularly useful in the treatment of infected and nonhealing digital ulcers. Application of external heat will not change body core temperature and may be harmful to the ischemia tissue by increasing the metabolic rate. Frostbitten hands or fingers are treated with rapid rewarming and not direct cutaneous application of heat.

Other drugs used in hand ischemia include methyldopa, prazosin, griseofulvin, tolazoline (Priscoline), and estrogens. Preliminary reports indicate that oral administration of such drugs as guanethidine and phenoxybenzamine may be of some benefit, although controlled clinical trials are necessary. Stellate ganglion block can be performed percutaneously under local anesthesia through an anterior cervical approach to provide temporary relief as well as to predict success of subsequent surgical sympathectomy. Relief of symptoms in the absence of blockade of the adjacent brachial plexus portends relief following sympathetic nerve section. A technically successful block is indicated by the appearance of a Horner's syndrome.

In most patients with TAO, acute episodes are brought on by heavy and continuous smoking. Other risk factors include exposure to cold and fungal infections, which are important in the prevention of acute exacerbation. Once an acute episode has occurred, withdrawal of cigarettes is mandatory. If total withdrawal of cigarettes is impossible, reduction in the number of cigarettes is desirable, as the prognosis is somewhat better. Patients with a family history of TAO should also be advised to cease smoking. Local care of the



fingertips consist of antiseptic dressings, bacterial and fungal cultures, and treatment with appropriate antibiotics. Antifungal powders are applied for treatment of local fungal infections. Analgesics are administered as necessary. Vasodilators, anticoagulants, and steroids have all been tried with varying success.<sup>12</sup> The role of cervical sympathectomy is controversial. Minor amputation of digits can often be successful if spontaneous sloughing of dead tissue does not occur. If gangrene extends proximally or there is persistent rest pain, a below-elbow amputation is advisable.

Anticoagulation with continuous intravenous heparin may be used for primary treatment for small vessel thrombosis, to prepare for surgical treatment, and as treatment following procedures such as arterial embolectomy. Long-term anticoagulants are chosen for reliable patients with arterial emboli secondary to atrial fibrillation for whom a high likelihood of occurrence exists. This will not prevent recurrent emboli in all patients, and certainly the substantial hazards of anticoagulation have to be weighed against the possible benefits. The role of thrombolytic therapy in peripheral arterial occlusion has not been clearly defined.

### Surgical Treatment

Surgical intervention is often necessary to salvage the hand. Direct reconstruction is preferred where large arteries are occluded. Although arterial symptoms secondary to thoracic outlet syndrome are uncommon, they are totally corrected by first rib resection early in the natural history of the disease. Poststenotic aneurysmal dilation in the subclavian or axillary artery with intraluminal thrombus formation and eventual distal embolization is another correctable cause of hand ischemia. Emboli originating from the heart can obstruct the upper extremity arteries, causing severe hand ischemia. The brachial artery bifurcation is the usual site. The surgical procedure of embolectomy involves transversely opening the brachial artery under local anesthesia and extracting the embolus with a Fogarty balloon catheter. With numerous transbrachial cardiac catheterizations being performed, iatrogenic intimal damage and thrombosis occur frequently. Endarterectomy and arterioplasty with autogenous vein patch under local or general anesthesia restore arterial circulation to the hand. Serial Doppler ultrasound examination is helpful in separating severely ischemic limbs re-

quiring vascular reconstruction from those with adequate collateral circulation for which arterial exploration may not be necessary. Extensive trauma to the forearm with fractured long bones and coexisting arterial injury often requires urgent restoration of blood flow using standard vascular techniques and the preferential use of autogenous tissue when available.

Treatment of hand ischemia secondary to intra-arterial drug injection consists of elevation of the limb, anticoagulants or dextran to limit small vessel thrombosis, analgesics, and occasionally intra-arterial reserpine for relief of arterial spasm. Fasciotomy should be utilized early to prevent ischemic muscle contracture or dysfunction. Minor digital or major amputation is often necessary.

In addition to all the other measures outlined above, corticosteroids have been known to produce clinical remission in some patients with arteritis. Surgical intervention is limited to the chronic phase of the disease, when prosthetic bypasses to the undiseased large arteries may relieve symptoms. Deaths are due to cerebral and cardiac complications.

### References

1. Raynaud M: De l'asphyxie locale et de la gangrene symetrique de extremités, Paris, 1862. In: Rignoux: Selected Monographs, Barlow T (trans). London, The New Sydenham Society, 1888
2. Hutchison J: Inherited liability to Raynaud's phenomenon, with great proneness to chilblains—Gradual increase of liability to paroxysmal local asphyxia acrospace-lus with scleroderma checks affected. *Arch Surg* 4:312, 1893
3. Spittell JA: Raynaud's phenomenon and allied vasospastic disorders. In Juergens JL, Spittell JA, Fairburn JF (eds): *Peripheral Vascular Diseases*. Philadelphia, WB Saunders, 1980
4. Porter JM, Bardana EJ, Baur GM, et al: The clinical significance of Raynaud's syndrome. *Surgery* 80:756, 1976
5. Laws JW, El Sallab RA, Scott JT: An arteriographic histologic study of digital arteries. *Br J Radiol* 40:740, 1967
6. Gulati SM, Singh KS, Thusoo TK, Saha K: Immunological studies in thromboangiitis obliterans (Buerger's disease). *J Surg Res* 27:287, 1979
7. Mozersky DJ, Buckley CJ, Hagood CO, et al: Ultrasonic evaluation of the palmar circulation: A useful adjunct to radial artery cannulation. *Am J Surg* 126:810, 1973
8. Gillies IDS, Morgan M, Sykes MK: The nature and incidence of complications of peripheral arterial puncture. *Anesthesia* 34:506, 1979
9. Bedford RF, Ashford TP: Aspirin pretreatment prevents post cannulation radial artery thrombosis. *Anesthesiology* 51:176, 1979
10. Baker RJ, Chunprapaph B, Nyhus LM: Severe ischemia of the hand following radial artery catheterization. *Surgery* 80:449, 1976
11. James EC, Khuri NT, Fedde CW, et al: Upper limb ischemia resulting from thromboembolism. *Am J Surg* 137:739, 1979
12. Hill GL: A rational basis for management of patients with the Buerger syndrome. *Br J Surg* 61:476, 1976