

## Internal Carotid Artery Thrombosis Following Penetrating Trauma of the Soft Palate: An Injury of Youth

George L. Higgins III MD, and John T. Meredith, MD  
Portland, Maine

Internal carotid artery (ICA) thrombosis with resultant neurologic deficit is a well-documented complication of both blunt and penetrating intraoral injuries in children and young adults.<sup>1-14</sup> A number of emergent surgical therapies have proven successful when treating the traumatized ICA,<sup>15-25</sup> and newer methods, such as emergent thrombolysis in acute stroke syndrome, currently are being evaluated.<sup>26-34</sup> The efficacy of therapeutic intervention, however, depends on timely diagnosis, a difficult challenge, as the clues to developing ICA thrombosis can be subtle, and a delay in development is not uncommon.

### Case Report

A 12-year-old boy was involved in a sledding accident, falling onto a tree branch protruding from the snow and sustaining a puncture wound of the right posterolateral aspect of his soft palate. Except for mild localized pain and minimal temporary bleeding, he was not apparently bothered by this injury.

Several hours later he developed transient dizziness and slurring of speech, which resolved completely without requiring medical attention. He was able to sleep and awoke symptom-free the next morning. Later in the day, approximately 24 hours after his accident, he suddenly developed headache, left-sided weakness, and slurring of speech. His condition rapidly deteriorated, leaving him with paralysis of his left side, slurred speech, and intermittent delirium. Transient seizure activity, characterized by clonic posturing of his left arm and leg, was witnessed by the family.

*Submitted, revised, December 11, 1990.*

*From the Department of Emergency Medicine, Maine Medical Center, Portland, Maine, and University of Vermont College of Medicine, Burlington, Vermont. Requests for reprints should be addressed to George L. Higgins, III, MD, Department of Emergency Medicine, Maine Medical Center, 22 Bramhall St, Portland, ME 04102.*

Initial medical evaluation revealed a lethargic boy with intermittent agitation. His blood pressure was 110/60 mm Hg, pulse rate 72 beats per minute, respiratory rate 12/min, and his temperature was normal. When aroused, he was able to answer questions appropriately, although he demonstrated a nonfluent aphasia. A 0.5-cm puncture wound of the posterolateral right side of the soft palate was noted (Figure 1). No other evidence of trauma was found. Carotid pulses were equal. Neurologic deficit was localized to the left side and revealed a homonymous hemianopia, facial weakness, deviation of the tongue to the left, flaccid hemiparesis, hypoesthesia to pinprick sensation, hyperreflexia, and Babinski sign. The remainder of the physical examination was unremarkable.

The diagnosis of traumatic ICA thrombosis on the right side was suspected, and a computed tomographic (CT) brain scan obtained. Axial images without contrast revealed no evidence of infarction (Figure 2) but did show increased density in the area of the right middle cerebral artery, suggesting acute thrombosis or diminished flow. Follow-up images with contrast demonstrated edema in the right parapharyngeal space.

Selective right carotid artery angiography demonstrated marked tapering and total occlusion of the right ICA approximately 3 cm above its origin (Figure 3), with no extension of contrast material intracranially. The external carotid artery was patent but failed to contribute collateral flow to the intracranial circulation. A follow-up CT brain scan with contrast 9 days after the initial study showed a large area of infarction and cytotoxic edema involving both gray and white matter in the frontal, temporal, and parietal lobes on the right side (Figure 4).

His severe neurologic deficit persisted without improvement, and a long-term rehabilitation program was initiated.

continued from page 316

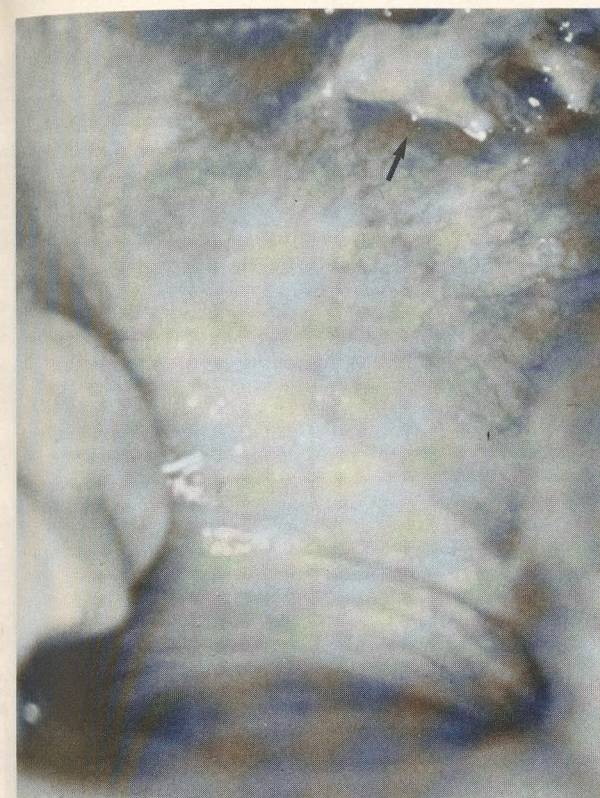

Figure 1. Puncture wound of the right posterolateral soft palate.

## Discussion

Penetrating injuries of the soft palate are not uncommon among pediatric and young adult patients, reflecting the general activity levels of these age groups. Children tend to carry potentially dangerous objects in the mouth (eg, pencils, sticks, lollipops), while young adults are often traumatized in motor vehicle accidents and athletic events.

Fortunately, most palatal impaling injuries heal uneventfully, completely, and without complication, as the soft palate demonstrates significant healing capacity.<sup>5</sup> The potential for a serious neurologic catastrophe exists, however, with any penetrating palatal trauma. In 1936, Caldwell<sup>3</sup> described the first case of acute palatal perforation leading to ICA occlusion. Since that initial report, intraoral injuries with resultant carotid artery trauma have been associated with saber thrusts,<sup>35</sup> metal rods,<sup>2</sup> pencils,<sup>1,2,6</sup> garden stakes,<sup>2</sup> sticks,<sup>1,11,36</sup> arrows,<sup>12</sup> rulers,<sup>37,38</sup> toothbrushes,<sup>12</sup> ballpoint pens,<sup>4</sup> knitting needles,<sup>4</sup> and rat-tail combs.<sup>14</sup>

Clues to developing ICA dissection include ipsilateral Horner's syndrome and hemicrania,<sup>39</sup> but the presence of a pulse and the absence of a bruit do not rule out

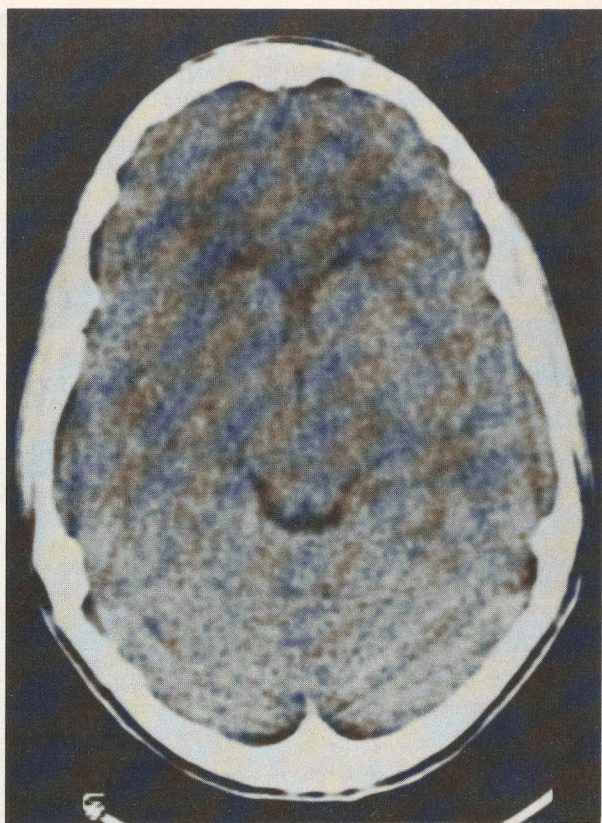


Figure 2. Initial noncontrast computed tomographic brain scan, which is essentially normal.

this possibility.<sup>40</sup> Wound characteristics that indicate a potentially significant injury include pain and tenderness at the mandibular angle<sup>7</sup> and lateral location of the puncture site. Lateral lesions are anatomically closer to the ICA as it courses posteriorly to the tonsillar fossa.<sup>10</sup> Intimal injury results either directly from vessel penetration or indirectly from pressing the ICA between the impaling object and the upper cervical transverse processes.<sup>7,11,12</sup>

In most cases of soft palate impalement causing ICA injury, the intimal flap becomes the nidus for localized thrombogenesis. Significant factors contributing to the degree of neurological deficit that ultimately occurs are the extent of intracranial propagation of the thrombus and its subsequent embolization.<sup>41</sup> Thrombus contained only within the proximal ICA promises significantly better outcome than thrombus that has advanced to the middle or anterior cerebral circulations. Adequate collateral intracerebral circulation exists through the circle of Willis in nearly one half of patients,<sup>11</sup> allowing some victims of total ICA occlusion to remain asymptomatic.<sup>22</sup> Distal extension of the thrombus will likely lead to the development of acute stroke syndrome within 24 hours.<sup>7</sup>

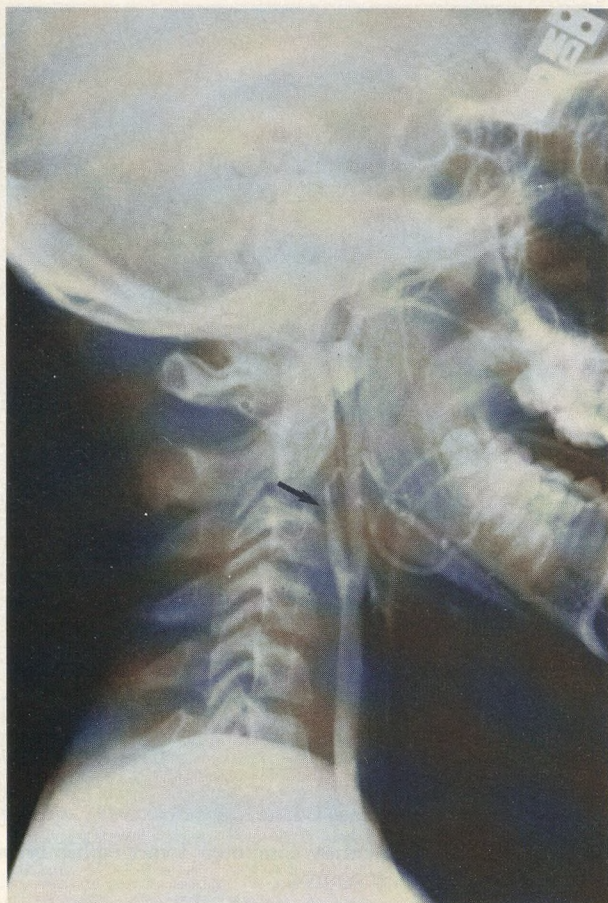

Figure 3. Carotid angiogram of the right side demonstrating marked tapering and total occlusion of the internal carotid lumen 3 cm above its origin.

Thrombus embolization with associated transient ischemic attacks can be an important clue to the presence of ICA injury and provide the astute clinician with a window of therapeutic opportunity.

Diagnosis is easier when the palate injury and the onset of neurologic symptoms and signs are immediately linked. The latency period between injury and resultant stroke syndrome, however, can approach 48 hours.<sup>7</sup> In addition, personal recall of the initial event, especially from young children or mentally impaired adults, can be inaccurate.

Patients remaining alert despite the presence of significant neurological deficit should be suspected of having ICA thrombosis.<sup>10,25</sup> Intracranial causes of traumatic central nervous system impairment usually are associated with mental obtundation.

Often a CT brain scan is the initial diagnostic study carried out when a central nervous system deficit develops in the context of intraoral trauma. A negative scan in

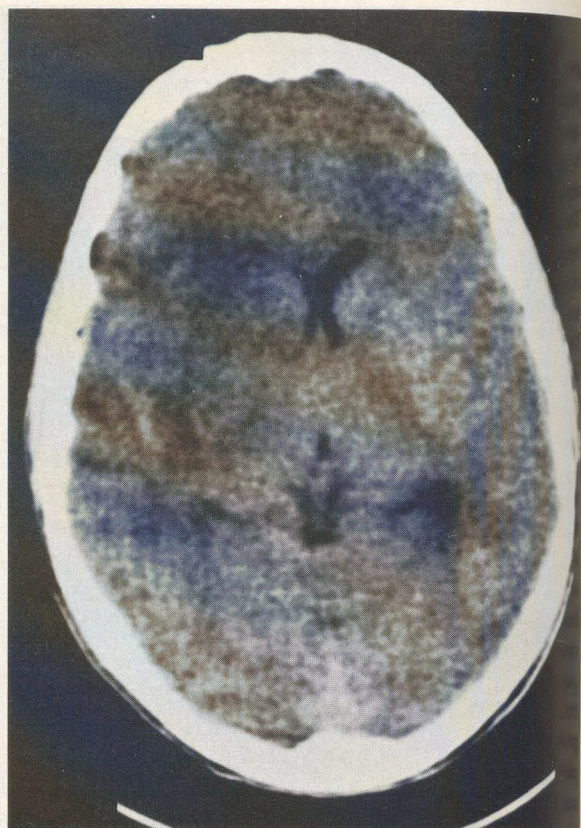


Figure 4. Follow-up computed tomographic brain scan with contrast 9 days after the initial study demonstrating right-sided infarction and cytotoxic edema involving the frontal, temporal, and parietal lobes.

such instances should raise the possibility of a more proximal ICA occlusion, even when the palatal injury itself appears to be trivial.<sup>10,40,42</sup> Serial CT scans often demonstrate evolution of progressive edema in a distribution atypical for traumatic contusion.<sup>43</sup>

Although such noninvasive techniques as ocular plethysmography can be used to detect abnormal carotid blood flow,<sup>7,10,25,43</sup> only angiography can definitively establish the site of vessel injury and extent of thrombosis.

Once the diagnosis of ICA injury has been established, surgical and medical management depend on the degree of neurologic deficit. Emergency surgery should be performed if minimal central nervous system dysfunction is present. Numerous successful techniques have been reported,<sup>15-25</sup> including thrombectomy and simple suturing, resection and anastomosis, interposition of a saphenous vein graft or an arterial autograft, applying a polyester fiber (eg, Dacron) graft, and extracranial to intracranial bypass grafting for selected inaccessible lesions.

Medical management, used in conjunction with surgery, has generally consisted of anticoagulant and antiplatelet therapy.<sup>7</sup> The role of the newer thrombolytic agents in the context of early ICA thrombosis has yet to be defined. Studies are currently being conducted to determine their value in stroke syndrome patients.<sup>26-34</sup> The risks of transforming an ischemic infarction into a hemorrhagic one always exists, and the potential benefit of systemic anticoagulation or thrombolysis in the context of a significant neurologic deficit is questionable. Patients with minimal or evolving neurologic deficits are likely to benefit from surgical or medical management. Patients presenting with completed stroke syndromes are unlikely to respond.

Patients with penetrating palatal injuries but without neurologic symptoms or signs present a dilemma. If the suspicion of an underlying asymptomatic ICA injury is high, or the social circumstances are such that home observation is unreliable, then admission for 24 to 48 hours of observation can be defended. Although the onset of neurologic deficit can be delayed, the majority of patients will develop evidence of ICA thrombosis within this 2-day window. Serial noninvasive studies, such as periorbital directional Doppler examination or oculoplethysmography, would prompt emergent angiography and possible systemic anticoagulation or thrombolysis should any disturbance of carotid flow develop.

For patients being discharged, it is imperative that they and responsible home observers be explicitly and clearly advised to seek immediate medical consultation should any neurologic symptoms develop. A list of representative signs and symptoms should be provided in the discharge instructions.

#### References

- Bickerstaff ER. Aetiology of severe hemiplegia in childhood. *Br Med J* 1964; 2:82-7.
- Braudo M. Thrombosis of the internal carotid artery in childhood after injuries in the region of the soft palate. *Br Med J* 1956; 1:665-7.
- Caldwell JA. Post traumatic thrombosis of the interior carotid artery. *Am J Surg* 1936; 32:522-3.
- Crawford BS. The management of perforating wounds of the palate. *Br J Plast Surg* 1970; 23:262.
- Domarus HV, Poeschel W. Impalement injuries of the palate. *Plast Reconstr Surg* 1983; 72:656-8.
- Fairburn B. Thrombosis of the internal carotid artery after soft palate injury. *Br Med J* 1957; 2:540-1.
- Hengerer AS, DeGroot TR, Rivers RJ, et al. Internal carotid artery thrombosis following soft palate injuries: a case report and review of 16 cases. *Laryngoscope* 1984; 94:1571-5.
- Holyst J. Internal carotid artery occlusion due to intraoral trauma. *Acta Neurochir* 1976; 33:325-9.
- Martin N, Warren GC. Thrombosis of the internal carotid artery due to intra-oral trauma. *South Med J* 1969; 62:103-7.
- Mears GD, Leonard RB. Blunt carotid artery trauma: a case report. *J Emerg Med* 1988; 6:281-4.
- Pitner SE. Carotid thrombosis due to intraoral trauma. *N Engl J Med* 1966; 274:764-7.
- Sharon E, Cohn D, Streighler H, et al. Penetrating injuries of the parapharyngeal space. *Arch Otolaryngol* 1972; 96:256-9.
- Smith MEN. Injuries of the palate and fauces in children. *Br J Clin Pract* 1959; 13:714.
- Woodhurst WB, Robertson WD, Thompson GB. Carotid injury due to intraoral trauma: case report and review of the literature. *J Neurosurg* 1980; 6:559-63.
- Brown MF, Graham JM, Feliciano DV, et al. Carotid artery injuries. *Am J Surg* 1982; 144:748-53.
- Jordan BP, Mayschak DT, Flye MW. Treatment of the totally occluded carotid artery. *Arch Surg* 1984; 119:952-5.
- Karlin RM, Marks C. Extracranial carotid artery injury. *Am J Surg* 1983; 146:225-7.
- Krajewski LP, Hertzner NR. Blunt carotid artery trauma. *Ann Surg* 1980; 191:341-6.
- Padberg FT, Hobson RW, Yeager RA, Lynch TG. Penetrating carotid arterial trauma. *Am Surg* 1984; 50:277-82.
- Pellegrini RV, Manzetti GW, DiMarco RF, et al. The direct surgical management of lesions of the high internal carotid artery. *J Cardiovasc Surg* 1984; 25:29-35.
- Perry MO, Snyder WH, Thal ER. Carotid artery injuries caused by blunt trauma. *Ann Surg* 1980; 192:74-7.
- Ringelstein EB, Zeumer H, Angelou D. The pathogenesis of strokes from internal carotid artery occlusion: diagnostic and therapeutic implications. *Stroke* 1983; 14:867-75.
- Robbs JV, Human RR, Rajaruthnam P, et al. Neurological deficit and injuries involving the neck arteries. *Br J Surg* 1983; 70:220-2.
- Yamada S, Kindt GW, Youmans JR. Carotid artery occlusion due to nonpenetrating injury. *J Trauma* 7:333-42.
- Zelenock GB, Kazmers A, Whitehouse WM, et al. Extracranial internal carotid artery dissections. *Arch Surg* 1982; 117:425-31.
- Barsan WG, Brott TG, Olinger CP, et al. Identification and entry of the patient with acute cerebral infarction. *Ann Emerg Med* 1988; 17:95-8.
- Brott T, Kaley EC, Levy DE, et al. The investigational use of tPA for stroke. *Ann Emerg Med* 1988; 17:115-8.
- Brott TG, Haley EC, Levy DE, et al. Very early therapy for cerebral infarction with tissue plasminogen activator (tPA) [Abstract]. *Stroke* 1988; 19:133.
- del Zoppo GJ. Investigational use of tPA in acute stroke. *Ann Emerg Med* 1988; 17:109-14.
- del Zoppo GJ, Zeumer H, Harker LA. Thrombolytic therapy in acute stroke: possibilities and hazards. *Stroke* 1986; 17:595-607.
- Olinger CP, Brott TG, Barsan WG, et al. Use of ancrod in acute or progressing ischemic cerebral infarction. *Ann Emerg Med* 1988; 17:123-4.
- Sloan MA. Thrombolysis and stroke: past and future. *Arch Neurol* 1987; 44:748-68.
- The tPA-Acute Stroke Study Group. An open multicenter study of the safety and efficacy of various doses of rt-PA in patients with acute stroke: preliminary results. *Stroke* 1988; 19:134.
- Timerding BL, Barsan WG, Hedges JR, et al. Stroke patient evaluation in the emergency department before pharmacologic therapy. *Am J Emerg Med* 1989; 7:11-5.
- Philippides D, Linck P, Montriou B. Thrombose de la carotide interne par contusion brune para-amygdalienne. *Rev Otoneuroophthalmol* 1954; 26:39.
- Shillito J. Carotid arteritis—a cause of hemiplegia in childhood. *J Neurosurg* 1964; 21:540-51.
- Leriche R. Hemiplegie ganche consecutive a une contusion de la carotide/interne chez un enfant: traitement par clinic infiltrations/steusunes; gression a peu pres complete. *Lyons/Chir* 1950; 45: 541.
- Miller JDR, Ayers TN. Post traumatic changes in the internal carotid artery and its branches: an arteriographic study. *Radiology* 1967; 89:95-100.
- Mokri B, Thoralf MS, Houser OW. Spontaneous internal carotid

- dissection, hemicrania, and Horner's syndrome. *Arch Neurol* 1979;677-80.
40. Youmans JR, Mims TJ. Trauma to carotid arteries. In: Youmans JR, ed. *Neurological surgery*. 2nd ed. Philadelphia: WB Saunders, 1982:2314-7.
41. Wishoff HS, Rothballer AB. Cerebral anterior thrombosis in children. *Arch Neurol* 1961; 4:258-67.
42. French MD, Cully CA, Dublin AB. Cranial computed tomography in the diagnosis of symptomatic indirect trauma to the carotid artery. *Surg Neurol* 1981; 15:256-67.
43. Ernst A, Robertson HJ, Bercier ML, et al. Occult carotid artery injury related to automobile seat belts. *Ann Emerg Med* 1988; 17:143-6.

## Manuscript Submission

to

### *The Journal of Family Practice*

#### Submit Manuscripts to the Editor

Paul M. Fischer, MD  
Department of Family Medicine  
Medical College of Georgia  
Augusta, GA 30912  
1(404) 855-2196



Appleton & Lange, 25 Van Zant Street, Norwalk, CT 06855, (203) 838-4400