

The 'Modified U' Technique: A Refined Method of Norplant Removal

Ronald D. Reynolds, MD
New Richmond, Ohio

Norplant removal has been much more difficult for many physicians than might have been anticipated. Dr Untung Praptohardjo of Indonesia recently developed the "U" technique, speeding the time required to remove the six Norplant implants to an average of 7 minutes. In his technique, a unique oval-ring-tipped forceps with an internal diameter of 2.2 mm is used to reach through a 4-mm incision to firmly grasp each of the implants. The incision is made parallel to the implants between the lower tips of implants 3 and 4. The "U" technique requires grasping the implant within 4 mm to 5 mm of its tip.

This preliminary paper describes the "Modified U" technique, which allows the physician who is removing the implants to grasp them anywhere along their shaft, not just near the tip. The Modified U technique involves the use of an improved ring-tipped forceps with a circular tip rather than the oval tip used in the "U" technique. This instrument, called Norgrasp, is a modi-

fication of the vas deferens fixation forceps used in the no-scalpel vasectomy (NSV) technique. In another adaptation of NSV instruments, an NSV dissecting forceps (a sharpened, curved hemostat) is used to free the implants from their tissue envelope and quickly deliver them through the skin incision.

Using the Modified U technique, the time required to remove Norplant implants in 20 patients in the United States has ranged from 8 to 13 minutes. Improperly placed implants are readily removed with this technique. The Modified U technique requires a minimal incision and offers both the physician and the patient a speedy, positive removal.

Key words. Contraceptive devices, female; levonorgestrel; Norplant implants; Norplant removal; Modified U technique; subdermal contraceptive implants; Norgrasp. (*J Fam Pract* 1995; 40:173-180)

The Norplant System is an implantable contraceptive device that releases levonorgestrel from six Silastic capsular implants over a 5-year period.¹ Since the Silastic surrounding the levonorgestrel is biologically inert, the implants are removed from their site in the medial upper arm at the end of 5 years.¹ Patients may choose to have them removed earlier because of undesirable side effects or because they want to restore their fertility. Nearly one million US women have chosen Norplant for contraception since its release in February 1991.²

Wyeth-Ayerst, the US distributor of Norplant, has

offered training in insertion and removal techniques to all interested physicians. Removal is not as simple and straightforward as it might seem. A tissue envelope forms around the implants, holding them firmly affixed in their subdermal position. This envelope impedes movement and manipulation of the implants during removal. The tissue envelope must be opened to free each implant. If the implants were not correctly placed, they may be especially difficult to remove. Removing the implants through a short, cosmetically acceptable incision may be initially difficult for many physicians.

Wyeth-Ayerst's suggested removal method (standard technique) uses an 11-blade scalpel and a curved and straight hemostat.¹ A 4-mm transverse incision is made at or just proximal (toward the shoulder) to the original insertion point. The straight hemostat is used to bluntly

Submitted November 16, 1994.

From the New Richmond Family Practice, New Richmond, Ohio. Requests for reprints should be addressed to Ronald D. Reynolds, MD, 1050 Old US 52, New Richmond, OH 45157.

dissect around the distal (elbow) ends of the implants. The tips of the implants are located one at a time by palpation and grasped from below using the blades of the curved hemostat. Traction on the hemostat brings the implant down to the incision. The tissue envelope around the implant is then opened with the scalpel. The exposed, bare implant is then grasped and removed with the straight hemostat.

Mastering the standard technique has been initially difficult for many physicians. Removal times can vary widely from 20 to 55 minutes, even in experienced hands.³ Some physicians have tried to remove the implants using the practice hemostats supplied in Wyeth-Ayerst's Norplant removal kit. These have bulky blades that do not dissect or grasp effectively through the small incision recommended. Even when smaller instruments are used, it can be difficult to hold the slippery implant's tip firmly in the curved hemostat. Excess tissue is often grasped along with the implant, making it difficult to expose the implant's tip.

A modification of the standard technique was developed by Drs Seshu Sarma and Robert Hatcher at Emory University in Atlanta.³ The so-called Emory technique uses a larger volume of local anesthetic (6 mL), an identically placed but longer incision (1 cm), and "vigorous disruption of tissue encapsulation" around the implant tips with the curved hemostat. Removal time using this technique was less than 10 minutes in 88% of the 50 removals they reported. It is implied in their report that removal of deeply or erratically placed implants using this technique required more time. The longer scar may be cosmetically unacceptable to some women.

The University of California at San Francisco has recently circulated a continuing medical education videotape among physicians who perform implants that demonstrates a new "no-instruments" removal technique. The "pop-out" technique developed by Dr Philip Darney and colleagues uses a 3-mm transverse incision just toward the shoulder from the insertion point.⁴ Each implant is manually pushed down to the incision and removed after opening the tissue envelope with an 11-blade scalpel. Removal times average around 20 minutes in experienced hands using the pop-out technique.⁴ The author has found, however, that if implant placement is not ideal, manipulating all six implants to the incision can be difficult, if not impossible.

The need for safe, speedy, simple, and reliable removal techniques will become even more important as the 5-year anniversary of Norplant's release approaches. A large number of implants will need to be removed within the next few years. Physicians will need to be adept at removal to meet this demand. Both the standard and pop-out techniques are time-consuming and can be diffi-

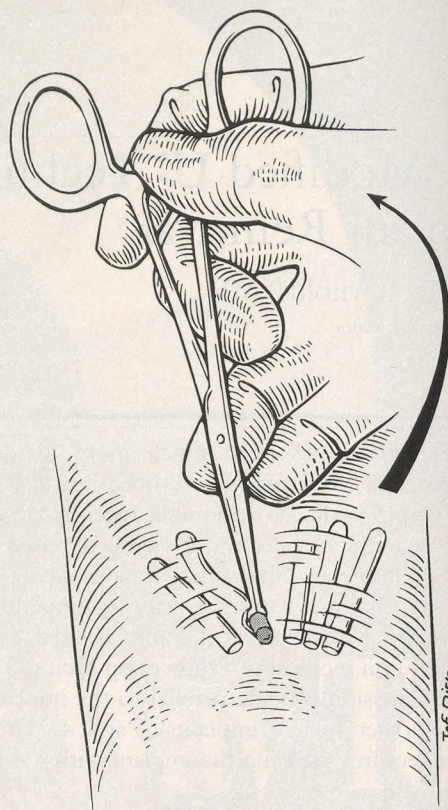


Figure 1. The "U" technique of Norplant removal. Implant 3 has been removed. The tip of implant 2 is delivered out of the incision by lifting the ring-tipped forceps toward the patient's shoulder. Drawing reproduced with permission of Jef Dirig.

cult to master. The Emory technique is faster, but none of the three methods is easy to use for the removal of improperly placed implants. New removal techniques are needed, especially for difficult removals.

The "U" Technique

An innovative removal technique was recently developed in Indonesia. It was dubbed the "U" technique after its developer, Dr Untung Praptohardjo.⁵ A 4-mm vertical incision is placed parallel to the implants, between implants 3 and 4, near where their tips touch. Each implant is grasped by surrounding its tip with a ring-tipped forceps. The tip is delivered out of the incision by lifting the ring-tipped forceps handle toward the patient's shoulder (Figure 1). Wiping with gauze or incising with a scalpel opens the tissue envelope that surrounds the implant tip. Each implant is then grasped and removed with a hemostat.

When the "U" technique was performed by Dr Un-

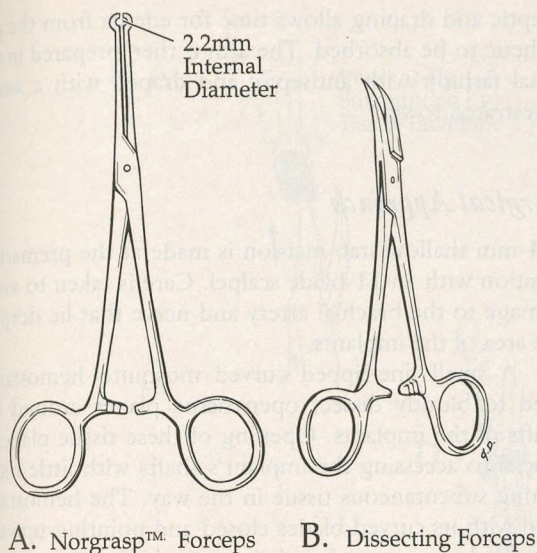


Figure 2. Unique instruments used for the Modified U technique of Norplant removal. Drawings reproduced with permission of Jef Dirig.

tung, removal time averaged 7 minutes in 38 patients.⁵ None of the patients required two incisions to remove all six implants. Dr Untung feels that difficult removals are much easier with the "U" technique because the grasp on the implant is more secure than with a hemostat. The placement of the incision is such that there is often a shorter distance to all the implants.

Problems with the "U" Technique

Dr Untung's ring forceps has an oval-shaped ring that gives a loose fit around the implants. An improved ring-tipped forceps with a circular tip (Advanced Meditech International, Flushing, NY) is shown in Figure 2A. Dubbed "Norgrasp" by the author, it is a modification of the vas deferens fixation clamp used in no-scalpel vasectomy (NSV).⁶ The ring's internal diameter (2.2 mm) is smaller than that of the NSV ring for a snug fit around the pliable 2.4-mm Norplant implant.

The original NSV ring clamp itself cannot be used for Norplant removal for two reasons. First, the ring is much too big to firmly grasp the implants and will not fit through the small incision. Second, the tips of the NSV ring clamp are designed to separate as it is locked, thereby minimizing scrotal skin trauma.⁶ This feature is counterproductive to Norplant removal, since it allows the implant to slip out of grasp. In contrast, Norgrasp securely holds the implants once locked around them.

In the "U" technique, Dr Untung does not open tissue planes around the implants. The author has found it

difficult to grasp the implants if the Norgrasp forceps cannot fully surround the implant. If the ring has to push tissue surrounding the implant away as it approaches, the tissue can act as a bowstring stretched between the tips of the open ring, pushing the implant out of the ring's grasp. Blunt dissection to open tissue planes that are both superficial and deep to the implants has solved this problem.

The author has also found it difficult to consistently grasp the Norplant implants near their tips. This is particularly true in deeply placed implants or in obese patients, where palpating the position of the tips closest to the insertion point can be nearly impossible. The thicker dermis and subcutaneous tissue of Western women, as contrasted with Indonesian women, may amplify this palpation problem. Even in superficially placed implants, the tips can be very close together, making differentiation of each implant difficult. The author finds that the "U" technique's delivery of the tip is impossible if the implant is not grasped within 4 mm or 5 mm of its tip.

Unlike all other removal methods that require the removing practitioner to find a single point in the tissue (the implant's tip), a technique that allows an implant to be grasped anywhere along its *shaft* would be advantageous. Grasped in this manner with the Norgrasp forceps, the implants can readily be brought to the incision by traction. If the Norgrasp forceps handle is then lifted toward the patient's shoulder, a short portion of the implant within its tissue envelope is exposed in the inferior portion of the incision.

Rather than using a scalpel to open the tissue envelope, an NSV dissecting forceps (a short, curved hemostat with the blades sharpened to a needle point, Figure 2B)⁶ can be used to tear open the envelope, skewer, and deliver the implant. Use of the NSV dissecting forceps minimizes the number of instruments that the physician must handle in performing implant removal, and thus can speed the operating time.

With this background, a modification of the "U" technique was developed by the author.* Unlike the traditional "U" technique, (1) blunt dissection opens a path to the implants, (2) the grasp is not just at the tip but can be anywhere along the shaft of the implant, and (3) a technique similar to NSV dissection is used to free the implant from its tissue envelope.

Preliminary experience with the first 20 removals suggests that this new technique is quick, simple, and appropriate for potentially difficult removals. Removal time has ranged from 8 to 13 minutes.

*An instructional videotape on the Modified U technique is available through Advanced Meditech International, Flushing, NY; (718) 672-7150.

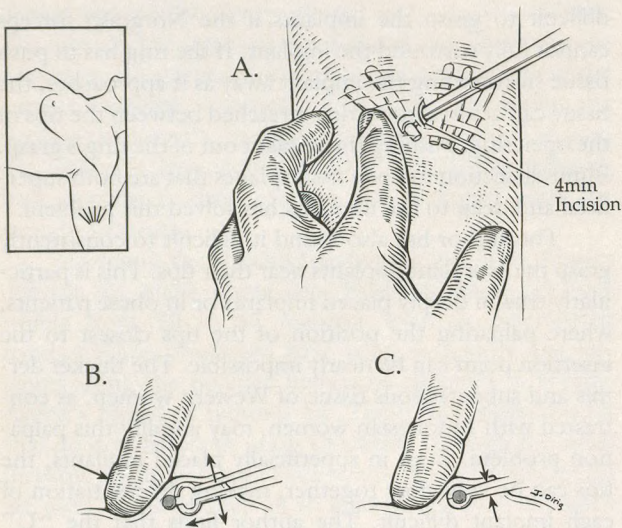


Figure 3. The Modified U technique of Norplant removal. Implant 2 is being grasped through a 4-mm incision parallel to the implants (A). The process of grasping the implant as it is pushed into the ring tip by the palpating finger is shown in cross-section (B and C). Drawings reproduced with permission of Jef Dirig.

The Modified U Technique

Instruments

Four instruments are used for the Modified U technique: (1) 11-blade scalpel; (2) fine-tipped curved mosquito hemostat (eg, Miltex 7-10 [Miltex Instrument Co, Inc, Lake Success, NY]); (3) Norgrasp forceps; (4) NSV dissecting forceps.

Patient Preparation and Anesthesia

The patient is placed in the same position as for Norplant insertion: supine with shoulder abducted and her hand next to her head. The implants are palpated to determine their position. A skin-marking pen is used to mark the location of a 4-mm incision parallel to the implants between the third and fourth implants. Some clinicians may also wish to mark the location of each implant. The elbow end of the incision is placed approximately 5 mm toward the shoulder from the implant tips (Figure 3A).

An alcohol pad is used to cleanse an area surrounding the insertion point for entry of the anesthetizing needle. Neutralized 1% lidocaine with epinephrine is infiltrated subcutaneously with a 1¼-in, 27-gauge needle both superficial and deep to the elbow end of the implants and under the planned incision. The addition of epinephrine minimizes bleeding and bruising. Anesthetic volume is limited to 3 mL; more than this would make palpation difficult. Anesthetizing before preparing the skin with an-

tiseptic and draping allows time for edema from the anesthetic to be absorbed. The arm is then prepared in the usual fashion with antiseptic and draped with a sterile fenestrated towel.

Surgical Approach

A 4-mm shallow stab incision is made at the premarked position with an 11-blade scalpel. Care is taken to avoid damage to the brachial artery and nerve that lie deep to the area of the implants.

A small fine-tipped curved mosquito hemostat is used to bluntly dissect open tissue planes around the shafts of the implants. Opening of these tissue planes is crucial to accessing the implant's shafts with little intervening subcutaneous tissue in the way. The hemostat is held with its curved blades closed and pointing upward. The blades are introduced through the incision toward the practitioner's left (toward implants 1, 2, and 3) and advanced laterally, perpendicular and just superficial to the implants. An open-close motion of the blades opens a tissue plane 4 mm to 5 mm in width between the implants and the skin. The same procedure is performed immediately beneath the implants by starting to the left between implants 3 and 4.

The blunt dissection is repeated to the right of the incision. Right-handed physicians will find it more comfortable to take a step to the left when working on the three implants to the right of the incision.

Grasping the Implants

The Norgrasp forceps is used to grasp each implant anywhere along its shaft. Figure 3A shows removal from the left upper arm. If an implant can be seen in the incision, as is often the case with implants 3 and 4, it is simply grasped in the ring tip under direct vision.

To grasp implants that can only be palpated, the physician's nondominant index finger is placed along the axis of, and just lateral to, the closest palpable implant. The Norgrasp forceps is closed (but not locked) and inserted through the incision. The closed ring tip is advanced until it touches the implant. As the forceps is opened, the palpating finger pushes the implant into the grasp of the ring tip (Figure 3B). The forceps is closed and locked around the implant (Figure 3C).

After the implant is firmly grasped, traction is applied to bring it to the incision. When the ring is visible in the incision, the handles of the Norgrasp forceps are lifted toward the patient's shoulder and held in this position with the nondominant hand. If the grasp is within 4 mm to 5 mm of the tip, the tip itself may emerge from the

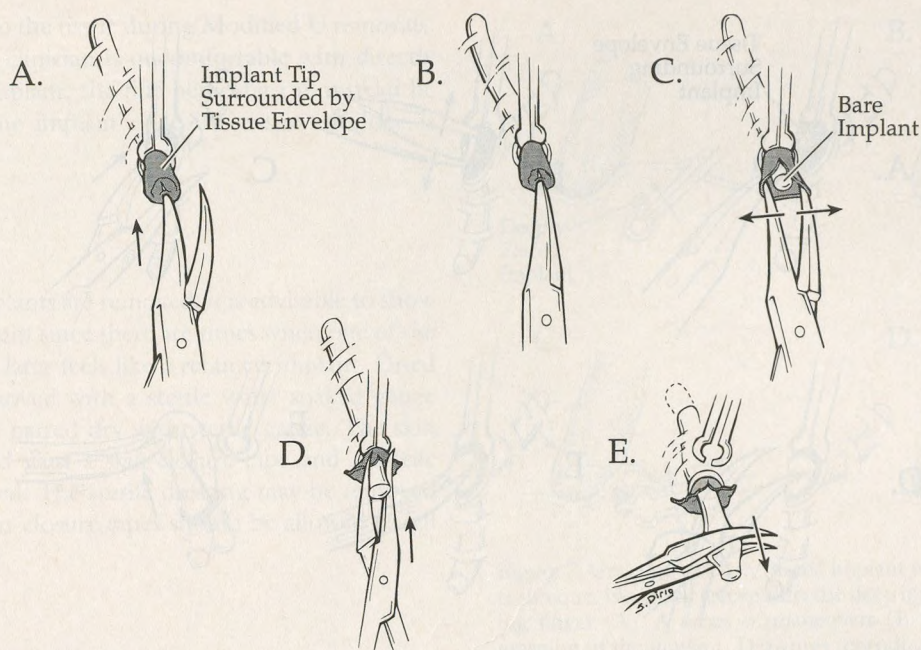


Figure 4. Opening the tissue envelope surrounding the implant's tip. The left blade of the dissecting forceps punctures the tissue envelope (A). The closed tips are reintroduced into the same opening (B) and spread to open the tissue envelope (C). Blade tips are then rotated upward and used to push the tissue envelope back (D), and the bare implant is grasped and removed (E). Drawings reproduced with permission of Jef Dirig.

inferior end of the incision as in the traditional "U" technique. More often, a portion of the implant's shaft is exposed in the inferior end of the incision. In either case the implant is surrounded by a tissue envelope that must be opened.

Opening of the Tissue Envelope Around the Implant

The tissue envelope that surrounds the implant must be opened before the implant is free to remove. The NSV dissecting forceps is used for both this task and to deliver the implant. For improved control, the dissecting forceps is always held with the practitioner's index finger on the hinge.

If the *tip* has been delivered out, the left blade of the dissecting forceps is used to sharply puncture the surrounding tissue envelope at the center of the implant's tip (Figure 4A). The depth of this puncture through the tissue envelope and into the thick end of the implant is about 2 mm. After withdrawing the left blade, the blades are closed (but not locked) and inserted in the opening just made (Figure 4B). Opening the blades stretches the tissue envelope open, exposing the bare end of the implant (Figure 4C). The dissector is rotated clockwise

around its long axis until its blades curve upward. The blades are used to push the envelope back along the shaft of the implant (Figure 4D) and then to grasp the implant itself (Figure 4E). Unlocking the Norgrasp forceps frees the implant for removal.

More commonly, the shaft rather than the tip of the implant will be exposed in the incision. A 4×4 gauze pad may be used to wipe over the implant toward the patient's elbow, further exposing the implant in its tissue envelope. In this situation, the NSV dissecting forceps is used in a different manner to open the tissue envelope. Clinicians experienced in NSV technique will recognize that the implant covered with its tissue envelope presents similar surgical anatomy to the vas deferens and its sheath. However, the usual NSV single-blade puncture and double-blade stretch that opens tissue layers during vasectomy⁶ cannot be used along the shaft of Norplant. To do so would tear open the implants, except when performed at the thick and durable tips as described above.

The closed blade tips of the dissecting forceps work well to tear the tissue envelope open. The tissue envelope is torn along the axis of the implant. Caution is required to avoid slipping and scratching the patient's skin (Figure 5A). The exposed bare implant has a characteristic shiny surface that is easy to differentiate from the tissue enve-

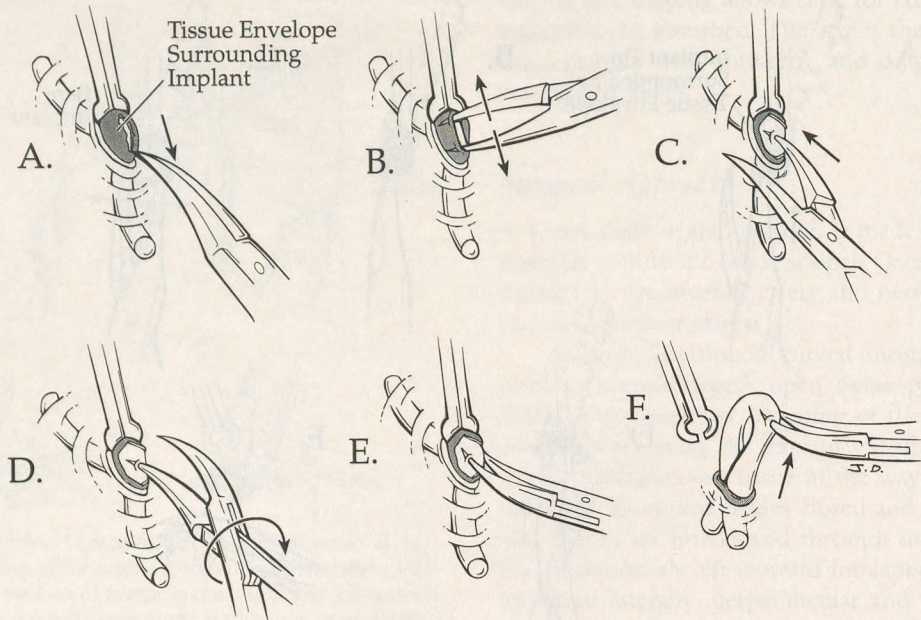


Figure 5. The Modified U technique of Norplant removal. After grasping the implant along its shaft and bringing it to the incision, the dissecting forceps is used to tear open the surrounding tissue envelope (A). The tissue envelope opening is enlarged (B). Skewering the implant with the right blade (C) and rotating the forceps clockwise 180° (D and E), allows the bare implant to be lifted free as a U-shaped loop (F). Drawings reproduced with permission of Jef Dirig.

loped. If it is unclear whether the tissue envelope is open, the closed dissecting forceps tips can be gently rubbed on top of what appears to be the bare implant. If a tissue layer is still present, it will move with the tips.

Generally, the initial opening in the tissue envelope needs to be enlarged to allow the implant to be lifted out. The closed dissecting forceps is held with the blade's curve facing downward and perpendicular to the axis of the implant. The blade tips are placed in the plane between the implant and left side of the opening in the tissue envelope. Opening the forceps blades along the axis of the implant enlarges the tissue envelope opening (Figure 5B). The length of the opening is stretched to twice the width of the implant.

Delivery of the Implant

In an analogy to the vas in NSV,⁶ the implant is skewered and delivered through the opening in the tissue envelope. Held with the blade's curve facing downward, the dissecting forceps is opened. The right blade is used to firmly skewer the implant in the center of the envelope opening (Figure 5C). The blade tip punctures the front wall of the implant and enters 2 mm to 3 mm into its cavity. Rotating the forceps 180° clockwise along its axis (by supinating the forearm palm up) causes a small loop of the implant to

hang on the now upward-facing forceps blade tip (Figures 5D and E).

The dissecting forceps is closed to gently hold the implant. To avoid cutting through the Silastic, the forceps is not locked. The clinician must be careful not to apply too much lifting force at this point. Since it is still constrained by the ring, the implant will not lift very far. Releasing the Norgrasp forceps will allow delivery of the implant as a U-shaped loop (Figure 5F), imparting another, more procedural meaning to the "U" technique.

If it is difficult to lift the implant once it is skewered, one of two things may be wrong. First, the tissue envelope may not be open. In this situation, the skewered implant must be regrasped with the Norgrasp forceps and another attempt to open the tissue envelope must be made. Second, the envelope opening may not be quite big enough. Since the implant's walls will collapse onto each other and effectively make the implant smaller, this usually can be overcome by exerting more lifting force. If lifted too vigorously, however, the dissecting forceps's sharp tips may cut through the implant. The Norgrasp forceps may be placed around the apex of the bare implant's loop, allowing more force of traction without the risk of severing the implant.

The author has had no difficulty with tearing or fragmenting of the implants, nor with release of levonorgestrel.

estrel crystals into the tissue during Modified U removals. However, if the clinician is uncomfortable with directly skewering the implant, the fine hemostat can instead be used to grasp the implant once the tissue envelope is opened.

Final Steps

When all the implants are removed, it is advisable to show all six to the patient since there are times when one of the tissue envelopes later feels like a retained implant. Dried antiseptic is removed with a sterile water-soaked gauze pad. Wet skin is patted dry with sterile gauze. The skin incision is closed with a skin-closure tape and a sterile dressing is applied. The sterile dressing may be removed in 24 hours. Skin-closure tapes should be allowed to fall off on their own.

Improving Speed and Safety

To speed removal, the dissecting forceps may be held in the clinician's dominant hand while grasping the next implant, as shown in Figure 6. The fourth finger is kept in the left handle hole and the forceps is rotated with its axis across the palm, pointing between the thumb and index finger. The pads of the little and ring fingers hold the dissecting forceps in place. The long finger and thumb are now free to hold the Norgrasp forceps. Following this procedure keeps the physician from having to put down and pick up instruments, speeding removal and decreasing the risk of dropping an instrument.

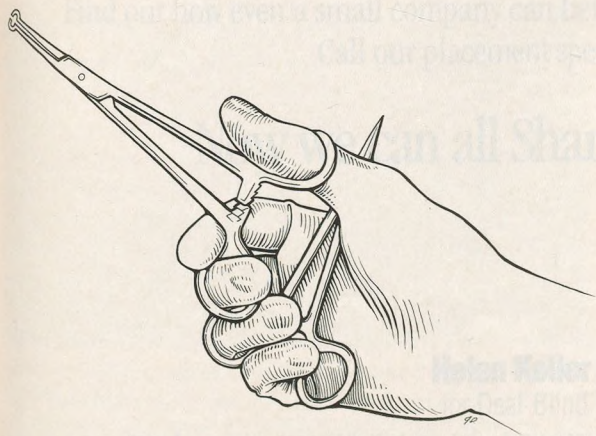


Figure 6. Holding both the Norgrasp and dissecting forceps in one hand. Drawing reproduced with permission of Jef Dirig.

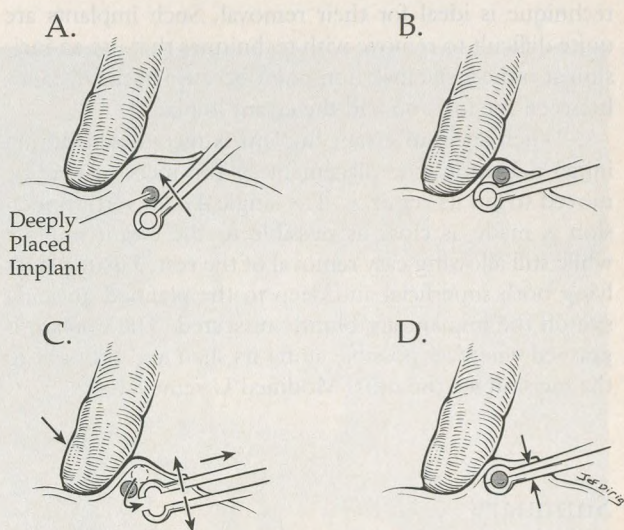


Figure 7. Grasping a deeply placed implant with the Modified U technique. Norgrasp forceps lifts the deep implant to the palpating finger (A). A series of maneuvers (B through D) allows grasping of the implant. Drawings reproduced with permission of Jef Dirig.

Difficult Removals

If a deep implant is difficult to palpate, the Norgrasp forceps can be used to help locate it. The closed ring is placed beneath and beyond where the implant is likely to be (Figure 7A). It is easy to tell when the Norgrasp forceps touches the implant because of the textural difference between the implant and the surrounding tissue. Lifting the ring tip will bring the implant up to the palpating finger (Figure 7B). To grasp the implant, the Norgrasp forceps is withdrawn, and the ring is opened (Figure 7C). As the implant drops down over the withdrawing ring, the palpating finger pushes it into the ring (Figure 7D). The ring tip is then closed and locked around the implant. This maneuver facilitates removal of deeply placed implants and may obviate the need for imaging techniques to find a "lost" implant, but caution is required to avoid touching the brachial nerve and artery that lie deep to this area.

When a palpable implant is difficult to grasp, the removing clinician should ensure that both the superficial and deep tissue planes surrounding the implant are open. Further blunt dissection with the fine curved hemostat may be necessary to allow a firm grasp of the implant.

If an implant is improperly placed, such as in a "corkscrew" or "U" shape, or if one is placed much farther from the insertion point than the others, the Modified U

technique is ideal for their removal. Such implants are quite difficult to remove with techniques that use an incision at or near the insertion point because of the distance between the incision and the errant implant.

When such an errant implant is recognized during initial palpation, the placement of the incision may be moved to aid its removal. The single 4-mm vertical incision is made as close as possible to the errant implant while still allowing easy removal of the rest. Tissue planes lying both superficial and deep to the planned grasping site on the implant are bluntly dissected. The implant is grasped wherever possible along its shaft and brought to the incision for the usual Modified U removal.

Summary

The Modified U technique is a refined and reliable method of Norplant removal that offers the advantages of grasping anywhere along the implant's shaft rather than just at the tip, establishing a secure grasp on the implants, and enabling quick removal times. The method appears ideally suited for difficult Norplant removals.

Acknowledgments

The author sincerely thanks Jef Dirig of The Ohio State University, Columbus, Ohio, for superb illustrations; Steve Wilhide and the Southern Ohio Health Services Network, Batavia, Ohio, for financial assistance with the illustrations; and Kevin Breslin, MD, of New Richmond, Ohio, and Philip Li, MD, of New York, NY, for carefully reviewing the manuscript and offering insightful suggestions for improvements.

The author receives royalties from Advanced Meditech International in Flushing, NY, for the sale of his copyrighted educational videotape on the Modified U technique.

References

1. Duffy MA, ed. Physicians' desk reference. 48th ed. Montvale, NJ: Medical Economics, 1994:2564-8.
2. Woodman S. The trouble with Norplant. *Allure* 1994; Oct:126-30.
3. Sarma SP, Hatcher R. The Emory method: a modified approach to Norplant implants removal. *Contraception* 1994; 49:551-6.
4. Darney PD, Klaise CM, Walker DM. The "pop-out" method of Norplant removal. *Advances in contraception [abstracts]*. Presented at the 8th annual meeting, Barcelona, Spain, Oct 28-31 1992; 8:188-9.
5. Praptohardjo U, Wibowo S. The "U" technique: a new method for Norplant implants removal. *Contraception* 1993; 48:526-36.
6. Li S, Goldstein M, Zhu J, Huber D. The no-scalpel vasectomy. *J Urol* 1991; 145:341-4.