

Diagnosing and Treating Onychomycosis

Nardo Zaias, MD; Brad Glick, DO, MPH; and Gerbert Rebell, MS

Miami Beach, Florida

Onychomycosis is a persistent fungal infection of the toenails or fingernails that is usually not painful but is unsightly and can affect a patient's quality of life by interfering with footwear. It may affect up to 30% of the population by age 60. In more than 99% of cases, it is caused by dermatophytes, the most common of which are *Trichophyton rubrum* and *Trichophyton mentagrophytes*.

Each of the four clinical types of onychomycosis, as defined by the route of fungal invasion, has a characteristic appearance, but other diseases, particularly psoriasis, may have a similar appearance. Proper management, therefore, includes confirmation of fungal infection by potassium hydroxide slide preparation and culture.

Onychomycosis is a fungal infection of the fingernails or toenails, usually by a dermatophyte, such as *Trichophyton*, *Microsporium*, and *Epidermophyton* spp.¹ These fungi infect the stratum corneum of the skin, hair, and nails. Onychomycosis may affect as many as 30% of the population by age 60² and is severe in some patients but mild in many others. In immunodeficient patients such as those with AIDS, onychomycosis can be severe.³ Many patients with onychomycosis have great concern about the abnormal appearance of their nails and seek treatment.

Susceptible patients develop onychomycosis in the home environment. Direct person-to-person transmission among nonsusceptible persons is rare.² Genetic factors may play a role in the development of onychomycosis, as evidenced by the familial pattern of the disease and the apparent predisposition to chronic infection in some families.

Traditionally, pharmacologic treatment has been less than optimal. In many cases, griseofulvin, the first oral agent approved for onychomycosis in the United States, must be given for 1 year or more to be effective. Low cure rates are related to poor bioavailability and the fungistatic rather than fungicidal effect of the drug. Newer agents, such as oral itraconazole and oral terbinafine, promise to substantially increase cure rates while shortening treatment duration. Oral terbinafine is potently fungicidal against dermatophytes and has proven efficacious with regimens as brief as 12 weeks when the nail is not 100% involved.

Key words. Onychomycosis; dermatophytes; fungal infection; terbinafine. (*J Fam Pract* 1996; 42:513-518)

Oral griseofulvin, the standard antifungal therapy for onychomycosis, produces low cure rates—generally less than 40% for toenail infections—because of poor bioavailability, and typically requires treatment for at least 6 to 12 months.⁴⁻⁶ Even with successful treatment, frequent recurrence is typical. Because of the long duration and low treatment success rates, patients may be discouraged from pursuing treatment. New oral agents, however, have the potential to dramatically increase cure rates while substantially decreasing length of treatment. This paper addresses the origin and clinical appearance of each of the four types of onychomycosis and describes the diagnosis and management of the disease.

Types of Onychomycosis

There are four types of onychomycosis: (1) distal subungual onychomycosis affecting the nail bed, (2) white superficial onychomycosis affecting the surface of the nail plate, (3) proximal subungual onychomycosis affecting the ventral and proximal area of the nail plate from the proximal nail fold (this type of onychomycosis is seen

Submitted, revised October 3, 1995.

From the Greater Miami Skin and Laser Center, Mount Sinai Medical Center, Miami Beach, Florida. Requests for reprints should be addressed to Nardo Zaias, MD, Greater Miami Skin and Laser Center, Mount Sinai Medical Office Pavilion, Miami Beach, FL 33140.

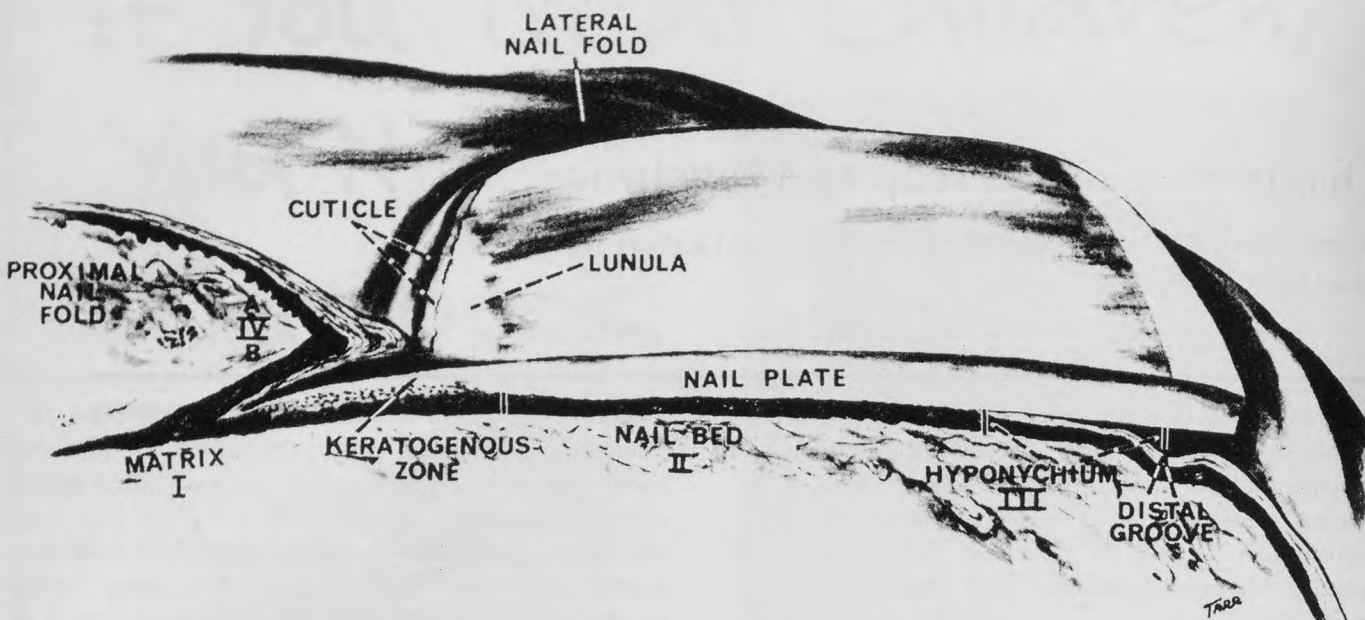


Figure 1. Parts of the nail unit: the nail plate (nail); the nail bed, (a bed of keratinocytes that move with the overlying nail plate and desquamate at the hyponychium); the hyponychium (the avenue of fungal invasion in the case of distal subungual onychomycosis); the proximal nail fold (the avenue of invasion in proximal subungual onychomycosis); and two lateral nail grooves (often in contact with lesions of white superficial onychomycosis). From Zaias N. *The Nail in Health and Disease*. New York, NY: Medical and Scientific Books, 1980. Reproduced with permission of the author.

predominantly in immunosuppressed patients), and (4) chronic mucocutaneous candidiasis by *Candida albicans* affecting the entire thickness of the nail plate. Each of these types is defined by its clinical appearance and invasion of the nail unit (Figures 1 and 2).²

In more than 90% of cases, onychomycosis is produced by dermatophytes such as *Trichophyton*, *Microsporum*, and *Epidermophyton* spp.⁷ Distal subungual onychomycosis is caused primarily by *T rubrum*, white superficial onychomycosis is caused mainly by *T menta-*

grophytes, proximal subungual onychomycosis is caused primarily by *T rubrum*, and total involvement of the nail unit is seen only in chronic mucocutaneous candidiasis.⁸

Among nondermatophytes occasionally producing onychomycosis of all types, the most common causative agents are *Scytalidium*, *Fusarium*, *Acremonium*, *Aspergillus*, and *Scopulariopsis* species. Others are even more rare.

Distal Subungual Onychomycosis

Distal subungual onychomycosis (DSO) (Figure 3) is the most common form of onychomycosis. Accounting for about 90% of cases, it is typically a lifelong infection and difficult to treat.^{2,8} Dermatophytes, mainly *T rubrum*, cause more than 99% of cases of DSO. Rarely, a traumatized nail may become infected by species of *Scytalidium* or *Scopulariopsis*, for example. Distal subungual onychomycosis involves primarily the nail bed epidermis. Species of *Scytalidium* produce DSO among residents of tropical areas.

The nail bed infection in DSO caused by *T rubrum* is the result of *T rubrum* spreading from the plantar and palmar surface of the feet or hands. There also seems to be a genetic predisposition with an autosomal dominant pattern to harbor the fungus and develop onychomycotic infections. Distal subungual onychomycosis does not appear to be highly contagious.⁸ Surveys of married couples have shown only occasionally contagion from an infected

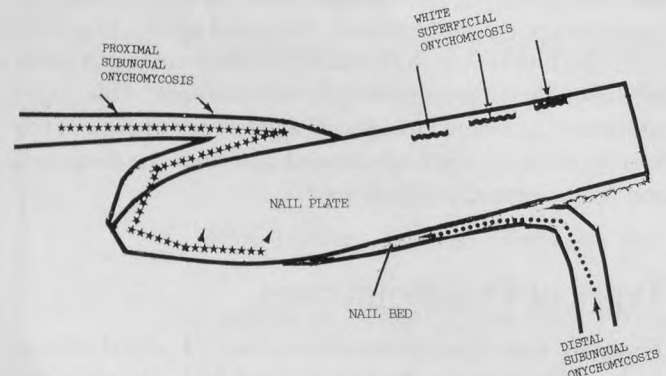


Figure 2. Diagram showing the primary avenues of invasion of the nail unit by dermatophyte fungi and occasionally by other filamentous fungi. Modified from Zaias N. *The Nail in Health and Disease*. New York, NY: Medical and Scientific Books, 1980. Reproduced with permission of the author.

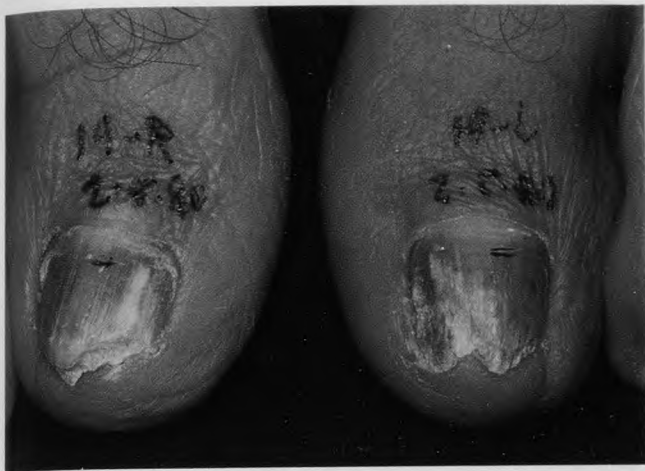

Figure 3. Distal subungual onychomycosis (DSO), the most common form of onychomycosis, which is caused by *T rubrum*, the most prevalent cause of tinea pedis. DSO is primarily, if not exclusively, an infection of the nail bed and not of the nail plate. DSO may affect toenails and fingernails. There is often a concomitant infection of the plantar or palmar skin.

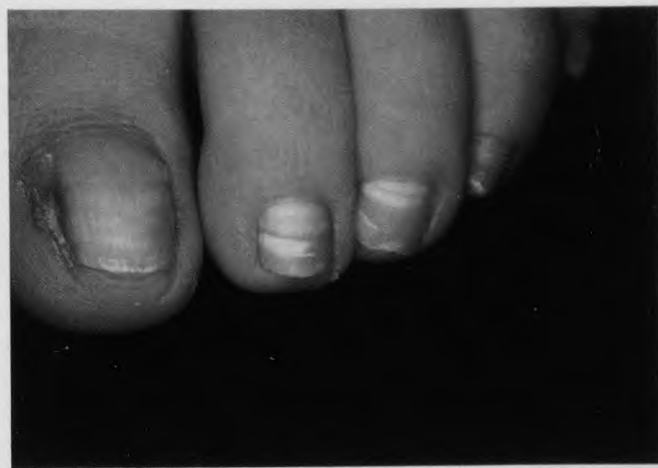

Figure 4. White superficial onychomycosis (WSO) by *T mentagrophytes*. WSO is a shallow infection of the nail plate and is usually present in tinea pedis caused by *T mentagrophytes*. Lesions are sometimes small and easily missed. Other fungi occasionally produce a similar nail infection. In this figure, the great toenail is malformed as the result of trauma, not onychomycosis.

partner to the other partner, despite years of close contact.⁹ While some children apparently acquire the infection from their infected parents, their siblings may not, suggesting that genetic predisposition may be required in addition to personal contact.¹⁰

As the fungal infection progresses from the plantar and palmar skin to the hyponychium of the nail unit, the nail plate remains intact and uninvaded.^{1,8} The fungus produces an inflammatory reaction, resulting in hyperkeratosis and focal parakeratosis, ie, retained nuclei in the stratum corneum. Scale begins to accumulate and raises the nail plate. The fungus advances proximally as the disease progresses. In some patients, the nail plate can be lifted almost to a 45° angle by the excessive horn produced by the diseased nail bed epidermis.

In DSO, nail plate damage is produced primarily by the patient, and iatrogenically by the physician or the podiatrist. The nail plate itself never thickens, but appears thicker due to the adherent subungual nail bed keratosis. Although subungual hyperkeratosis is the most reliable sign of distal subungual onychomycosis, it is not diagnostic because psoriasis and other disorders may mimic this clinical sign.^{1,8}

White Superficial Onychomycosis

White superficial onychomycosis (WSO) (Figure 4) mainly involves the toenails and manifests itself as small, well-defined white spots or white longitudinal streaks on the surface of the nail plate.² The white spots or streaks, which are actually colonies of the organism growing into

the nail surface, may extend or merge, ultimately involving the entire nail surface.⁴ There is only slight penetration of the organisms into the nail plate.⁸ For this reason, WSO can be treated easily and effectively by means of mechanical scraping or topical antifungals or antimicrobials.²

Lesions of WSO may range from minimal to extensive and are part of a syndrome caused by *T mentagrophytes* that includes tinea pedis interdigitalis and vesicular-arch-type tinea pedis. Estimates of prevalence by Zaias¹ for this infection are in the neighborhood of 10%. Non-dermatophyte fungi, such as *Fusarium*, *Acremonium*, and *Aspergillus*, occasionally cause WSO.

Proximal Subungual Onychomycosis

Proximal subungual onychomycosis (PSO) (Figure 5) accounts for less than 1% of onychomycosis cases. It is rare in otherwise healthy adults but often occurs in patients with acquired immunodeficiency syndrome (AIDS) (Figure 3)^{2,3,8} In fact, the presence of PSO is now recognized as a marker for immunodeficient patients.² This type of onychomycosis is caused by a preexisting *T rubrum* tinea pedis that predates immunosuppression. The fungus initially invades the stratum corneum of the proximal nail fold, then penetrates deeper into the nail unit.

Chronic Mucocutaneous Candidiasis

Onychomycosis associated with chronic mucocutaneous candidiasis (CMC) accounts for less than 1% of ony-

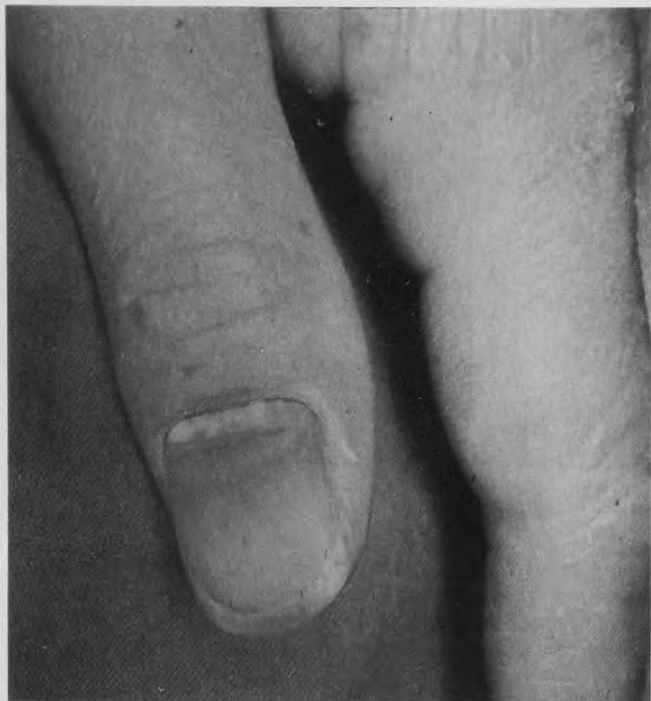


Figure 5. Proximal subungual onychomycosis (PSO) by *T. rubrum* in a patient with acquired immunodeficiency syndrome (AIDS). PSO is a sign of immunodeficiency.

chomycosis cases. Invasion of the nail by *Candida albicans* is rare^{1,8} but can occur in patients with CMC. Most commonly, the organism originates in the intestinal tract and spreads from the mouth to the hand, eventually affecting the nail plate, nail bed, and nail fold.² The nail plate becomes thickened, develops white streaks, and is invaded distally through its entire thickness. Subsequently, the big toe, distal phalanx of the thumb, and other fingers may swell distally, followed eventually by disintegration of the nail plate.

Diagnosis of Onychomycosis

About 50% of cases that initially appear to be onychomycosis prove, on closer scrutiny, to be other types of nail disorders. Many other disorders, particularly psoriasis, have a similar appearance to that of onychomycosis and must be excluded before treatment is initiated.^{4,9} Certain kinds of nail trauma also may be mistaken for onychomycosis. The diagnosis of onychomycosis must be confirmed by (1) identification of fungal hyphae in potassium hydroxide (KOH) preparation of a scraping from the area of affected nail bed keratosis, and (2) growth of fungus on culture in a suitable medium.

When obtaining material for KOH preparation, a small well-selected scraping is preferable to a large ran-

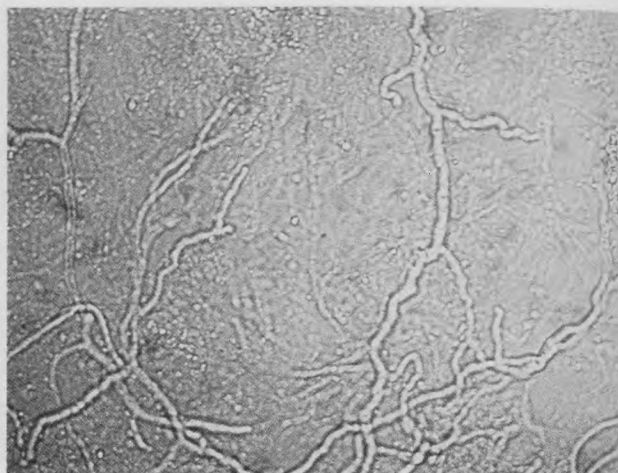


Figure 6. Fungus hyphae seen in a potassium hydroxide wet mount of a nail scraping. Note the refractile branching filaments that are diagnostic of the presence of a dermatophyte or other filamentous fungi.

dom scraping or piece of nail. In DSO, scrapings should be taken from the nail bed. In WSO, scrapings should be taken from the surface of the nail plate. The scrapings should be mixed with a small drop of 20% KOH, preferably containing 40% dimethyl sulfoxide (DMSO). KOH with DMSO (eg, Delasco, Vertex) is readily available from most dermatologic medical supply companies for approximately \$10 per 1 oz bottle. KOH with DMSO quickly clears (makes transparent) the stratum corneum cells, permitting the fungus to be seen as refractile septate hyphae. No warming of the slide is required if the solution contains DMSO (Figure 6).

Culture can be performed using various modifications of Sabouraud's dextrose agar.⁶ A dermatophyte test medium (DTM), which inhibits the growth of bacteria and saprophytic fungi and contains phenol red as a pH indicator, is the simplest to use (Figure 7). Growth is usually seen within 9 days; however, negative cultures are kept for 1 month before discarding, to avoid missing occasional slow-growing isolates. Plain Sabouraud's agar is needed to detect nondermatophyte fungi, such as *Scytalidium*, and *Fusarium*, that cause onychomycosis. These fungi cannot be isolated on DTM or any other modification of Sabouraud's agar containing the antifungal antibiotic cycloheximide.

Currently, the Clinical Laboratory Improvement Act (CLIA) permits office laboratories to conduct moderately complex tests using DTM and to report "presumptive dermatophyte," "yeasts," or "negative" cultures, based on colony type and color change. Reporting of species is not permitted except by CLIA laboratories capable of conducting highly complex tests.

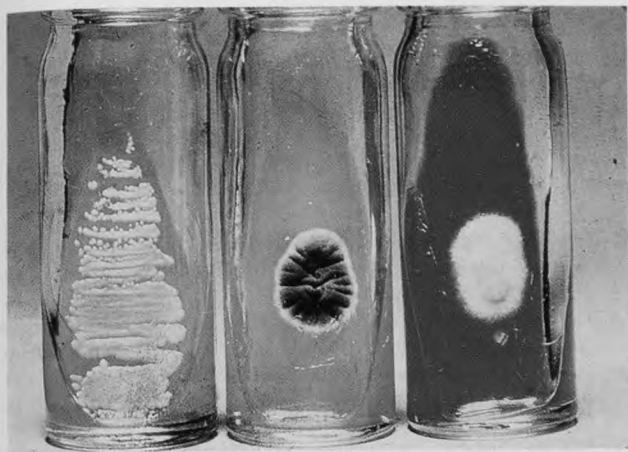


Figure 7. Use of a dermatophyte test medium facilitates the isolation and provisional recognition of dermatophytes and *Candida albicans*. A near-white fungus colony (left) that promptly produces a surrounding zone of red (alkaline pH change in the medium) is usually a dermatophyte. A colony that fails to produce a red color change is rarely a dermatophyte. A colony that is green or black (middle) and may or may not produce a gradual red change in the medium is usually a contaminant mold fungus. A butter-white growth (right) that may or may not produce a gradual red color change is usually a yeast—most often *Candida albicans*. This can be concluded because the cycloheximide in the medium inhibits or slows the growth of most other yeast species. Mucoid or translucent colonies, which may produce a red color change, are bacteria, such as *Pseudomonas*.

Treatment of Onychomycosis

Onychomycosis never resolves spontaneously, and recurrence after treatment is common.⁸ Treating onychomycosis is difficult because of the unique properties of the nail unit. To be effective, an antifungal drug must enter the affected nail tissue (ie, the nail bed in DSO and the nail plate in WSO) and persist there in high concentrations. In the case of many older agents, therapy must be continued until the affected nail grows out. Even after lengthy treatment, however, low cure rates and quick relapse are common with older agents. Griseofulvin, one of the oral drugs currently approved in the United States for onychomycosis, produces cure rates of about 40% (lower for toenail infections) and requires treatment for 12 months or longer.^{1,5,6} Moreover, because griseofulvin induces hepatic enzymes that degrade the agent, high doses are required.¹¹ Oral ketoconazole is not approved for the treatment of onychomycosis but produces cure rates similar to those with griseofulvin.⁸ Ketoconazole treatment has occasionally resulted in hepatic, anti-androgenic, and adrenal dysfunction, making monitoring necessary.¹²

Newer Agents

Of the oral “-azoles,” itraconazole, recently approved for treatment of onychomycosis in the United States, and fluconazole, which is not yet approved for treatment of onychomycosis in the United States, have been shown to be effective in treating a variety of superficial fungal infections; however, experience with oral fluconazole to treat onychomycosis has been limited. Both oral itraconazole and terbinafine have been shown to be more effective than griseofulvin in the treatment of onychomycosis.¹¹ Both produce mycological and clinical cure in more than 70% of patients.

The newer antifungal agents have in common the potential to be used in intermittent treatment schedules. Many such studies are currently in progress to test such dosage regimens. Generally, these intermittent schedules specify that a given dose be taken for 1 week of every month. Another treatment option is 3 or 4 months of daily dosing. This is shorter than the classic 12-month therapy often needed for the older drugs. The shorter regimens of the newer drugs are possible, in part, because of the keratophilic properties of these agents.

Terbinafine may have an advantage over griseofulvin and the “-azole” agents in that it is fungicidal rather than fungistatic. This characteristic allows for shorter treatment periods, resulting in better compliance and possibly fewer side effects, higher mycologic cure rates, and fewer relapses.^{13,14}

Oral terbinafine has also been tested as a treatment for onychomycosis produced by nondermatophytes, such as the yeasts *C albicans* and *Candida parapsilosis* and the mold *Scopulariopsis brevicaulis*.¹⁵ Terbinafine proved fungicidal against *C parapsilosis*, with an 85% cure rate for fingernails and 68% for toenails.¹⁶

Relapse rates appear to be low with oral terbinafine. In one multicenter study, 90.9% of infected toenails and 85.7% of infected fingernails remained cured 6 months after treatment.¹⁷

Itraconazole and other “-azoles” may also achieve cure rates similar to those of terbinafine by increasing the dose used in the intermittent schedule.

Response to any of these oral therapies can be assessed using the method proposed by Zaias and Drachman,¹⁸ in which a small groove is cut into the nail between the normal and affected areas. If the antifungal agent is working, monthly evaluations should reveal continued growth of normal nail with no expansion of the diseased area proximal to the groove. Nail growth varies among healthy individuals but should be between 1.5 to 2 mm per month for large toenails and 3 to 4 mm per month for fingernails.

Cost Considerations

In Europe and Canada, griseofulvin, ketoconazole, itraconazole, and terbinafine are all used in the systematic treatment of onychomycosis. The treatment cost-effectiveness with each of these agents has been evaluated using pharmacoeconomic modeling. The evaluations were based on large-scale meta-analyses of published safety and efficiency studies of these agents.^{19,20} Factors considered in the assessment of clinical outcomes included clinical success rates, relapse rates, and frequency of side effects. Factors considered in the economic analysis included the cost of drug acquisition, drug administration, routine medical care, laboratory tests, and management of adverse reactions. Overall, oral terbinafine was found to be the most cost-effective agent studied.^{19,20} Although this drug had the highest acquisition cost, the expected cost of therapy with terbinafine was lowest because of the short treatment regimen and high efficacy rates. Oral terbinafine was also found to produce the greatest number of disease-free days.¹⁹

Conclusions

Onychomycosis is a fungal infection of the toenails or fingernails. There are four clinical types of the disease, each with a unique presentation and pattern of invasion. Distal subungual onychomycosis is the most common type, accounting for approximately 90% of all cases of onychomycosis. More than 99% of the cases of this type of onychomycosis are caused by dermatophytes, primarily *T rubrum*. Dermatophytes are also the primary causative agents in white superficial onychomycosis and proximal subungual onychomycosis. Onychomycosis associated with chronic mucocutaneous candidiasis is rare, accounting for less than 1% of all cases of onychomycosis. Treatment of onychomycosis, especially of the toenails, has traditionally been difficult. Oral griseofulvin requires a lengthy treatment regimen and produces low cure rates. Use of oral ketoconazole has potentially serious safety risks, primarily hepatotoxicity. Both of these therapies are associated with high relapse rates. New oral agents, particularly oral itraconazole and oral terbinafine, appear to produce high mycologic cure rates with short treatment regimens. Use of terbinafine, the only agent that is fungicidal against dermatophytes, may result in higher cure rates, shorter treatment periods, and fewer relapses.

Acknowledgment

This research was supported by an educational grant from Sandoz Pharmaceutical Corporation.

References

1. Zaias N. Onychomycosis. *Arch Dermatol* 1972; 105:263-74.
2. Zaias N. Clinical manifestation of onychomycosis. *Clin Exp Dermatol* 1992; 17(suppl 1):6-9.
3. Domp Martin D, Domp Martin A, Dell AM, Grosshans E, Couland JP. Onychomycosis and AIDS: clinical and laboratory findings in 62 patients. *Int J Dermatol* 1990; 29:337-9.
4. Andre J, Achten G. Onychomycosis. *Int J Dermatol* 1987; 26:481-90.
5. Hay RJ. Onychomycosis: agents of choice. *Dermatol Clin* 1993; 11: 161-9.
6. Elewski BE. Cutaneous fungal infections. New York, NY: Igak-Shoin, 1992:117-20.
7. Summerbell RC, Kane J, Kraiden S. Onychomycosis, tinea pedis and tinea manuum caused by non-dermatophytic filamentous fungi. *Mycoses* 1989; 32:609-19.
8. Zaias N. Onychomycosis. *Dermatol Clin* 1985; 3:445-60.
9. Rippon JW. Cutaneous infections: dermatophytosis and dermatomycosis. In: *Medical mycology: the pathogenic fungi and the pathogenic actinomycetes*. 3rd ed. Philadelphia, Pa: WB Saunders Company, 1988:169-275.
10. Zaias N, Tosti A, Rebell G, et al. Autosomal dominant pattern of distal subungual onychomycosis by *T rubrum*. *J Am Acad Dermatol* 1996; 34:302-4.
11. Roseeuw D, DeDoncker P. New approaches to the treatment of onychomycosis. *J Am Acad Dermatol* 1993; 29(suppl):S45-S50.
12. Zaias N. Management of onychomycosis with oral terbinafine. *J Am Acad Dermatol* 1990; 23:810-12.
13. Elewski BE. Mechanisms of action of systemic antifungal agents. *J Am Acad Dermatol* 1993; 28(suppl):S28-S34.
14. Clayton YM. Relevance of broad-spectrum and fungicidal activity of antifungals in the treatment of dermatomycoses. *Br J Dermatol* 1994; 130(suppl 43):7-8.
15. Nolting S, Brautigam M, Weidinger G. Terbinafine in onychomycosis with involvement by non-dermatophytic fungi. *Br J Dermatol* 1994; 130(suppl 43):16-21.
16. Segal R, Cividalli L, Kritzman A, David M. Treatment of *Candida* nail infection with terbinafine. Presented at the Second Annual International Summit on Cutaneous Antifungal Therapy, November 10-13, 1994, Boston, Mass.
17. Baudraz-Rosselet F, Rakosi T, Wili PB, Kenzelmann R. Treatment of onychomycosis with terbinafine. *Br J Dermatol* 1992; 126(suppl 39):40-6.
18. Zaias N, Drachman D. A method for the determination of drug effectiveness in onychomycosis: trials with ketoconazole and griseofulvin ultramicrosize. *J Am Acad Dermatol* 1983; 9:912-8.
19. Arikian SR, Einarson TR, Kobelt-Nguyen G, Schubert F. A multinational pharmacoeconomic analysis of oral therapies for onychomycosis. *Br J Dermatol* 1994; 130(suppl 43):35-44.
20. Einarson TR, Arikian SR, Shear NH. Cost-effectiveness analysis for onychomycosis therapy in Canada from a government perspective. *Br J Dermatol* 1994; 130(suppl 43):32-4.