

Continuing medical education (CME) credit is awarded upon successful completion of the posttest and evaluation.

**To access the posttest and evaluation, visit**  
[www.worldclasscme.com/imagingofthebreast](http://www.worldclasscme.com/imagingofthebreast)

World Class CME is accredited by the Accreditation Council for Continuing Medical Education to provide continuing medical education for physicians.

World Class CME designates this journal-based CME activity for a maximum of 1.0 *AMA PRA Category 1 Credit*<sup>™</sup>. Physicians should claim only the credit commensurate with the extent of their participation in the activity.

This activity is supported by an educational grant from Hologic, Inc.

**Audience:** This activity was planned for obstetricians and gynecologists and women's health care providers.

#### Faculty

##### Program Director

**Steven R. Goldstein, MD, CCD, NCMP, FACOG**

Professor of Obstetrics and Gynecology  
New York University School of Medicine  
Director of Gynecological Ultrasound  
Co-Director of Bone Densitometry  
Department of Obstetrics and Gynecology  
New York University Medical Center  
New York, New York

##### Authors/Editors

**Reni S. Butler, MD**

Assistant Professor, Diagnostic Radiology  
Yale University  
New Haven, Connecticut

**Bonnie N. Joe, MD, PhD, FSBI**

Professor of Radiology and Biomedical Imaging  
Chief, Breast Imaging  
University of California, San Francisco  
San Francisco, California

**Bruce A. Porter, MD, FACR**

Clinical Associate Professor  
Department of Radiology  
University of Washington School of Medicine  
Seattle, Washington

**Michael J. Ulisse, MD, FACR**

Adjunct Professor of Radiology  
University of Texas  
Health Sciences Center  
San Antonio, Texas  
Breast Diagnostic Centers  
Auburn and Federal Way, Washington

#### Learning Objectives

At the conclusion of this activity, the participant will be able to:

1. Understand tomosynthesis and realize different types of equipment have different scan times, number of views, and clinical trial data.
2. Appreciate who appropriate candidates are for breast MRI as well as potential pitfalls in its use.
3. Understand the current role of breast density and legislative efforts to inform patients.

Date of original release: June 1, 2016

Date credit expires: May 31, 2019

#### Conflict of Interest Disclosure

**Steven R. Goldstein, MD, CCD, NCMP, FACOG**

Consultant: Cook OB/GYN, fees received

#### No Disclosures to Declare

Reni S. Butler, MD; Bonnie N. Joe, MD, PhD, FSBI;  
Bruce A. Porter, MD, FACR; Michael J. Ulisse, MD, FACR;  
Heidi M. Wilson, Course Director

June 2016

# Imaging of the Breast 2016: Reducing the Confusion

## Introduction

**Steven R. Goldstein, MD, CCD, NCMP, FACOG**

New York University School of Medicine  
New York, New York

Until recently, when it was surpassed by lung cancer, breast cancer was the most common malignancy in women, accounting for an estimated 231,840 new cases and 40,290 deaths per year in 2015.<sup>1</sup> For many women, the emotional and psychological ramifications of having breast cancer, or the fear of developing it, is overwhelming. Indeed, in a Gallup poll commissioned by the North American Menopause Society (NAMS), women were asked, "What is the most common cause of death?" Fully 40% responded "breast cancer." At that time breast cancer actually had a 4% mortality rate, while cardiovascular disease accounted for 45% of all mortality. More recently, 1 in 31 American women dies from breast cancer each year, while 1 in 3 dies of heart disease.<sup>2</sup>

Thus, fear of breast cancer is a very important health concern for many women. As gynecologists and health care providers who concentrate on women's health, we are the frontline clinicians tasked with maximizing our patients' breast health. Such care includes taking a patient's pertinent family and personal history and being well versed in the risk factors for breast cancer and their relative increases in risk (TABLE). Of course, it is essential for us to ensure that patients understand the important difference between relative risk and absolute risk. Counseling patients to manage modifiable risk factors, such as obesity, smoking, and excessive alcohol intake, is also critical. Furthermore, clinicians need to be up to date on agents approved by the US Food and Drug Administration (FDA) for chemoprevention in appropriate candidates.

Early detection of breast cancer, however, is truly one of the most important ways to reduce the morbidity and mortality of this disease. In the excellent article that follows by Dr. Bonnie Joe, we learn that only after the intro-

**TABLE Breast Cancer Risk Factors and Their Relative Risks**

Relative risk <2	Relative risk 2-4	Relative risk >4
Age 25 to 34 at first live birth	Age >35 at first live birth	Gene mutations (BRCA 1 or 2)
Early menarche	First-degree relative with breast cancer	Lobular carcinoma in situ
Late menopause	Nulliparity	Ductal carcinoma in situ
Proliferative benign disease	Radiation exposure	Atypical hyperplasia
Postmenopausal obesity	Prior breast cancer	
Alcohol use		
Estrogen/progestogen hormone therapy		

Adapted from: Bilimoria MM, Morrow M. The woman at increased risk for breast cancer: evaluation and management strategies. *CA Cancer J Clin.* 1995;45:263-278.

duction of mammographic screening in the mid-1980s did we finally see a 30% reduction in mortality from breast cancer. As health care providers for women, we prescribe mammography screening and, often, follow-up studies, and we serve as a reliable resource for how often and how best to do surveillance, thus promoting early detection

while maintaining an appropriate risk (false-positives)/benefit (true-positives) ratio.

The landscape has become quite murky. Professional society recommendations for breast cancer screening vary. Many new screening modalities have become available, including magnetic resonance imaging (MRI) and tomosynthesis. Great confusion exists about breast density, especially in the 24 states that have legislative mandates to inform patients of their personal level of breast density. Many patients, and even many health care providers, do not realize that tomosynthesis is 3D mammography, not to mention what it is capable of doing (and not doing). Even among clinicians who do understand tomosynthesis, few realize that instruments from various manufacturers have very real differences that may impact the quality and performance of the study.

As program director of this continuing medical education (CME) supplement, I have assembled a team of imaging experts who, in the pages that follow, help sort through the confusion. They provide data on the merits of screening, the role of tomosynthesis (including its advantages and the differences in various instruments employed for it), how best to approach breast density, and the role of MRI.

**REFERENCES**

1. National Cancer Institute Surveillance, Epidemiology, and End Results Program. SEER Stat Fact Sheets: female breast cancer. <http://seer.cancer.gov/statfacts/html/breast.html>. Accessed February 22, 2016.
2. Centers for Disease Control and Prevention. Heart Disease Facts. [www.cdc.gov/heartdisease/facts.htm](http://www.cdc.gov/heartdisease/facts.htm). Updated August 10, 2015. Accessed April 18, 2016.

## Breast cancer demographics and screening guidelines

**Bonnie N. Joe, MD, PhD, FSBI**

University of California, San Francisco  
San Francisco, California

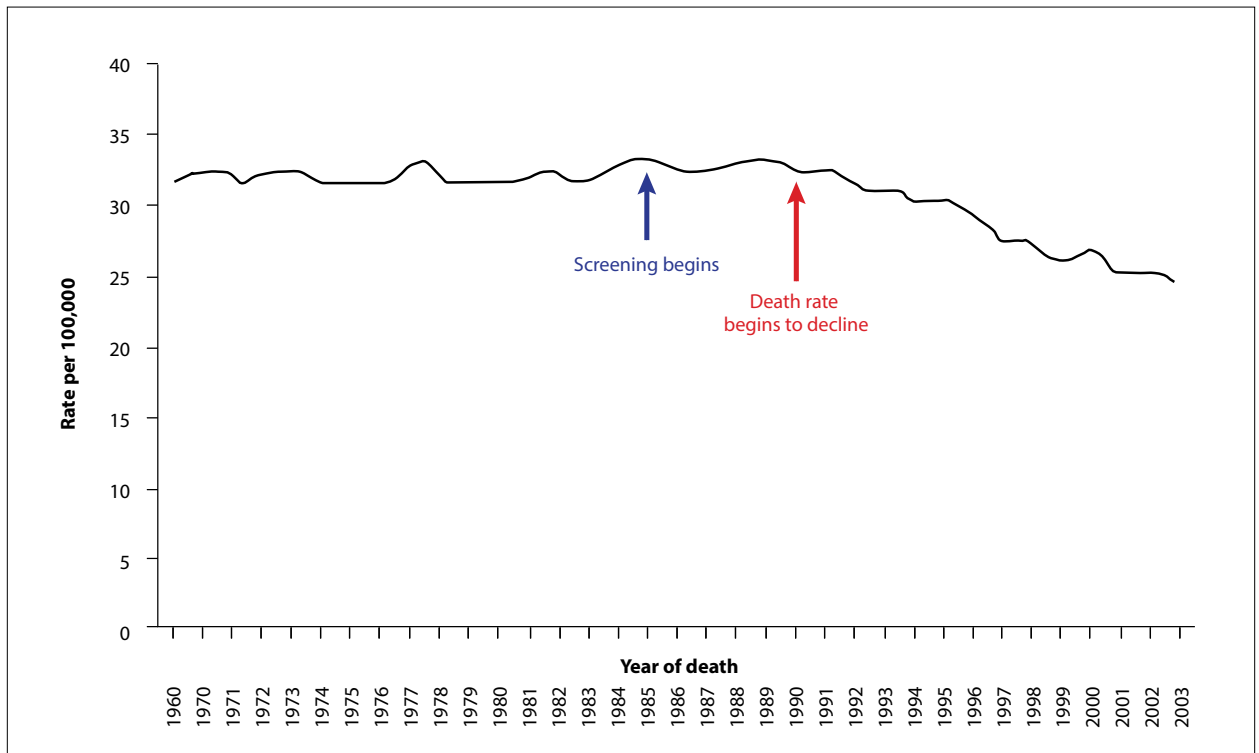
**R**ecent guideline updates from the American Cancer Society and the US Preventive Services Task Force (USPSTF) have unfortunately misled many to believe that screening mammography is not effective for women aged 40 to 49 years and that biennial screening is preferred over annual screening to reduce false-positive recalls.<sup>1,2</sup> It is critically important to point out that choosing biennial screening over annual screening or choosing to begin screening at age 50 will reduce false-positive recalls—but at the cost of sacrificing lives to breast cancer.<sup>3</sup>

Randomized controlled trials (RCTs) have consistently demonstrated an 18% to 29% mortality reduction related to screening women in the age range of 40 to 49 years.<sup>4</sup> Remember that RCTs underestimate the lifesaving benefit of screening due to issues with nonadherence and con-

tamination between the groups invited to screen versus those not invited. A better measure of screening mammography would be to compare women who actually undergo screening mammography with those who do not. Analysis of population service screening data provides such measures.

Population service screening studies, which represent how mammography screening performs in the “real world,” demonstrate the benefit of screening mammography to reduce mortality up to 50%.<sup>5</sup> According to data from the Surveillance, Epidemiology, and End Results (SEER) program, the breast cancer death rate was unchanged for decades. With the introduction of screening mammography, the death rate gradually declined to about 30% by 2005 (FIGURE).<sup>6</sup>

**FIGURE** The breast cancer death rate has decreased in relationship to mammography screening



The death rate for breast cancer was unchanged for decades until mammography screening began in the mid-1980s. Soon after, the death rate began to decrease, and it has continued to decrease as more and more women participate in screening. By 2005 it was down by 30%.<sup>6</sup>

Reprinted from *Radiologic Clinics of North America*, 48/5, Kopans, D, The 2009 US Preventive Services Task Force (USPSTF) Guidelines are not Supported by Science: The Scientific Support for Mammography Screening, p.843-857, 2010 with permission from Elsevier.

None of the parameters of screening—recall rates, biopsy rates, cancer detection rates—change suddenly at age 50.<sup>7</sup> Asking only women at high risk for breast cancer to screen starting at age 40 ignores the fact that 75% of breast cancers are diagnosed in women with no identifiable risk factors.

A study of 40- to 49-year-old women with screen-detected breast cancer found that the majority had neither strong family history nor dense breast tissue.<sup>8</sup> An analysis by Hendrick and Helvie, using the USPSTF 2009 methodology, showed that if women aged 40 to 49 years are not screened, and those aged 50 to 74 are screened biennially, approximately 6500 additional women in the United States would die each year from breast cancer—a population of women who have the most years to live in terms of personal and family milestones they will miss if not given the opportunity for early detection.<sup>3</sup> In fact, all of the Cancer Intervention and Surveillance Modeling Network (CISNET) models used by the USPSTF and the ACS show that the most lives are saved by annual screening starting at age 40.<sup>9</sup>

When cancers are detected on mammography before

they spread to other parts of the body, the likelihood of cure is increased. Annual screening mammography in 40- to 49-year-old women not only saves lives but also results in the detection of smaller tumors, resulting in less aggressive surgery, possible avoidance of radiation therapy, and elimination of the need for expensive and toxic chemotherapy.<sup>10-12</sup>

#### REFERENCES

1. Siu AL; US Preventive Services Task Force. Screening for breast cancer: US Preventive Services Task Force Recommendation Statement. *Ann Intern Med*. 2016;164(4):279-296.
2. Oeffinger KC, Fontham ET, Etzioni R, et al; American Cancer Society. Breast cancer screening for women at average risk: 2015 guideline update from the American Cancer Society. *JAMA*. 2015;314(15):1599-1614.
3. Hendrick RE, Helvie MA. United States Preventive Services Task Force screening mammography recommendations: science ignored. *AJR Am J Roentgenol*. 2011;196(2):W112-W116.
4. Shapiro S. Screening: assessment of current studies. *Cancer*. 1994; 74(1 suppl):231-238.
5. Newell M, Eby PR. Benefits of screening mammography: data from population service screening. *Society of Breast Imaging News*. 2015;(4):4-5. <http://tigerlilyfoundation.org/wp-content/uploads/2015/11/The-Member-Newsletter-of-the-Society-of-Breast-Imaging-2015-Issue-4.pdf>. Accessed March 31, 2016.
6. Kopans DB. The 2009 US Preventive Services Task Force (USPSTF) guidelines are not supported by science: the scientific support for mammography screening. *Radiol Clin North Am*. 2010;48(5):843-857.

7. Kopans DB, Moore RH, McCarthy KA, et al. Biasing the interpretation of mammography screening data by age grouping: nothing changes abruptly at age 50. *Breast J*. 1998;4(3):139-145.
8. Price ER, Keedy AW, Gidwaney R, Sickles EA, Joe BN. The potential impact of risk-based screening mammography in women 40-49 years old. *AJR Am J Roentgenol*. 2015;205(6):1360-1364.
9. Mandelblatt JS, Cronin KA, Bailey S, et al; Breast Cancer Working Group of the Cancer Intervention and Surveillance Monitoring Network. Effects of mammography screening under different screening schedules: model estimates of potential benefits and harms. *Ann Intern Med*. 2009;151(10):738-747.
10. Shen N, Hammonds LS, Madsen D, Dale P. Mammography in 40-year-old women: what difference does it make? The potential impact of the US Preventative Services Task Force (USPSTF) mammography guidelines. *Ann Surg Oncol*. 2011;18(11):3066-3071.
11. Plecha D, Salem N, Kremer M, et al. Neglecting to screen women between 40 and 49 years old with mammography: what is the impact on treatment morbidity and potential risk reduction? *AJR Am J Roentgenol*. 2014;202(2):282-288.
12. Miglioretti DL, Zhu W, Kerlikowske K, et al; Breast Cancer Surveillance Consortium. Breast tumor prognostic characteristics and biennial vs annual mammography, age, and menopausal status. *JAMA Oncol*. 2015;1(8):1069-1077.

## Tomosynthesis: What is it, and are all systems equal?

**Reni S. Butler, MD**

Yale University, Yale School of Medicine  
New Haven, Connecticut

### The technology

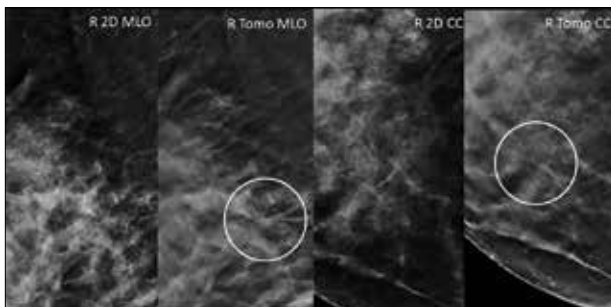
Digital breast tomosynthesis offers cross-sectional imaging of thin sections of the breast. Although 2-dimensional (2D) screening mammography is proven to reduce breast cancer mortality, its sensitivity and specificity are limited by the masking effect of overlapping breast tissue. Three-dimensional (3D) tomosynthesis compensates for this. It helps us detect malignant lesions that may be obscured by the overlapping breast tissue on standard digital mammography, and it can increase specificity by resolving pseudolesions produced by breast tissue overlap, reducing the so-called false-positives (**FIGURE**).

Two-dimensional and tomosynthesis data are obtained in a single compression, adding a variable number of seconds to the acquisition of each view depending on the system (see vendor information on the following page). Once the patient is positioned, the x-ray tube sweeps through an arc over the breast and acquires a predetermined number of projection images that are subsequently reconstructed into 1-mm sections. After the sweep, the x-ray tube returns to its starting position perpendicular to the image receptor and obtains a conventional 2D image. While the additional exposure increases the radiation dose, it still remains below the 3 mGy safety limit of the US Food and Drug Administration (FDA). If the vendor provides the option of creating a synthetic mammogram (currently called a C-view), the 2D acquisition can be eliminated. The standard mammogram image is reverse engineered from the 3D tomosynthesis data, thereby significantly reducing the radiation exposure to a level comparable to that of a conventional 2D mammogram.

### The vendors

Four major vendors have developed digital breast tomosynthesis systems; each has slight variations in detectors, technical parameters of the tomosynthesis acquisition,

**FIGURE** Two-dimensional mammographic images compared with tomosynthesis images



Screening mammogram in a 56-year-old woman shows an irregularity in the right breast seen only on tomosynthesis images. Surgical pathology showed grade 1-2 invasive ductal carcinoma.

Abbreviations: CC, top projection; MLO, mediolateral oblique projection.  
Images courtesy of Reni S. Butler, MD.

and resolution of 2D and tomosynthesis images (**TABLE**). Systems by Hologic, Siemens, and GE are FDA approved for clinical use in the United States, while the Fujifilm system is currently undergoing trials. At this time, the only available synthetic mammogram is the C-view from Hologic, which is FDA approved to be used in place of a conventional 2D mammogram when paired with tomosynthesis, again reducing the overall dose to the woman.

### The data

Multiple clinical trials in the United States and Europe have shown significant gains in breast cancer detection as well as a marked decline in false-positive recalls when using tomosynthesis in the screening environment.<sup>1-3</sup> The additional cancers detected are predominantly small invasive cancers whose early detection is likely to positively influence patient outcomes. In addition, tomosynthesis

**TABLE** Comparison of technical and clinical features of digital breast tomosynthesis systems developed to date

Vendor	Platform	3D acquisition			Resolution		
		Detector	X-ray arc sweep	Projection images	Acquisition time	2D pixel size	Tomo pixel size
Hologic	Amorphous selenium	15°	15	4 sec	70 μ	95 μ/117 μ <sup>a</sup>	C-view, FDA approved
Siemens	Amorphous selenium	50°	25	30 sec	85 μ	85 μ	N/A
GE	Amorphous silicon	25°	9	10 sec	100 μ	100 μ	N/A
Fujifilm	Amorphous selenium	15° (ST) <sup>b</sup>	15 (ST)	4 sec (ST)	50 μ	100 μ (ST)	N/A
		45° (HR) <sup>c</sup>	15 (HR)	11 sec (HR)		50 μ (HR)	

Selenium gives better resolution with faster acquisition, both benefiting the patient. A greater number of projection images produce a higher-resolution tomosynthesis image with smaller pixel size. However, this needs to be balanced against a longer acquisition time, which increases the likelihood of motion.

<sup>a</sup>Reconstructed tomosynthesis pixel size for Hologic Selenia Dimensions depends on paddle size, with 2 paddle sizes available.

<sup>b</sup>Standard mode of Fujifilm Amulet Innovality digital mammography system; recommended for screening mammography.

<sup>c</sup>High-resolution mode of Fujifilm Amulet Innovality digital mammography system; recommended for diagnostic mammography.

Abbreviations: HR, high resolution; N/A, not applicable; ST, standard; Tomo, tomosynthesis.

has been shown to aid in the detection of invasive lobular carcinoma, a histology that has been sometimes difficult to diagnose at an early stage due to its tendency to present with subtle findings.<sup>3</sup>

In the diagnostic setting, tomosynthesis has led to a marked shortening of the diagnostic workup and a greater diagnostic confidence, resulting in fewer Breast Imaging Reporting and Data System (BI-RADS) 3 assessments and a higher positive predictive value for BI-RADS 4 and BI-RADS 5 cases.<sup>4-6</sup> By minimizing the masking effect of overlying breast tissue, tomosynthesis improves visualization of important lesion features, such as mass margins, which help determine the probability of malignancy. The added information gained from routine mediolateral oblique and craniocaudal views often obviates the need for spot compression and other diagnostic views.

Further technological innovations, such as high-resolution synthetic 2D mammograms and computer-aided detection for tomosynthesis, may continue to

improve the accuracy and efficiency of both mammographic screening and diagnosis.

#### REFERENCES

1. Skaane P, Bandos A, Gullien R, et al. Comparison of digital mammography alone and digital mammography plus tomosynthesis in a population-based screening program. *Radiology*. 2013;267(1):47-56.
2. Friedewald SM, Rafferty EA, Rose SL, et al. Breast cancer screening using tomosynthesis in combination with digital mammography. *JAMA*. 2014;311(24):2499-2507.
3. Dang P, Humphrey K, Freer P, Rafferty E. ILC on tomosynthesis: now you can see it! Paper presented at: Radiological Society of North America 2013 Scientific Assembly and Annual Meeting; December 1-6, 2013; Chicago, IL.
4. Zuley M, Bandos AI, Ganott MA, et al. Digital breast tomosynthesis versus supplemental diagnostic mammographic views for evaluation of noncalcified breast lesions. *Radiology*. 2013;266(1):89-95.
5. Brandt KR, Craig DA, Hoskins TL, et al. Can digital breast tomosynthesis replace conventional diagnostic mammography views for screening recalls without calcifications? A comparison study in a simulated clinical setting. *AJR Am J Roentgen*. 2013;200(2):291-298.
6. Butler R, Kalra V, Geisel J, Crenshaw J, Philpotts L. Tomosynthesis in diagnostic mammography—continued change after three years of experience. Paper presented at: Radiological Society of North America 2015 Scientific Assembly and Annual Meeting; November 29–December 4, 2015; Chicago, IL.



## Dense breast screening: Ultrasound, tomosynthesis, or MRI?

**Reni S. Butler, MD**

Yale University, Yale School of Medicine  
New Haven, Connecticut

**R**ecent legislation has propelled the issue of mammographic breast density to the forefront of public attention. Currently, 24 states have breast density reporting laws, and last year a bill titled, the “Breast Density and Mammography Reporting Act of 2015” was introduced in the House and Senate to establish a federal standard for breast density notification.

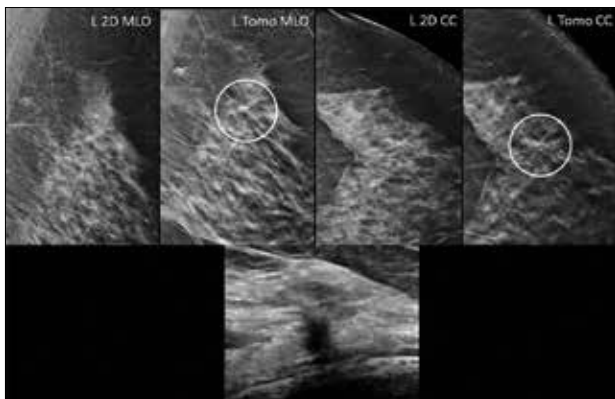
The advocacy for breast density legislation stems from 2 concerns. First, dense breast tissue represents an independent risk factor for the development of breast cancer. This risk has been reported as 4 to 6 times greater than that for women with nondense breasts.<sup>1</sup> The second and perhaps even more significant concern regarding dense breasts is the marked decrease in mammographic sensitivity associated with increasing breast density.<sup>2</sup> From as high as 80% to 98% in entirely fatty breasts, mammographic sensitivity plummets to 30% to 64.4% at the opposite end of the spectrum in women with extremely dense breasts.

Ultrasound, which is not limited by radiographic density, can detect many of these mammographically occult

cancers. Multiple studies in women with dense breasts have reported that ultrasound detects an additional 2.7 to 4.6 cancers per 1000 women screened with mammography.<sup>3,4</sup> However, this additional breast cancer detection comes with significant cost. In the first year of implementing screening ultrasound in Connecticut, an additional 3 cancers were detected in a patient population of 935 women at a cost of \$60,267 per each additional cancer.<sup>4</sup> Concerns over this high cost have challenged experts to consider whether all women with dense breasts require additional screening and how modalities other than ultrasound fit into the screening paradigm.

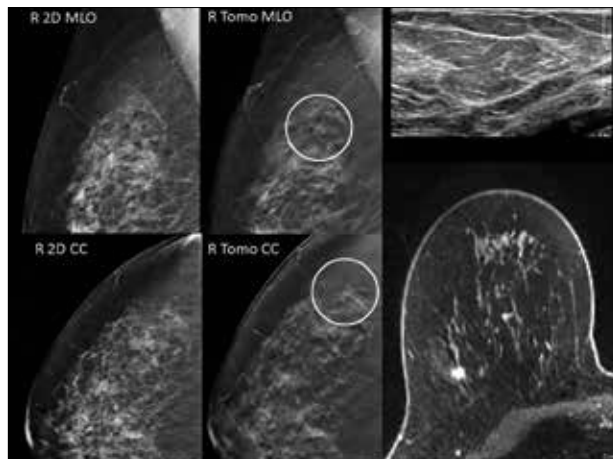
The decision to pursue supplemental screening should be based on an informed discussion of the patient’s individual breast density and cancer risk, as well as an understanding of the likelihood of detecting a mammo-

**FIGURE 1** Breast cancer occult on two-dimensional mammography revealed by tomosynthesis



Screening mammogram in a 54-year-old woman shows a small irregularity seen only on tomosynthesis images. Ultrasound reveals a sonographic correlate, and biopsy yields diagnosis of grade 2 invasive ductal carcinoma. This finding, which might have been considered mammographically occult in years prior to tomosynthesis, is now a tomosynthesis-detected cancer. Abbreviations: CC, top projection; MLO, mediolateral oblique projection. Images courtesy of Reni S. Butler, MD.

**FIGURE 2** Role of MRI in tomosynthesis-detected breast cancer not seen in two-dimensional images or ultrasound



Screening mammogram in a 49-year-old woman clearly reveals an irregularity in the right superior lateral breast seen only on tomosynthesis images. Ultrasound was negative. Contrast-enhanced MRI demonstrates a small spiculated mass corresponding to the mammographic finding, which biopsy showed to represent a grade 2 invasive ductal carcinoma with DCIS. In this patient, screening with 2D mammography and ultrasound would not have detected the cancer without the use of tomosynthesis.

Abbreviations: 2D, 2 dimensional; CC, top projection; DCIS, ductal carcinoma in situ; MLO, mediolateral oblique projection; MRI, magnetic resonance imaging. Images courtesy of Reni S. Butler, MD.

graphically occult cancer versus false-positive findings that may lead to anxiety, follow-up imaging, and biopsy. For patients with a lifetime risk >20%, magnetic resonance imaging (MRI) is the modality of choice for screening in conjunction with mammography and is recommended regardless of breast tissue density.<sup>5</sup> Patients with a lifetime risk between 15% and 20% fall into an intermediate category for which the guidelines recommend neither for nor against MRI. In these patients, both MRI and ultrasound may be suitable options. Finally, for patients at average lifetime risk <15%, MRI is not recommended and ultrasound may be considered if the patient has dense breasts.

In patients at average risk, tomosynthesis may diminish the role of ultrasound as an adjunctive screening test. Clinical trials have shown that tomosynthesis improves breast cancer detection.<sup>6</sup> By removing the masking effect of superimposed breast tissue, tomosynthesis unveils cancers that would have been deemed mammographically occult on conventional 2-dimensional (2D) mammography, leaving fewer cancers to be detected by ultrasound alone. The cost effectiveness and cancer detection rate of screening ultrasound is, therefore, likely to be diminished. Little data comparing the benefit of tomosynthesis versus screening ultrasound in women with dense breasts is currently available. However, growing clinical experience with

tomosynthesis reveals cancers occult on 2D mammography whose detection no longer requires screening ultrasound (**FIGURE 1**).

Less commonly, some cancers detected with tomosynthesis may even be ultrasound occult (**FIGURE 2**). In a small percentage of patients, screening ultrasound is likely to remain useful. However, as tomosynthesis becomes more widely available, ultrasound may be used more selectively to screen patients at higher-than-average breast cancer risk.

#### REFERENCES

1. Yaghjian L, Colditz GA, Rosner B, Tamimi RM. Mammographic breast density and breast cancer risk by menopausal status, postmenopausal hormone use and a family history of breast cancer. *Cancer Causes Control*. 2012;23(5):785-790.
2. Carney PA, Miglioretti DL, Yankaskas BC, et al. Individual and combined effects of age, breast density, and hormone replacement therapy use on the accuracy of screening mammography. *Ann Intern Med*. 2003;138(3):168-175.
3. Berg WA, Blume JD, Cormack JB, et al; ACRIN 6666 Investigators. Combined screening with ultrasound and mammography vs mammography alone in women at elevated risk of breast cancer. *JAMA*. 2008;299(18):2151-2163.
4. Hooley RJ, Greenberg KL, Stackhouse RM, Geisel JL, Butler RS, Philpotts LE. Screening US in patients with mammographically dense breasts: initial experience with Connecticut Public Act 09-41. *Radiology*. 2012;265(1):59-69.
5. Saslow D, Boetes C, Burke W, et al. American Cancer Society guidelines for breast screening with MRI as an adjunct to mammography. *CA Cancer J Clin*. 2007;57(2):75-89.
6. Skaane P, Bandos AI, Gullien R, et al. Comparison of digital mammography alone and digital mammography plus tomosynthesis in a population-based screening program. *Radiology*. 2013;267(1):47-56.

## Current best indications for breast MRI

**Bruce A. Porter, MD, FACP**

University of Washington, School of Medicine  
Seattle, Washington

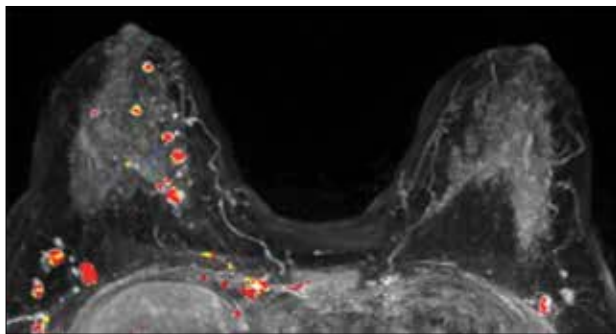
**A**ccepted indications for magnetic resonance imaging (MRI) of the breast in high-risk breast cancer (BRCA) surveillance are evolving, variable, and often disputed. Although MRI is not indicated in women at average risk for breast cancer, one application is especially clear: MRI is an appropriate adjunct to mammography in women at high risk for breast cancer.<sup>1</sup> Its efficacy when used with mammography is well established.<sup>2</sup> Based strictly on the American Cancer Society recommendations, the current best indications for breast MRI are<sup>1</sup>:

- BRCA mutation carriers and their first-degree relatives who are untested
- Prior chest radiation (eg, Hodgkin lymphoma treatment)
- >20% to 25% lifetime risk for breast cancer (by risk-assessment model)
- Congenital cancer predisposition syndromes (Li-Fraumeni syndrome, Cowden syndrome, Bannayan-Riley-Ruvalcaba syndrome)

Recommended imaging in these patients generally starts at age 30, with some exceptions (such as congenital syndromes), and continues as long as the woman is in good health. MRI and mammography should be alternated at 6-month intervals. The recommended risk-assessment models are the Tyrer-Cuzick ([www.ems-trials.org/risk-evaluator](http://www.ems-trials.org/risk-evaluator)) and Claus (<http://www4.utsouthwestern.edu/breasthealth/cagene/default.asp>) models; the Gail model is specifically not recommended since it does not include family history. Ideally, these women should be assessed and monitored in an approved high-risk clinic or facility. MRI should be performed in an American College of Radiology accredited facility ([www.acr.org](http://www.acr.org)), and MRI-guided biopsy must be available.

There are other promising indications for MRI, but they are controversial and are not yet considered appropriate (due to lesser risk): preoperative staging for unsuspected multicentric tumors (**FIGURE 1**), as well as diffuse or contralateral cancer, lobular histology, and monitoring of

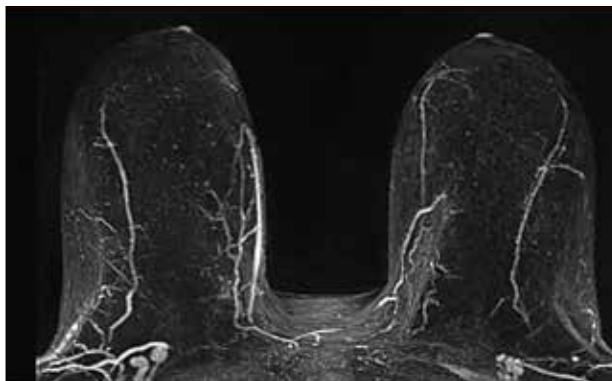
**FIGURE 1** Unsuspected multicentric infiltrating ductal cancers (red lesions on CAD)



This patient was thought to have a solitary 1.3-cm ductal cancer prior to MRI; at mastectomy, multiple cancers were confirmed. Abbreviations: CAD, computer-aided detection; MR, magnetic resonance imaging.

Image courtesy of Bruce A. Porter, MD, FACR.

**FIGURE 2** Normal contrast-enhanced breast MR, MR-BI-RADS 1



Abbreviations: MR, magnetic resonance; MR-BI-RADS, Breast Imaging Reporting and Data System.

Image courtesy of Bruce A. Porter, MD, FACR.

neoadjuvant chemotherapy, among others. MRI's key contribution in high-risk surveillance is, however, the very high (approximately 99%) negative predictive value of a normal exam (FIGURE 2), even in a high-risk population.<sup>3</sup>

Concerns are often raised regarding the potential for false-positive breast MRI exams leading to anxiety and more biopsies. This is true and more likely in less experienced imaging facilities, but it is important to recognize that the harm-risk/benefit ratio is significantly less in high-risk populations due to a greater probability of cancer and the potential benefits of earlier detection and lower stage at diagnosis when MRI and mammography are used in conjunction. This combined approach has been demonstrated to improve mortality in these selected patients.<sup>4</sup> Exclusion or detection of unsuspected contralateral cancer is also beneficial.<sup>5</sup>

In summary, a combined mammography and MRI approach to ongoing surveillance of women at appropriately established high-risk for breast cancer is effective in early diagnosis or near-exclusion of breast cancer in these

selected patients. Although there is a higher probability of false-positive results than with mammography alone, the risk/benefit ratio in these patients makes this an acceptable and appropriate clinical alternative for these at-risk women.

#### REFERENCES

1. Saslow D, Boetes C, Burke W, et al; American Cancer Society Breast Cancer Advisory Group. American Cancer Society Guidelines for breast screening with MRI as an adjunct to mammography. *CA Cancer J Clin.* 2007;57(2):75-79.
2. Kriege M, Brekelmans CT, Boetes C, et al; Magnetic Resonance Imaging Screening Study Group. Efficacy of MRI and mammography for breast-cancer screening in women with a familial or genetic predisposition. *N Engl J Med.* 2004;351(5):427-437.
3. Lehman CD, Isaacs C, Schnall MD, et al. Cancer yield of mammography, MR, and US in high-risk women: prospective multi-institution breast cancer screening study. *Radiology.* 2007;244(2): 381-388.
4. Lee CH, Dershaw DD, Kopans D, et al. Breast cancer screening with imaging: recommendations from the Society of Breast Imaging and the ACR on the use of mammography, breast MRI, breast ultrasound, and other technologies for the detection of clinically occult breast cancer. *J Am Coll Radiol.* 2010;7(1):18-27.
5. Kim JY, Cho N, Koo HR, et al. Unilateral breast cancer: screening of contralateral breast by using preoperative MR imaging reduces indigence of metachronous cancer. *Radiology.* 2013;267(1):57-66.

**Continuing medical education (CME) credit is awarded upon successful completion of this posttest and evaluation.**

**To access the posttest and evaluation, visit:**

**[WWW.WORLDCLASSCME.COM/IMAGINGOFTHEBREAST](http://WWW.WORLDCLASSCME.COM/IMAGINGOFTHEBREAST)**

World Class CME  
6201 Fairview Road, Suite 322  
Charlotte, North Carolina 28210  
888-207-9105  
[www.worldclasscme.com](http://www.worldclasscme.com)  
[office@worldclasscme.com](mailto:office@worldclasscme.com)