

# Suppurative Complications and Upper Airway Obstruction in Infectious Mononucleosis

Joshua Nagler, MD

Rebecca L. Ruebner, MD

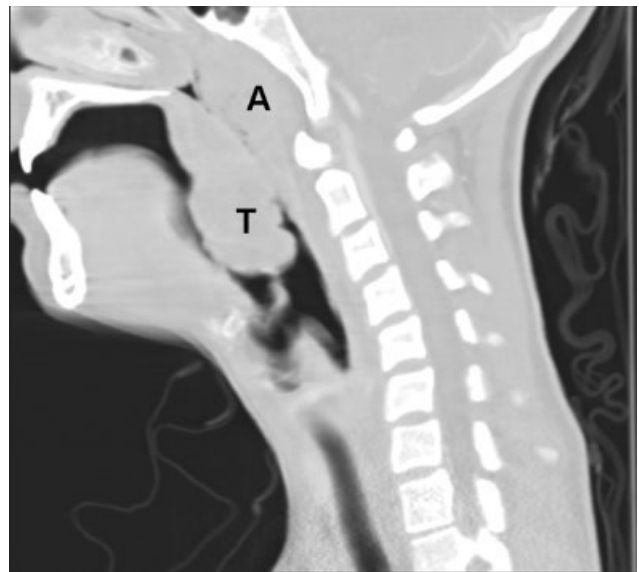Department of Medicine, Children's Hospital Boston and Harvard Medical School

A 17-year-old female patient presented to the emergency department reporting having fever, sore throat, and pain with swallowing for several days. The result of her rapid strep screen was negative. She had an elevated white blood cell count, mildly elevated AST and ALT levels, and a positive result from a heterophile antibody test (BBL™ Monoslide™). She was diagnosed with infectious mononucleosis. Given her inability to tolerate oral fluids, she was admitted to the hospital for intravenous hydration. After 3 days of receiving methylprednisolone intravenously, she had worsening throat pain, progressive neck swelling, difficulty handling her secretions, and new respiratory symptoms. During the examination, she was sitting upright in bed in moderate respiratory distress. She had kissing, exudative tonsils with palatal and uvular edema. Examination of her neck showed significantly enlarged anterior and posterior cervical lymph nodes without fluctuance. Her lung exam revealed subcostal retractions with transmitted upper airway sounds but good aeration. The edge of her liver and spleen tip were palpable.

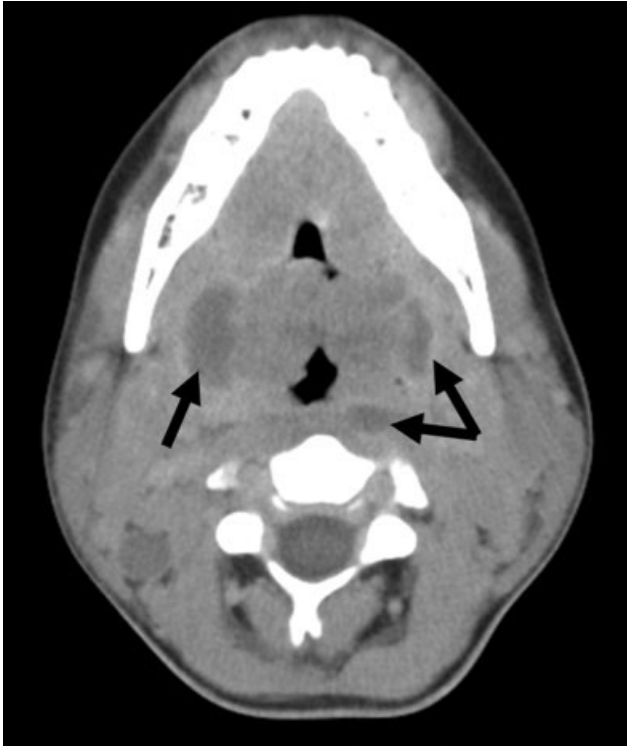
Because of the rapid progression of symptoms while on medical therapy, computed tomography (CT) of the neck was performed. Sagittal reconstructions showed adenoidal hypertrophy compromising her nasopharynx, and massive tonsillar enlargement causing nearly complete obstruction of her oropharyngeal airway (Fig. 1), with airway narrowing to less than 2.5 mm in axial images. Bilateral low-density lesions within the paratonsillar regions were suggestive of abscesses and retropharyngeal soft-tissue swelling was consistent with phlegmon (Fig. 2). The patient was taken to the operating room for an emergent tonsillectomy. Bilateral peritonsillar abscesses were drained, pus was sent for culture, and her tonsils were excised. Cultures from the abscesses grew *Streptococcus milleri*. The pa-

tient was discharged home 2 days later to complete a 2-week course of oral clindamycin.

Most patients with infectious mononucleosis (IM) have a benign, self-limited course. However, a wide range of severe complications have been described including airway obstruction, splenic rupture, meningoencephalitis, Guillain-Barré syndrome, peritonsillar abscess, and hemolytic anemia.<sup>1,2</sup> Upper-airway obstruction results from lymphoid hyperplasia throughout Waldeyer's ring, with associated soft-tissue edema. As many as 25% of patients hospitalized for IM will have some degree of airway obstruction.<sup>2,3</sup> Peritonsillar abscesses (PTAs) occur in approximately 1% of hospitalized patients with IM and may further obstruct the airway.<sup>4</sup> Most commonly, peritonsil-



**FIGURE 1.** Sagittal reconstructions from neck CT scan. "A" represents adenoidal hypertrophy compromising her nasopharynx, and "T" is massive tonsillar enlargement labeled as causing nearly complete obstruction of her oropharyngeal airway.



**FIGURE 2.** Axial view from the CT scan. The arrows point to the bilateral peritonsillar abscesses and the retropharyngeal phlegmon.

lar abscesses are polymicrobial, having both aerobic and anaerobic bacteria. In a study of young adults with peritonsillar abscesses from all causes, *Streptococcus pyogenes* was the most common aerobe, found in nearly half of isolates; *Streptococcus milleri*, the bacterium isolated from our patient, was the second most common organism, found in approximately 25% of these abscesses.<sup>5</sup> One prior case of airway obstruction from IM complicated by bilateral peritonsillar abscesses has been reported<sup>6</sup>; however, this patient was not reported to have concomitant retropharyngeal infection, as was noted in our patient.

Guidelines suggest that patients with mild, uncomplicated IM should be managed with supportive care alone; current recommendations are that steroids be prescribed only for specific complications of IM, including upper-airway obstruction.<sup>7</sup> Protocols for steroid regimens include initial prednisone doses ranging from 20 to 80 mg/day, with most advocating that they be tapered off over 1-2 weeks.<sup>7,8</sup>

Some of the controversy about the routine use of steroids in IM is related to concern for

potential infectious complications associated with immunosuppression. In a small case series, Handler et al. proposed that there is an association between steroid therapy and the development of peritonsillar abscesses.<sup>9</sup> However, this has not been tested in controlled trials, and the results of more recent studies do not support an increased likelihood of PTA in patients with infectious mononucleosis treated with corticosteroids.<sup>10,11</sup> Therefore, given that it has documented benefits and no proven adverse consequences, steroid therapy is uniformly recommended for patients with upper-airway obstruction secondary to infectious mononucleosis. However, use of steroids also mandates careful monitoring for signs or symptoms suggestive of secondary bacterial infection.

For patients whose symptoms progress despite medical management including steroid therapy, surgical intervention may be required. Both tracheostomy and tonsillectomy during acute infection, sometimes referred to as “hot tonsillectomy,” have been reported as surgical options for airway obstruction in IM, the latter having emerged as the preferred treatment.<sup>3</sup> Such treatment allows for drainage of any infectious collections, as well as removal of obstructing lymphoid tissue as indicated.

In conclusion, enlargement of tonsils and adenoids with associated edema in infectious mononucleosis can lead to upper-airway obstruction. Patients with evidence of such obstruction should be treated with a tapering course of corticosteroids. Peritonsillar abscesses and deep neck infections are also severe complications of IM and can cause further respiratory compromise. In cases where medical therapy is not effective, such as with our patient, evaluation for peritonsillar abscess and need for possible acute tonsillectomy may be required.

## REFERENCES

1. Jenson HB. Acute complications of Epstein-Barr virus infectious mononucleosis. *Curr Opin Pediatr.* 2000;12(3): 263-268.
2. Alpert G, Fleisher GR. Complications of infection with Epstein-Barr virus during childhood: a study of children admitted to the hospital. *Pediatr Infect Dis.* 1984;3:304-307.
3. Chan SC, Dawes PJ. The management of severe infectious mononucleosis tonsillitis and upper airway obstruction. *J Laryngol Otol.* 2001;115:973-977.
4. Johnsen J, Katholm M, Stangerup SE. Otolaryngological complications in infectious mononucleosis. *J Laryngol Otol.* 1984;98:999-1001.

5. Jousimies-Somer H, Savolainen S, Makitie A, Ylikoski J. Bacteriologic findings in peritonsillar abscesses in young adults. *Clin Infect Dis*. 1993;16(suppl 4):S292-S298.
6. Burstin PP, Marshall CL. Infectious mononucleosis and bilateral peritonsillar abscesses resulting in airway obstruction. *J Laryngol Otol*. 1998;112:1186-1188.
7. McGowan JE, Chesney PJ, Crossley KB, et al. Guidelines for the use of systemic glucocorticosteroids in the management of selected infections. Working Group on Steroid Use, Antimicrobial Agents Committee, Infectious Diseases Society of America. *J Infect Dis*. 1992;165(1):1-13.
8. Sudderick RM, Narula AA. Steroids for airway problems in glandular fever. *J Laryngol Otol*. 1987;10:673-675.
9. Handler SD, Warren WS. Peritonsillar abscess: a complication of corticosteroid treatment in infectious mononucleosis. *Int J Pediatr Otorhinolaryngol*. 1979;1(3):265-268.
10. Hanna BC, McMullan R, Hall SJ. Corticosteroids and peritonsillar abscess formation in infectious mononucleosis. *J Laryngol Otol*. 2004;118:459-461.
11. Ganzel TM, Goldman JL, Pedhya TA. Otolaryngologic Clinical Patterns in Pediatric Infectious Mononucleosis. *Am J Otolaryngol*. 1996;17:397-400.