

Campylobacter Empyema Due to Food Aspiration

Deepti Behl, MD¹
Rajnish Manchanda, MD¹
Charles Thomas, MD²

Department of Internal Medicine, Mayo Clinic,
Rochester, Minnesota

²Division of Pulmonary and Critical Care Medicine,
Mayo Clinic, Rochester, Minnesota

A 72-year-old man had been suffering from low-grade fever, minimally productive cough, and shortness of breath for 1 week when he experienced sudden, moderately severe right-sided chest pain. His local primary care physician found no abnormalities on physical exam and laboratory testing. A chest x-ray, however, did reveal a small right-sided pleural effusion. The patient was empirically started on levofloxacin but noticed no improvement. Two weeks into his illness, he was referred to our institution for further management. By this time, he reported a rapid 10-pound weight loss and a daily low-grade fever. Chest examination revealed dullness to percussion along with decreased breath sounds in the right posterior lung fields. A complete blood count showed an elevated white count of 17,000/mL with 14,000 neutrophils. Hemoglobin was 13.5 g/dL. A repeat chest x-ray and then a CT scan showed a multiloculated pleural effusion in the right lower hemithorax. Ultrasound-guided tap of this effusion showed cloudy fluid consistent with pus, with a protein of 4.8 g/dL and total nucleated cells of 6000/mL. A gram stain on this fluid was negative.

The patient had a history remarkable for severe underlying chronic obstructive pulmonary disease (COPD). His forced expiratory volume in 1 second (FEV1) was 21%, and his diffusing capacity of carbon monoxide (DLCO) was 27%. Therefore, decortication under general anesthesia was not an option. So the largest pus pocket was drained under CT guidance, and the patient was dismissed home on levofloxacin.

He returned for follow-up after 3 weeks and reported daily low-grade fever, night sweats, and an additional weight loss of 14 pounds. His white count had risen to 18,300/mL with a neutrophil count of 16,600. Hemoglobin had fallen to 11.9 g/dL. A repeat CT scan showed that although the previously drained fluid pocket had resolved, a moderate amount of fluid had reaccumulated in other pockets. Delayed anaerobic culture results from the hospitalization 3 weeks earlier were now available and, interestingly, showed 2+ growth of *Campylobacter jejuni*, broadly sensitive to all antibiotics including penicillin. Piperacillin/tazobactam was started intravenously, and CT-guided drainage of the largest pus pocket was again performed.

We carefully reexamined the patient's CT scan, and there appeared to be a lesion in the right main-stem bronchus. We decided to perform a bronchoscopy, which revealed a foreign body in the right main-stem bronchus. The foreign body turned out to be a piece of chicken and a peanut. On specific questioning of the patient again, he admitted that at times he coughed after eating too quickly. Specifically, he remembered that a few days

before falling sick he was at a village fair, where he had had chicken, and he thought he might have coughed after eating it. He denied any diarrheal illness in the recent past. We obtained a swallow study and upper gastrointestinal endoscopy, both of which were unremarkable.

He improved remarkably after removal of the foreign body and was sent home on amoxicillin-clavulanic acid for 3 weeks.

DISCUSSION

Campylobacter is one of the most common zoonoses in the world.¹ Commercially raised poultry is nearly always colonized with *Campylobacter jejuni*, and therefore, not surprisingly, 50% to 70% of *C. jejuni* infection in humans is caused by undercooked poultry.² The most common presentation of *C. jejuni* in humans is acute enteritis or colitis, but it can have numerous extraintestinal manifestations.³ Bacteremia occurs in fewer than 1% of patients, but *C. jejuni* meningitis and endocarditis have been reported. Hepatitis, interstitial nephritis, hemolytic-uremic syndrome, and IgA nephropathy are other reported complications. Our patient probably aspirated a piece of undercooked chicken that likely was the source of the *C. jejuni*, causing a persistent empyema.

Most patients fully recover from *C. jejuni* infections without medications, but if illness is severe or prolonged, antibiotics are recommended. Macrolides are usually the first-line treatment, but their increasing veterinary use is leading to their being resistant to these drugs.⁴ Most isolates are not susceptible to cephalosporins or penicillins, except amoxicillin or ticarcillin plus clavulanic acid. The *C. jejuni* isolated in culture in our lab from this patient was unusual in being broadly sensitive.

Our patient aspirated a foreign body in the form of chicken and a peanut without even realizing it. This is extremely uncommon, although foreign-body aspiration in otherwise healthy and alert adults sometimes does occur. The most common presentation is sudden choking, coughing, and vomiting, followed by wheezing and breathlessness. Patients may also present with persistent cough, hemoptysis, fever, breathlessness, or wheezing. Children may present with cyanosis.

Inorganic foreign bodies tend to be from dental "accidents," and organic aspirated foreign bodies tend to depend on the types of food eaten in a particular population, with bones, nuts, and apple pips the most common. In adults, all foreign bodies tend to lodge in the right bronchial tree. Aspiration of organic material is usually diagnosed later than

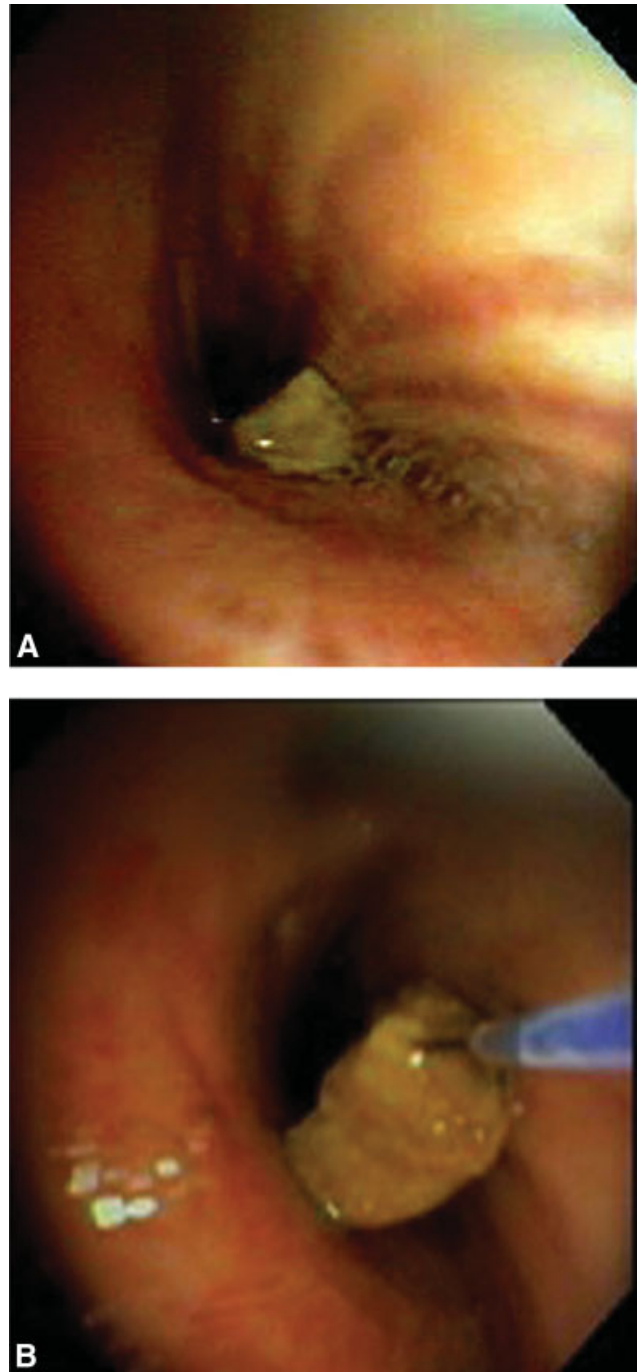


FIGURE 1. Bronch view of chicken in RML bronchus (A) and extracted with basket (B).

aspiration of nonorganic material.⁵ In either case, airway foreign-body aspiration is a common cause of recurrent bacterial pneumonia, and long delays in diagnosis are quite typical.⁶

Plain x-rays may be entirely normal. A CT may demonstrate an aspirated foreign body in the lumen of the tracheobronchial tree. Other common findings are atelectasis, hyperlucency, bronchiectasis, lobar consolidation, ipsilateral pleural effusion, and lymphadenopathy and a thickened bronchial wall adjacent to the foreign body.⁷ Newer methods such as CT virtual bronchoscopy are being evaluated for use in selected cases when clinical suspicion is high.⁸

REFERENCES

1. Altekruze SF, Stern NJ, Fields PI, Swerdlow DL. *Campylobacter jejuni*—an emerging foodborne pathogen. *Emerg Infect Dis*. 1999;5(1):28-35.
2. Newell D, Fearnley C. Sources of *Campylobacter* colonization in broiler chickens. *Appl Environ Microbiol*. 2003;69:4343-4351.
3. Peterson MC. Clinical aspects of *Campylobacter jejuni* infections in adults. *West J Med*. 1994;161(2):148-152.
4. Gibreel A, Taylor DE. Macrolide resistance in *Campylobacter jejuni* and *Campylobacter coli*. *J Antimicrob Chemother*. 2006;58:243-255.
5. Debeljak A, Sorli J, Music E, Kecelj P. Bronchoscopic removal of foreign bodies in adults: experience with 62 patients from 1974-1998. *Eur Respir J*. 1999;14:792-795.
6. Chen, CH, Lai CL, Tsai TT, Lee YC, Perng RP. Foreign body aspiration into the lower airway in Chinese adults. *Chest*. 1997;112(1):129-133.
7. Zissin R, Shapiro-Feinberg M, Rozenman J, Apter S, Smorjick J, Hertz M. CT findings of the chest in adults with aspirated foreign bodies. *Eur Radiol*. 2001;11:606-611.
8. Haliloglu M, Ciftci AO, Oto A, et al. CT virtual bronchoscopy in the evaluation of children with suspected foreign body aspiration. *Eur J Radiol*. 2003;48:188-192.