

The approach to clinical conundrums by an expert clinician is revealed through presentation of an actual patient's case in an approach typical of morning report. Similar to patient care, sequential pieces of information are provided to the clinician who is unfamiliar with the case. The focus is on the thought processes of both the clinical team caring for the patient and the discussant.

Gregory M. Bump, MD¹
 Vikas I. Parekh, MD¹
 Sanjay Saint, MD, MPH^{2,1,3}

¹ Department of Internal Medicine, University of Michigan, Ann Arbor, Michigan

² Ann Arbor VA Health Services Research and Development Center of Excellence, Ann Arbor, Michigan

³ VA/UM Patient Safety Enhancement Program

“Above or Below?”

A 49-year-old man presented with 2 days of chills, fever, anorexia, and increased cough and dyspnea. The patient had a history of chronic obstructive pulmonary disease (COPD) and noted that his cough and dyspnea had increased above normal for several days. He was now dyspneic with minimal activity and had slept at a 45-degree incline the night prior to evaluation due to dyspnea. He noted less improvement than usual with the use of his metered dose inhaler. His cough was occasionally productive of small amounts of white phlegm. He had vomited once. During a coughing episode the patient experienced a sudden onset of sharp right upper quadrant abdominal pain that worsened with coughing and sudden position changes. The patient denied a prior history of abdominal pain or surgery. The patient's last bowel movement was 2 days prior to admission. He denied melena or bright red blood per rectum.

My initial differential diagnosis for this patient's dyspnea and cough is pneumonia, acute exacerbation of COPD, or congestive heart failure. The presence of fever and anorexia increases the likelihood of infectious etiologies, whereas the presence of orthopnea points toward congestive heart failure. Noncardiac processes—such as a large pleural effusion or apical lung disease—could also cause orthopnea. His abdominal pain could be a result of pneumonia alone (perhaps in the right lower lobe with diaphragmatic irritation), but I am also considering complications of pneumonia such as empyema. Although his abdominal pain, dyspnea, and cough could also be a result of hepatobiliary disease, a perforated viscus, or pancreatitis, we currently have little reason to suspect a direct abdominal etiology. My top diagnosis is community-acquired pneumonia, perhaps accompanied by pleural effusion.

His medical history was significant for dilated cardiomyopathy and heavy alcohol use. His medications included various metered-dose inhalers, bupropion, digoxin, spironolactone, lisinopril, and metoprolol. He had never received corticosteroid therapy and had not previously been hospitalized for COPD-related problems. He had smoked one pack of cigarettes daily for 40 years.

Supported by a Career Development Award (to S.S.) from the Health Services Research & Development Program of the Department of Veterans Affairs and a Patient Safety Developmental Center Grant (to S.S.) from the Agency for Healthcare Research and Quality (P20-HS11540).

Heavy alcohol use is associated with an increased risk of several pulmonary infections such as gram-negative necrotizing pneumonia (classically, *Klebsiella pneumoniae*), pneumococcal pneumonia, aspiration pneumonia, anaerobic lung abscesses, and tuberculosis. Given his right upper quadrant pain, acute alcoholic hepatitis and alcohol-related pancreatitis enter the differential. His history of cardiomyopathy makes me consider congestive heart failure as more likely than before, and perhaps his abdominal pain is a result of hepatic congestion from right heart failure. His fever, however, cannot be attributed to cardiac failure. Less likely diagnoses include ischemic conditions related to his cardiomyopathy such as mesenteric ischemia from low perfusion or embolism from a cardiac thrombus. A pulmonary infection remains the most likely diagnosis.

He was an ill-appearing man in moderate respiratory distress, looking older than his stated age. His temperature was 38.4°C, heart rate 129 beats/minute, blood pressure 85/56 mm Hg, respiratory rate 24 breaths/minute, and oxygen saturation 92% on room air. A cardiovascular exam revealed no murmur, gallop, or rub. The jugular venous pulse was not elevated. His lungs were clear to auscultation. Abdominal exam revealed right-sided abdominal tenderness that appeared to localize to the rectus sheath. Otherwise, the abdomen was soft, with normal bowel sounds and no organomegaly. Rectal examination revealed guaiac negative stool and no focal tenderness. His extremities were normal.

His vital signs are worrisome for impending cardiovascular collapse and shock, possibly due to sepsis. The relatively nonfocal cardiopulmonary exam is surprising given his initial symptoms and makes me wonder if his dyspnea is primarily related to an abdominal process leading to diaphragmatic irritation rather than to a thoracic process. Congestive heart failure seems unlikely given the lack of supportive physical examination findings. His abdominal exam findings are puzzling. Although his abdominal wall tenderness could be benign—perhaps from muscular strain or a tear from coughing—it could represent a more worrisome process such as infection or a hematoma in the abdominal wall muscles. Mesenteric ischemia is still possible, as the exam is often unimpressive. A hepatic abscess or subphrenic abscess should be considered, as

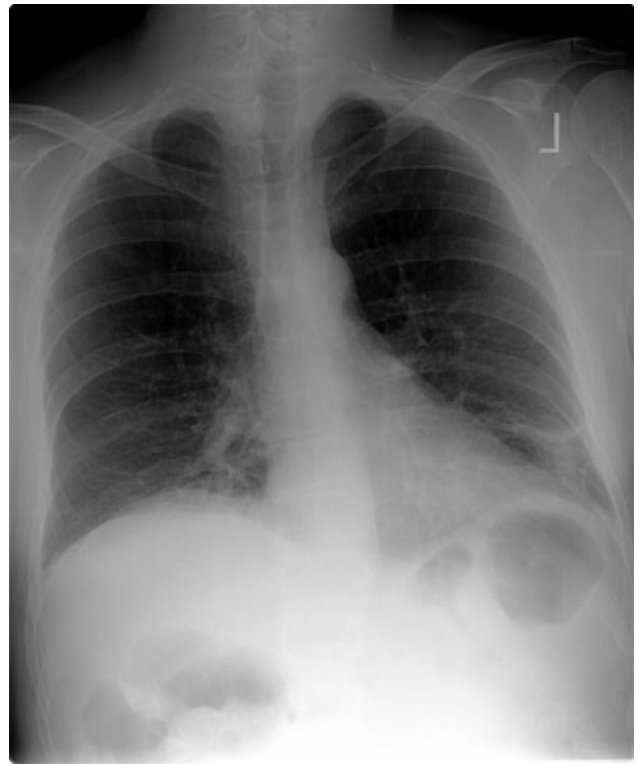


FIGURE 1. Chest radiograph obtained on admission revealed opacities in the right middle and both lower lobes consistent with atelectasis or pneumonia.

physical exam findings in these conditions can be subtle.

My differential remains relatively unchanged, but I have now put consideration of a hepatic or subphrenic abscess higher on my list. Early empiric broad-spectrum antibiotics seem necessary.

He had a white blood cell count of 26,700/mL with 92% neutrophils, a hemoglobin of 14.6 g/dL, and a platelet count of 312,000/mL. Sodium was 134 mmol/L, potassium was 4.3 mmol/L, chloride was 94 mmol/L, bicarbonate was 23 mmol/L, blood urea nitrogen was 23 mg/dL, and creatinine was 2.1 mg/dL. The results of the calcium, protein, albumin, and liver function tests were normal. Urinalysis was negative for protein and red blood cells. An electrocardiogram revealed sinus tachycardia. A chest radiograph at admission revealed mild opacities in both lower lobes and the right middle lobe consistent with either atelectasis or pneumonia (Fig. 1). A very small left effusion was also identified.

The additional data reinforce my clinical impression that this process is likely to be infectious. The

chest radiograph is consistent with community-acquired pneumonia, possibly from an atypical pathogen. Given his elevated creatinine, I am also considering a pulmonary-renal syndrome such as vasculitis, though hematuria was not present. A subphrenic abscess, mesenteric ischemia, or an abdominal wall process (because his abdominal tenderness on exam still needs an explanation) remain possibilities; my suspicion would increase if he does not respond appropriately to therapy for community-acquired pneumonia.

The clinical team's working diagnosis also was community-acquired pneumonia. Blood and sputum cultures were obtained, and the patient was treated with intravenous ceftriaxone, azithromycin, and intravenous fluid. By the second day, his creatinine had normalized; however, his hypoxemia had worsened, and he now required supplemental oxygen. His temperature was 39.3°C, and his heart rate was 150 beats/minute. The findings of an abdominal ultrasound of the kidneys, spleen, and right upper quadrant were normal.

It is too early to say the patient has failed therapy because a patient can get worse before getting better during the course of antibiotic therapy for community-acquired pneumonia. Fever, for example, may take up to 7 days to resolve, depending on host factors and the pathogen. Though I typically wait about 72 hours before assuming a patient is not appropriately responding to therapy, the additional information has made me concerned. The degree of tachycardia is significant and warrants an EKG to exclude an arrhythmia. I would also repeat the chest radiograph to evaluate for worsening infiltrates or increased pleural effusion.

On the third hospital day, the patient's abdominal pain had decreased with analgesia, but his fever, cough, and dyspnea remained largely unchanged. Antibiotics were changed to intravenous levofloxacin. A repeat chest radiograph revealed elevation of the right hemidiaphragm and bilateral effusions (Fig. 2). An electrocardiogram revealed sinus tachycardia. Blood cultures revealed no growth, and sputum cultures grew oral flora.

A significantly elevated right hemidiaphragm makes me reconsider the diagnosis of simple community-acquired pneumonia. The differential diagnosis for an elevated hemidiaphragm is best con-

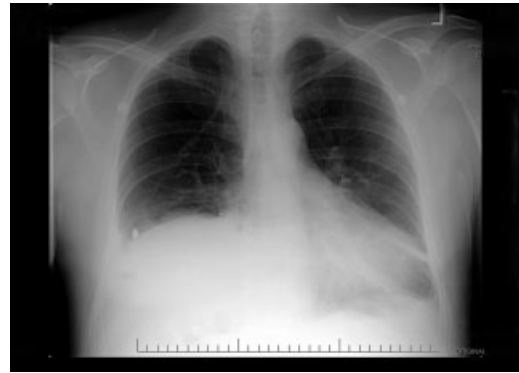

FIGURE 2. Chest radiograph obtained on the third hospital day revealed an elevated right hemidiaphragm and bilateral effusions.

sidered by location in relation to the diaphragm. Causes above the diaphragm include rib fracture, atelectasis, pleural thickening, and volume loss of the lung for another reason (e.g., surgery, bronchial obstruction due to tumor or mucus plugging), as well as “mimics” such as a densely consolidated pneumonia, pulmonary infarction, or a subpulmonary effusion. Diaphragmatic causes include eventration, rupture, phrenic nerve weakness, and intrinsic weakness because of neuromuscular disease (usually bilateral). Causes below the diaphragm that must be considered are subphrenic or liver abscess, liver (and other abdominal) malignancy, pancreatic pseudocyst, and distended bowel. Given the clinical picture, I am focusing below the diaphragm—especially on a possible hepatic or subphrenic abscess (which could be missed on ultrasound) and mimics of it such as dense consolidation or a subpulmonary effusion. Given the lack of response to antibiotics, I need to consider an infection that is not being treated, either because of location (abscess, effusion) or microbiology (tuberculosis, a parasite, a fungus, resistant bacteria). After confirming that the patient has a substantive pleural effusion, he needs a thoracentesis.

On the fourth hospital day, his temperature was 38.8°C, and his white blood cell count was 21,000/mL. A right-sided thoracentesis was performed; approximately 250 cc of fluid was obtained. Pleural fluid analysis revealed bloody fluid, with a white blood cell count of 16,750/mL with 94% neutrophils, 40,000 red blood cells/mL, lactate dehydrogenase of 278 U/L (normal serum value 80–200 U/L), protein of 3.7 g/dL, and glucose of 81 mg/dL. A pleural fluid pH was not obtained. A gram stain

revealed many white blood cells with no organisms noted. Serum protein was 7.4 g/dL. These results were thought to represent an exudative parapneumonic effusion; levofloxacin and supplemental oxygen were continued.

The pleural fluid appears exudative, but I am not sure this man has a parapneumonic effusion because, despite clinical deterioration, an obvious infiltrate is not seen on interval chest radiography. We must look closely at the fluid because this is a bloody effusion and somewhat atypical for a parapneumonic effusion. Also, the effusion does not appear large enough to explain why he has not improved on the current antibiotics. We should thus reconsider our diagnosis and management. I would obtain additional imaging (such as an abdominal and chest computed tomography [CT]) and perhaps obtain a consultation from the pulmonary team regarding the postulated initial diagnosis of pneumonia with effusion.

On the fifth day of hospitalization, the patient's dyspnea and cough persisted but were improved. His abdominal pain was minimal and felt improved with flatus. Fever continued to 38.8°C, and the white blood cell count was 20,000/mL. On examination the patient had decreased breath sounds at the right base and bibasilar crackles. His abdomen was soft, with tenderness in his right upper quadrant only with deep palpation; bowel sounds remained. An ultrasound of the chest was performed to look for a loculated effusion; however, no fluid was identified. The pulmonary consultant thought it likely that the patient had a subpulmonic effusion and recommended CT of the abdomen and chest.

His right upper quadrant tenderness is still unexplained. I would agree with the CT, primarily to evaluate other causes of his elevated diaphragm such as subphrenic or hepatic abscess. For now, I would make no change in antibiotic therapy.

On the sixth hospital day, the patient had an episode of bilious emesis. Chest and abdominal CT revealed collapse of the right middle and lower lobes with a small adjacent effusion, and a 6 × 6 × 16 cm abscess intimately opposed to the right lobe of the liver. Extending from the inferior extent of the abscess was a tubular thick-walled structure connecting to the cecum that was suspicious of a thickened inflamed appendix. There was periap-

pendiceal stranding suggesting inflammation. The small bowel was diffusely dilated up to 4.5 cm, suggesting a small bowel obstruction.

I suspect that his abscess is related to a perforated appendix and that the dilated small bowel is most likely a result of localized irritation of the bowel by the abscess and appendicitis. The collapsed lung is most likely due to local inflammation from the subdiaphragmatic abscess. Treatment should now be changed substantially. I would ask a surgeon to evaluate the patient because the most likely diagnosis is perforated appendicitis with abscess formation.

When the periappendiceal abscess was drained percutaneously, 190 mL of purulent fluid was removed. The cultures were positive for Klebsiella pneumonia, Enterococcus faecalis, and Streptococcus milleri. The patient was given 6 weeks of intravenous antibiotics with improvement in his clinical symptoms. During the interval the findings on his chest radiograph resolved completely. A laproscopic appendectomy 3 months later revealed significant right lower quadrant adhesions. The pathology specimen identified a distorted appendix with regeneration consistent with prior appendicitis. The patient was contacted 4 months after his surgery, and he reported that he was doing well, with no cardiopulmonary or gastrointestinal symptoms.

COMMENTARY

Community-acquired pneumonia (CAP) is a common cause of acute illness and accounts for nearly 1 million admissions per year in the United States.¹ The diagnosis of CAP is made when symptoms including dyspnea, fever, cough, or leukocytosis are present, with confirmation provided by a chest radiograph. Often the diagnosis is clear; however, there is no pathognomonic constellation of signs or symptoms that establish the diagnosis with certainty.² Many physicians learn that pneumonia—especially lower-lobe pneumonia—can lead to abdominal findings such as upper quadrant pain, vomiting, and tenderness to palpation. Conversely, the patient discussed above illustrates that a primary abdominal process can also result in a symptom complex that mimics pneumonia.

The prevalence of CAP coupled with the inherent uncertainty of a clinical diagnosis of CAP leads to an important question: How long is too long

before questioning the diagnosis? An analysis of the pneumonia Patient Outcomes Research Trial (PORT) limited to inpatients with CAP examined time to clinical stability. For the majority of patients, abnormal vital signs resolved within 2–3 days.³ In this study, 29% of patients had severe disease, and not surprisingly, these patients took longer to improve. Using the pneumonia severity index score, which accounts for age, comorbidity, abnormal vital signs, and laboratory data, the patient described in this article would be considered at high risk for death and complication with an estimated mortality of 9%.⁴ Using a combination of defervescence, resolution of tachycardia, tachypnea, and hypoxemia as markers of clinical stability, a patient like ours should respond within 4 days (with a range of 2–7 days). On the basis of these data—and the discrepancy between the patient's severe illness and relatively minor pulmonary infiltrates—it seems reasonable to have considered this patient as failing CAP therapy as early as the fourth day of hospitalization.

In approximately 10% of hospitalized patients with CAP, the clinical course is protracted.⁵ When patients do not improve as quickly as expected, the reasons that could explain this should be investigated. In a cohort of 49 patients with CAP who failed therapy the most common reasons for failure to improve were severity of the pneumonia and drug resistance.⁶ A multicenter study found that the incidence of resistance to penicillin by *Streptococcus pneumoniae*, the most common bacterial pathogen in CAP, was 30%, with a 4% in vitro resistance rate to ceftriaxone.⁷ How well in vitro resistance predicts clinical response, however, is unclear. Risk factors for antibiotic resistance include close exposure to children, recent antibiotic use, and recent hospitalization. Immunosuppressive conditions should also be considered in patients who fail to improve. Suppurative complications of pneumonia—such as empyema, parapneumonic effusion, and lung abscess—also delay recovery.

Another consideration in a patient with what appears to be a nonresolving pneumonia with pleural effusion is that the initial diagnosis is incorrect and the cause is extrathoracic. Pulmonary and cardiac diseases account for more than 90% of effusions, whereas less than 5% of pleural effusions result from intraabdominal causes.⁸ When should intraabdominal diseases be sought in patients with an effusion, fever, dyspnea, and cough? Light suggests that intraabdominal pathology should be in-

vestigated in patients who have pleural effusions without significant parenchymal disease.⁸ This point is underscored by the experience of our patient, whose chest radiographs showed, despite clinical decline, minimal airspace disease.

Several abdominal entities cause pleural effusion. Pancreatitis, either acute or chronic, with pseudocyst formation is the most common abdominal cause of exudative pleural effusions. Approximately 10% of patients with pancreatic disease will develop effusions, usually left-sided.⁹ These left-sided effusions are also seen in splenic abscesses, usually as a result of endocarditis. Intrahepatic abscess is associated with effusions in 20% of patients.¹⁰ A subphrenic abscess, as seen in our patient, is an uncommon cause of exudative pleural effusions. Historically, subphrenic abscesses resulted from a perforated viscus, with ruptured appendicitis the most common cause,¹¹ followed by perforated peptic ulcers and biliary tract disease. With the advent of antibiotics, the causes of subphrenic abscess changed considerably, with the majority of current cases resulting from postsurgical complications.¹² The findings of a chest radiograph are abnormal in 80% of patients with subphrenic abscess,^{12–14} an elevated hemidiaphragm and pleural effusion are found in the majority of cases. The symptoms of a subphrenic abscess are nonspecific, and patient's complaints are equally split between predominantly thoracic and predominantly abdominal complaints.¹⁵

Appendicitis, a common disease predominantly of the young, may lead to atypical presentations in older individuals. In a retrospective analysis of 113 patients older than 60 years with appendicitis, 70% presented in an atypical fashion.¹⁶ Typical symptoms include right lower quadrant pain, fever, anorexia and a white blood cell count greater than 10,000/mL. Fever was the most frequently absent symptom, seen in only 37% of older patients. In this cohort, approximately one third of older patients waited more than 48 hours prior to presentation. The time between symptom onset and clinical presentation is a strong predictor of perforation risk.¹⁷ As in this case, roughly 2% of patients with acute appendicitis will present with perforation and abscess formation.¹⁸ In such patients the management is initially conservative. Percutaneous drainage and broad spectrum antibiotics are the treatment of choice, followed by an interval appendectomy in 6–12 weeks.¹⁹ The rationale for delayed

surgery is that earlier surgery may disseminate a localized inflammatory process.²⁰

Community-acquired pneumonia is a more frequent cause of hospital admission than is intraabdominal abscess. Physicians often face the dilemma of when to pursue alternative diagnoses after a patient who is thought to have an atypical presentation of a common disease (ie, CAP) fails to respond to conventional therapy. Although clinicians learn that right upper quadrant pain may be a symptom of pneumonia, our patient revealed that abdominal causes may mimic pneumonia and produce a pleural effusion. Determining whether the primary disease originates above or below the diaphragm is critical to guiding therapy. When patients fail to respond adequately to therapy, clinicians should set a low threshold for deciding to image the abdomen in a patient with modest pulmonary infiltrates, pleural effusion, and abdominal pain.

Address for correspondence and reprint requests: Gregory M. Bump, MD, University of Michigan Health System, 3119 Taubman Center, Box 0376, 1500 E. Medical Center Drive, Ann Arbor, MI 48109-0376; Fax: (734) 615-8401; E-mail: gbump@umich.edu

REFERENCES

1. Niederman MS, McCombs JL, Unger AN, et al. The cost of treating community-acquired pneumonia. *Clin Ther*. 1998;20:820–827.
2. Metlay JP, Kapoor WN, Fine MJ. Does this patient have community-acquired pneumonia? Diagnosing pneumonia by history and physical examination. *JAMA*. 1997;278:1440–1445.
3. Halm EA, Fine MJ, Marrie TJ, et al. Time to clinical stability in patients hospitalized with community acquired pneumonia. Implications for practice guidelines. *JAMA*. 1998;279:1452–1457.
4. Fine MJ, Auble TE, Yealy DM, et al. A prediction rule to identify low-risk patients with community-acquired pneumonia. *N Engl J Med*. 1997;336:243–250.
5. Feinsilver SH, Fein AM, Niederman MS, et al. Utility of fiberoptic bronchoscopy in non resolving pneumonia. *Chest*. 1990;98:1322–1326.
6. Arancibia F, Ewig S, Martinez JA, et al. Antimicrobial treatment failures in patients with community acquired pneumonia. Causes and prognostic implications. *Am J Respir Crit Care Med*. 2000;162:154–160.
7. Doern GV, Brueggemann AB, Huynh H, et al. Antimicrobial resistance with *Streptococcus pneumoniae* in the United States, 1997–98. *Emerg Infect Dis*. 1999;5:757–765.
8. Light RW, Broaddus VC. Pleural effusion. In: Murray JF, Nadel JA, eds. Textbook of respiratory medicine. 3rd ed. Philadelphia: WB Saunders, 2000:2013–2041.
9. Gumaste V, Singh V, Dave P. Significance of pleural effusion in patients with acute pancreatitis. *Am J Gastroenterol*. 1992;87:871–874.
10. Light RW. Exudative pleural effusions secondary to gastrointestinal diseases. *Clin Chest Med*. 1985;6(1):103–111.
11. Moore HD. Subphrenic abscess. *Ann Surg*. 1963;158:240–248.
12. Connell TR, Stephens DH, Carlson HC, Brown ML. Upper abdominal abscess: a continuing and deadly problem. *Am J Roentgenol*. 1980;134:759–765.
13. Wetterfors J. Subphrenic abscess. A clinical study of 101 cases. *Acta Chir Scand*. 1959;117:388–408.
14. Sherman NJ, Davis JR, Jessep JE. Subphrenic abscess a continuing hazard. *Am J Surg*. 1969:117–122.
15. Carter R, Brewer LA. Subphrenic abscess: a thoracoabdominal clinical complex. The changing picture with antibiotics. *Am J Surg*. 1964;108:165–172.
16. Storm-Dickerson TL, Horattas MC. What have we learned over the past 20 years about appendicitis in the elderly. *Am J Surg*. 2003;185:198–201.
17. Pittman-Waller VA, Myers JG, Stewart RM, et al. Appendicitis: why so complicated? Analysis of 5755 consecutive appendectomies. *Am Surg*. 2000;66:548–554.
18. Jordan JS, Kovalcik PJ, Schwab CW. Appendicitis with a palpable mass. *Ann Surg*. 1981;193:227–229.
19. Oliak D, Yamini D, Udani VM, et al. Nonoperative management of perforated appendicitis without periappendiceal mass. *Am J Surg*. 2000;179:177–181.
20. Lally KP, Cox CS, Andrassy RJ. Appendix. In: Townsend CM, ed. Sabiston textbook of surgery. The biologic basis of modern surgical practice. 16th ed. Philadelphia: W. B. Saunders, 2001:917–928.