

## *Streptococcus pneumoniae* Keratitis

Prashant Bhawe, MD

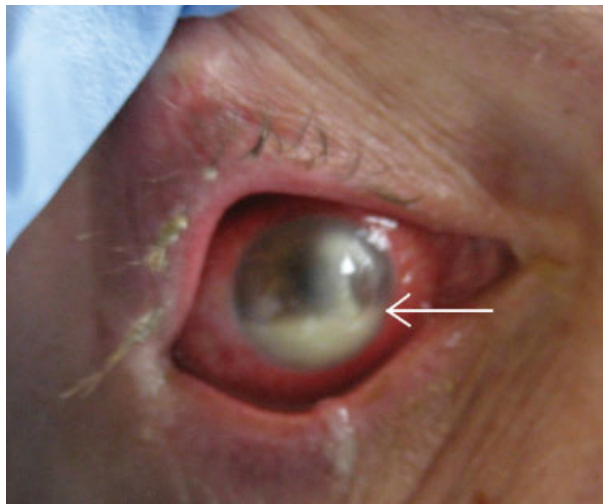
Gabriel Chamie, MD

UCSF Medical Center, San Francisco, California.

**A** 45-year-old man with HIV infection (CD4 count of 6 cells per cubic millimeter) presented after 2 days of diminishing visual acuity and pain in his right eye. Examination revealed a corneal ulceration and hypopyon (Fig. 1, white arrow). Chest radiograph demonstrated right lower lobe pneumonia. Cultures of the hypopyon, sputum, and blood grew *Streptococcus pneumoniae*.

The patient was treated with IV ceftriaxone as well as fortified tobramycin, vancomycin, and doxycycline eye drops with intravitreal vancomycin. The patient's vision and eye pain gradually improved, and he was discharged home.

Infectious ulcerative keratitis is a rare entity, most often resulting from direct corneal invasion by bacterial or fungal organisms. This case appears to involve hematogenous spread. *Streptococcus pneumoniae*, *Staphylococcus*, and *Pseudomonas* are the most common bacterial pathogens. Broad-spectrum topical antibiotics are the cornerstone of therapy. Topical steroids may be administered once the infection is under control.



**FIGURE 1.** Layering exudate in the anterior chamber.

Address for correspondence and reprint requests: Prashant Bhawe, MD, 505 Parnassus, M980, San Francisco, CA 94117; E-mail: prashant.bhawe@ucsf.edu

Received 9 July 2007; revision received 17 September 2007; accepted 19 October 2007.