

## Soft-Tissue Gangrene Secondary to Mixed Cryoglobulinemia

Tarek Darwish, MD

Department of Internal Medicine, University of Missouri–Kansas City

**A** 61-year-old Hispanic male with chronic hepatitis C presented with a 4-week history of a nonpruritic skin rash involving his lower extremities, hands, arms, and right ear. He also reported purple discoloration of his right foot, along with pain in the extremity that worsened with ambulation. Physical examination revealed diffuse purpura of both arms and legs (Figure 1). The right foot was cold to the touch and purple to black in color (Figure 2). There were multiple skin ulcers of various sizes covering the anterior aspect of his

legs bilaterally. Pedal pulses were 2/4. Laboratory evaluation revealed positive cryoglobulins with low  $C_4$  and  $CH_{50}$  concentrations of 3 mg/dL (10–40) and 2 units/mL (60–144), respectively. Other immunological studies were negative. Lower extremity arterial Doppler studies were normal.

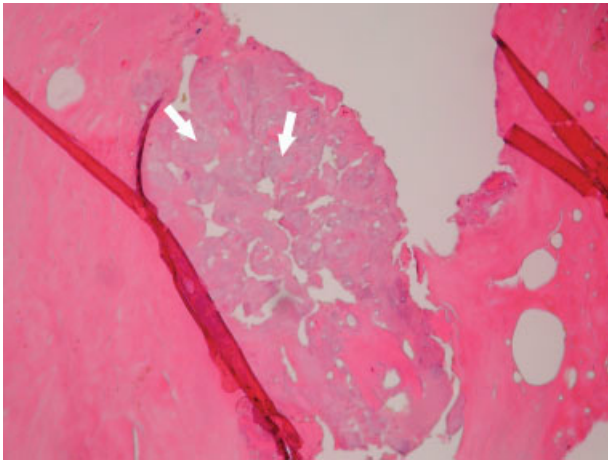
His clinical and laboratory findings were attributed to mixed cryoglobulinemia, and treatment, consisting of daily intravenous methylprednisolone, a single dose of intravenous cyclophosphamide, and plasmapheresis, was initiated. Despite these interventions, 5 days later, he developed severe burning pain in the right extremity with worsening discoloration and a line of demarcation at the level of his proximal midfoot. Eventually, right below the knee, amputation was performed, and histopathological examination

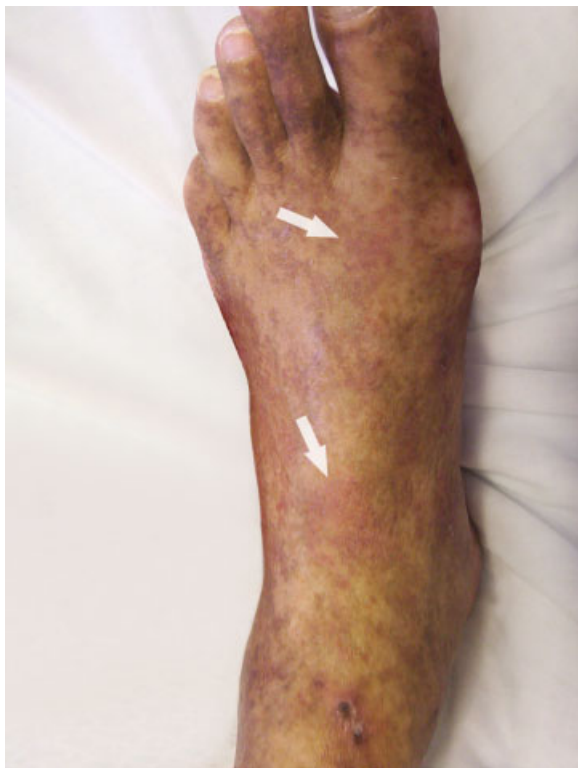

FIGURE 1. Left-foot purpura.

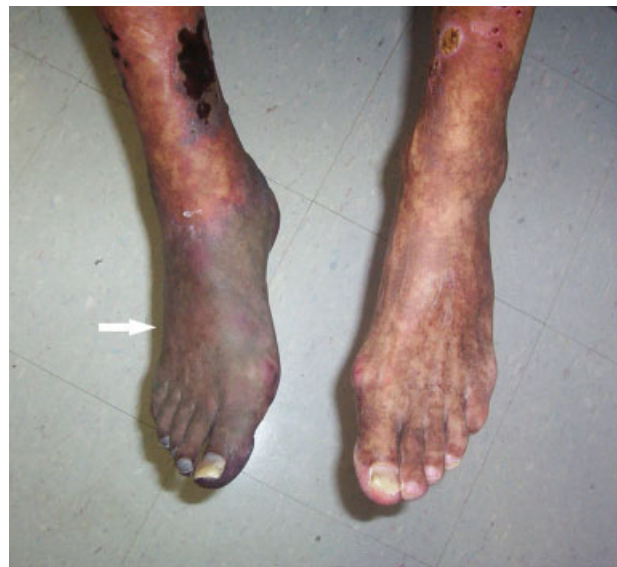

FIGURE 2. Right-foot gangrene.



**FIGURE 3.** Avascular necrosis of the bone.

showed soft-tissue gangrene with avascular necrosis of the bone (Figure 3). The patient subsequently had an uneventful course. Plasmapheresis and oral prednisone were continued.

Cryoglobulinemia is a small- to medium-vessel vasculitis due to cryoglobulin-containing immune complexes. There are 3 types, with the classification based on an immunological analysis of the cryoglobulin composition. Hepatitis C virus infection is closely associated with type II mixed cryoglobulinemia. Cutaneous manifestations are the most common, consisting of palpable purpura, urticaria, postinflammatory hyperpigmentation, acrocyanosis, and skin ulcers. A serum cryoglobulin elevation is diagnostic and is usually accompanied by hypocomplementemia.

Treatment of the underlying disease is essential. However, aggressive therapy with plasmapheresis and immunosuppressive medications is warranted in severe cases involving limb- or organ-threatening vasculitis.

Address for correspondence and reprint requests: Tarek Darwish, MD, Assistant Professor of Medicine, Department of Internal Medicine, University of Missouri-Kansas City, 2301 Holmes Street, Kansas City, MO 64108-2677; Telephone: (816) 404-5036; Fax: (816) 404-5014; E-mail: tzdarwish@hotmail.com

Received 4 March 2008; revision received 28 April 2008; accepted 26 May 2008.