

# Iliac Vein Compression Syndrome: An Underdiagnosed Cause of Lower Extremity Deep Venous Thrombosis

Ami Naik, BS<sup>1</sup>  
Taimur Mian, BS<sup>2</sup>  
Aney Abraham, MD<sup>3</sup>  
Vijay Rajput, MD<sup>3</sup>

<sup>1</sup>Medical Student, Department of Internal Medicine, UMDNJ-Robert Wood Johnson Medical School, Camden, NJ.

<sup>2</sup>Medical Student, St. George's University, Grenada, West Indies.

<sup>3</sup>Department of Internal Medicine, UMDNJ-Robert Wood Johnson Medical School, Camden, NJ.

Disclosure: Nothing to report.

Iliac vein compression syndrome (CS) is a rare cause of deep venous thrombosis. It is caused by an anatomic anomaly in which the right common iliac artery overlies the left common iliac vein causing mechanical compression. Subsequent endothelial changes within the vessels have the potential to spur thrombus formation. Aggressive diagnostic and therapeutic interventions must be implemented upon suspicion to avoid long-term complications. We report on a 19 year old male who presented with ICS. We discuss the clinical presentation, diagnosis, and current treatment options. *Journal of Hospital Medicine* 2010;5:E12–E13. © 2010 Society of Hospital Medicine.

**KEYWORDS:** Cockett Syndrome, deep venous thrombosis, iliac vein compression syndrome, May-Thurner syndrome.

Hospitalists frequently diagnose and treat lower extremity deep venous thrombosis (DVT). Patients presenting with acute DVT or chronic venous stasis of the left leg can have an underlying anatomic anomaly known as iliac vein compression syndrome (ICS), May-Thurner syndrome, or Cockett syndrome in Europe. In this condition, the right iliac artery overlies the left iliac vein, causing extrinsic compression of the vein (Figure 1).<sup>1</sup> This compression and accompanying intraluminal changes predisposes patients to left-sided lower extremity DVT.<sup>2</sup> Failure to recognize and treat this anomaly in patients with acute thrombosis can result in serious vascular sequelae and chronic left leg symptoms.<sup>3</sup> A high clinical suspicion should be maintained in young individuals presenting with proximal left leg DVT with or without hypercoagulable risk factors. The following report is a case of ICS in a young male recognized and treated early by aggressive diagnostic and therapeutic interventions.

## Case Report

A 19-year-old man presented to the ER with sudden onset of left lower extremity swelling and pain 5 days after a fall. He had no known risk factors for DVT. On physical examination his left leg was dusky, swollen, and tender from his groin to his ankle, with good arterial pulses. Duplex ultrasonogram of the leg showed a clot in the femoral vein extending up the popliteal vein. Following a venogram, he underwent mechanical thrombectomy and regional thrombolysis. A repeat venogram showed an irregular narrowing of the left iliac vein and a tubular filling defect at the junction of the inferior vena cava and common iliac veins, suggestive of external compression from the right common iliac

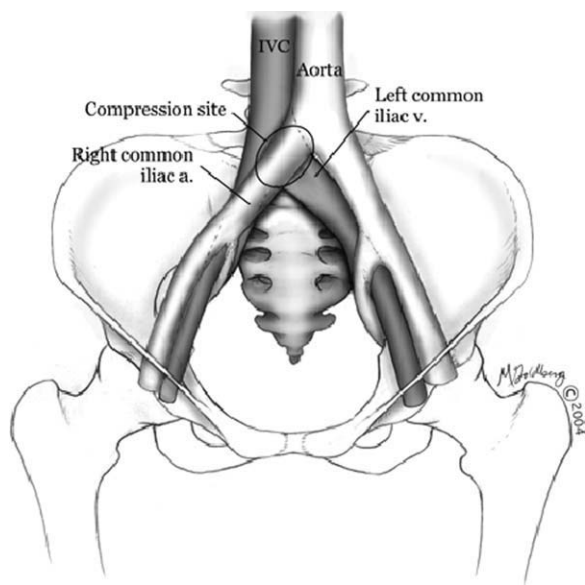
artery. The patient underwent successful angioplasty and stenting of the common iliac vein. He was treated with intravenous heparin, warfarin and clopidogrel. His hypercoagulable work-up was inconclusive.

## Discussion

In 1956, May and Thurner<sup>1</sup> brought clinical attention to ICS. They hypothesized that an abnormal compression of the left iliac vein by an overriding right iliac artery—present in 22% of a series of 430 cadavers—led to an intraluminal filling defect in the vein. The chronic extrinsic compression and pulsing force from the overlying artery results in endothelial irritation and formation of venous spurs (fibrous vascular lesions) in the intimal layer of the vein.<sup>1</sup> Following the principles of Virchow's triad, this endothelial injury propagates the formation of a thrombus. Subsequent studies by Kim et al.<sup>4</sup> suggest that there are 3 stages involved in the pathogenesis of thrombosis in ICS: asymptomatic vein compression, venous spur formation, and finally DVT formation.<sup>4,5</sup> It is estimated that 1 to 3 out of 1000 individuals with this malformation develop DVT each year.<sup>5,6</sup>

Patients with ICS may present to the emergency or ambulatory setting in either an acute or chronic phase. The acute phase is the actual episode of thrombosis. Symptoms include left leg pain and swelling up to the groin. In rare cases, pulmonary emboli may be the initial presentation. A lifelong chronic phase can follow if undiagnosed, resulting in pain and swelling of the entire left leg, venous claudication, recurrent thrombosis, pigmentation changes, and ulceration.<sup>3</sup>

The typical ICS patient is a woman between 18 and 30 years old,<sup>3</sup> possibly due to the developmental changes in



**FIGURE 1.** Illustration of the anatomic anomaly present in ICS. The right common iliac artery is shown overlying the left common iliac vein creating a site of compression. From Grunwald et al.<sup>11</sup>

the pelvic structures in preparation for child-bearing.<sup>2</sup> Many patients also present after pregnancy; increased lordosis during pregnancy may put additional strain on the anatomic lesion.<sup>3</sup> Nevertheless, Steinberg and Jacocks<sup>7</sup> reported that out of 127 patients, 38 (30%) were male. Thus, it is critical not to overlook ICS as a possible cause of thrombosis in male patients.

The urgency in diagnosing this anatomic variation lies in the distinct need for more aggressive treatment than that required for a typical DVT. While Doppler ultrasound is typically the first diagnostic test performed in this patient population, it is not specific. For patients with physical exam findings highly suspicious of ICS, venography and magnetic resonance venography are superior modalities to make a definitive diagnosis of the syndrome.<sup>8</sup> In ICS, these studies will reveal left common iliac vein narrowing with intraluminal changes suggestive of spur formation.<sup>2</sup>

Due to the mechanical nature of ICS pathology, anticoagulation therapy alone is ineffective. ICS prevents recanalization in 70% to 80% of patients and up to 40% will have continued clot propagation.<sup>5,7</sup> More aggressive treatment using endovascular techniques such as the combination of thrombectomy, angioplasty, and intraluminal stenting have proven to be the most efficacious treatment modality for ICS.<sup>9</sup> A study by AbuRahma et al.<sup>10</sup> demonstrated that one year following this aggressive combination, patency rate was 83% (vs. 24% following thrombectomy alone).

## Conclusion

The anatomic anomaly present in ICS was identified by CT in as many as two-thirds of an asymptomatic patient population studied by Kibbe et al.<sup>12</sup> Although a common structural anomaly, it is important to note that only 1 to 3 out of 1000 individuals with this malformation develop DVT annually. ICS should be included in the differential diagnosis of all young individuals presenting with proximal left leg DVT with or without hypercoagulable risk factors. If the mechanical compression is not diagnosed and treated, the syndrome can develop into a life-long chronic phase with multiple complications.<sup>2</sup> It is therefore critical that aggressive diagnostic and therapeutic interventions be implemented immediately upon suspicion of ICS.

## Address for correspondence and reprint requests:

Ami Naik, BS, Cooper University Hospital, UMDNJ-Robert Wood Johnson Medical School at Camden, 401 Haddon Avenue, E&R Building, 3rd Floor, Camden, NJ 08103; Telephone: 609-273-8150; E-mail: naikam@umdnj.edu Received 30 July 2009; revision received 4 December 2009; accepted 29 December 2009.

## References

1. May R, Thurner J. A vascular spur in the vena iliaca communis sinistra as a cause of predominantly left-sided thrombosis of the pelvic veins. *Z Kreislaufforsch.* 1956;45:912–922.
2. Oguzkurt L, Ozkan U, Ulsan S, Koc Z, Tercan F. Compression of the left common iliac vein in asymptomatic subjects and patients with left iliofemoral deep vein thrombosis. *J Vasc Interv Radiol.* 2008;19:366–370; quiz 71.
3. Cockett FB. The iliac compression syndrome alias 'iliofemoral thrombosis' or 'white leg'. *Proc R Soc Med.* 1966;59:360–361.
4. Kim D, Orron DE, Porter DH. Venographic anatomy, technique and interpretation. *Peripheral Vascular Imaging and Intervention.* St. Louis (MO): Mosby-Year Book; 1992:269–349.
5. Murphy EH, Davis CM, Journeycake JM, DeMuth P, Arko FR. Symptomatic iliofemoral DVT after onset of oral contraceptive use in women with previously undiagnosed May-Thurner Syndrome. *J Vasc Surg.* 2009; 49:697–703.
6. Nordstrom M, Wheeler HB, Goldberg RJ. A prospective study of the incidence of deep vein thrombosis within a defined urban population. *J Intern Med.* 1992;232:152–160.
7. Steinberg JB, Jacocks MA. May-Thurner syndrome: a previously unreported variant. *Ann Vasc Surg.* 1993;7:577–581.
8. Hurst D, Forauer A, Bloom J, Greenfield L, Wakefield T, Williams D. Diagnosis and endovascular treatment of iliocaval compression syndrome. *J Vasc Surg.* 2001;34:106–113.
9. O'sullivan GJ, Semba CP, Bittner CA, et al. Endovascular management of iliac vein compression (May-Thurner) syndrome. *J Vasc Interv Radiol.* 2000;11:823–836.
10. AbuRahma AF, Perkins SE, Wulu JT, Ng HK. Iliofemoral deep vein thrombosis: conventional therapy versus lysis and percutaneous transluminal angioplasty and stenting. *Ann Surg.* 2001;233:752–760.
11. Grunwald MR, Goldberg MJ, Hofmann LV. Endovascular management of May-Thurner Syndrome. *Am J Roentgenol.* 2004;183:1523–1524.
12. Kibbe M, Ujiki M, Goodwin L, Eskandar M, Yao J, Matsumura J. Iliac vein compression in an asymptomatic patient population. *J Vasc Surg.* 2004; 39:937–943.