

Pot Shots—Cannabis Arteritis of the Digits

Sally Daganzo, MD
George Nune, MD

Internal Medicine, California Pacific Medical Center, San Francisco, California.

A 46-year-old man with a history of heavy marijuana use for 30 years presented to the emergency room with 1 month of progressively worsening distal extremity pain and numbness that had developed into necrosis at the tips of his fingers (Figure 1A, arrows). The patient did not have other systemic symptoms. Transthoracic echocardiogram was normal. An evaluation for “hypercoagulable” disorders, blood cultures, C-ANCA, cryoglobulins, Hepatitis C serologies, and human immunodeficiency virus

(HIV) serologies were all negative. Erythrocyte sedimentation rate was within normal limits. An arteriogram of the hands showed distal subsegmental obliteration of digital arteries (Figure 1B, arrows), which was consistent with thromboangiitis obliterans (Buerger’s Disease). While the patient rarely consumed tobacco, he reported smoking up to 10 marijuana cigarettes daily and a diagnosis of cannabis arteritis was made. The patient was encouraged to discontinue smoking and at follow-up he had marked

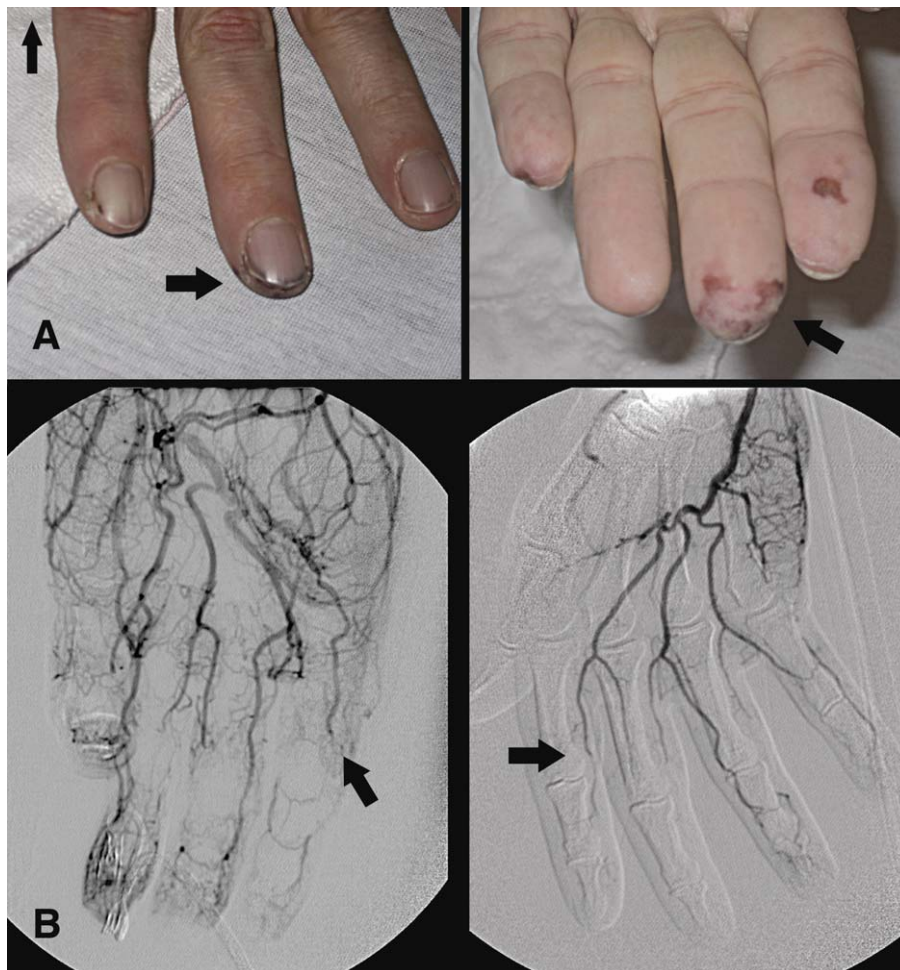


FIGURE 1. Cutaneous manifestations of (A) thromboangiitis obliterans and (B) arteriogram demonstrating subsegmental obliteration of the digital arteries.

improvement in symptoms with abstinence from marijuana.

Address for correspondence and reprint requests:

Sally Daganzo, 2333 Buchanan St., San Francisco, CA 94115; Telephone: 415-600-1349; Fax: 415-775-7437; E-mail: sdaganzo@gmail.com Received 30 November 2009; accepted 10 January 2010.

References

1. Noël B, Ruf I, Panizzon RG. Cannabis arteritis. *J Am Acad Dermatol.* 2008; 58(5 Suppl 1):S65–S67.
2. Combemale P, Consort T, Denis-Thelis L, Estival JL, Dupin M, Kanitakis J. Cannabis arteritis. *Br J Dermatol.* 2005;152(1):166–169.
3. Peyrot I, Garsaud AM, Saint-Cyr I, Quitman O, Sanchez B, Quist D. Cannabis arteritis: a new case report and a review of literature. *J Eur Acad Dermatol Venereol.* 2007;21(3):388–391.