This supplement is supported by independent educational grants from

Alcon Vision, LLC
Viatris, Inc.

Copyright © 2024 Frontline Medical Communications Inc.
All material in this activity is protected by copyright.

A PUBLICATION OF
THE JOURNAL OF
FAMILY
PRACTICE™

APRIL 2024 | MDEDGE.COM/FAMILYMEDICINE

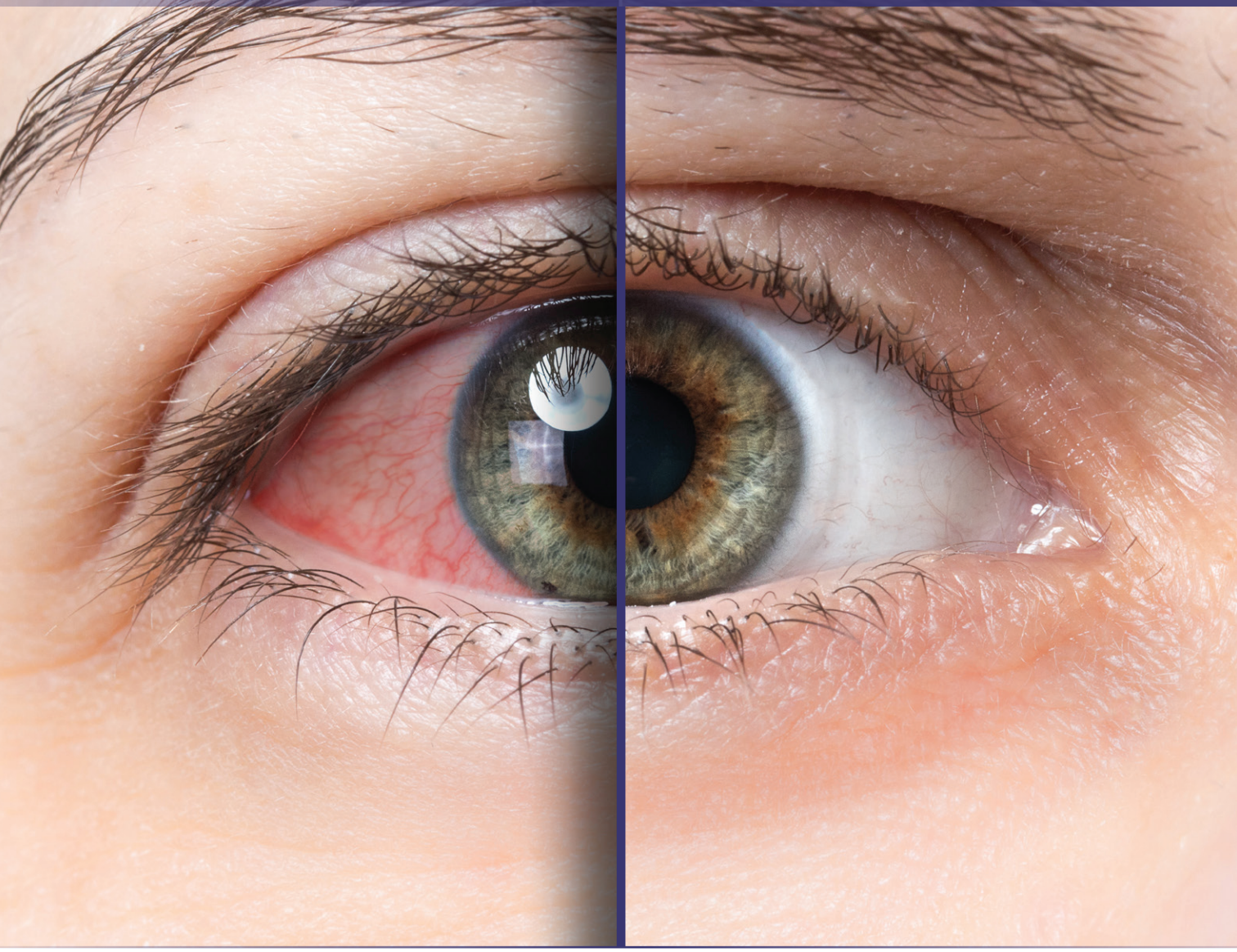

Dry Eye: A Hands-On Guide for Diagnosis and Treatment in Primary Care

Based on a Medscape Education Online Activity

CME INFORMATION

CME / ABIM MOC

Release Dates: 4/4/24
Expiration Date 4/4/25

TARGET AUDIENCE

This activity is intended for primary care physicians, ophthalmologists, optometrists, nurses, pharmacists, and other clinicians who treat patients with dry eye disease (DED).

GOAL STATEMENT

The goal of this activity is for the learner to be better able to assess, treat, counsel, and refer patients with DED.

LEARNING OBJECTIVES

Upon completion of this activity, participants will be able to:

- Assess patients with DED
- Devise first treatment plans for DED
- Explain to patients how to manage their dry eye symptoms
- Describe novel therapies in DED (mechanisms of action [MoAs], clinical data)

DISCLOSURES

Faculty

John D. Sheppard, MD, MMSc, FACS
Professor of Ophthalmology
Eastern Virginia Medical School
Norfolk, Virginia

John D. Sheppard, MD, MMSc, FACS, has no relevant financial relationships.

Preeya K. Gupta, MD
Associate Professor of Ophthalmology
Tulane University
Medical Director and Attending Surgeon
Triangle Eye Consultants
New Orleans, Louisiana

Preeya K. Gupta, MD, has the following relevant financial relationships:

- Consultant or advisor for: Alcon Laboratories Corp.; Aldeyra; Allergan, Inc.; Azura Ophthalmics; Expert Opinion; HanAll Biopharma; Johnson & Johnson Vision; Kala Pharmaceuticals; New World Medical; Novartis Pharmaceuticals; Ocular Science; Ocular Therapeutix; Orasis; Oyster Point; Sight Sciences; Spyglass; Surface Ophthalmics; Sun Pharmaceuticals; Tear Clear; Tear Lab; Tissue Tech, Inc.; Visionology; Zeiss
- Stock options from: Azura Ophthalmics; Expert Opinion; Orasis; Oyster Point; Surface Ophthalmics; Spyglass; Tarsus; Tear Clear; Visant; Visionology

Selina McGee, OD, FAAO
Owner/CEO, BeSpoke Vision
President, Intrepid Eye Society
Edmond, Oklahoma

Selina McGee, OD, FAAO, has the following relevant financial relationships:

- Consultant/advisor for or speaker/member of speakers bureau for: Alcon Laboratories Corp.; Allergan, Inc.; Bausch & Lomb, Inc.; Cynosure; Dompe; Lumenis; Oyster Point; RVL; Science Based Health; Sun Pharmaceuticals; Tarsus
- Additionally, a consultant/advisor for: Aldeyra; Avellino; Bruder; Horizon; Kala Pharmaceuticals; Novartis Pharmaceuticals; Optovue; Thea; Topcon; Versant; Zeiss
- Research funding from: Oyster Point

Medscape Staff

The following Medscape, LLC, employees have no relevant relationships:
Editor – **Lisette Arnaud-Hevi, PhD**, Senior Medical Education Director
Medical Writer – **Jason Luis Quiñones, PhD**, Associate Medical Writer
Compliance Reviewer – **Leigh Schmidt, MSN, RN, CNE, CHCP**, Associate Director, Accreditation and Compliance

ACCREDITATION STATEMENTS

In support of improving patient care, Medscape, LLC is jointly accredited with commendation by the Accreditation Council for Continuing Medical Education (ACCME), the Accreditation Council for Pharmacy Education (ACPE), and the American Nurses Credentialing Center (ANCC), to provide continuing education for the healthcare team.

FOR PHYSICIANS

Medscape, LLC designates this enduring material for a maximum of 1.00 *AMA PRA Category 1 Credit(s)*™. Physicians should claim only the credit commensurate with the extent of their participation in the activity.

Successful completion of this CME activity, which includes participation in the evaluation component, enables the participant to earn up to 1.0 MOC points in the American Board of Internal Medicine's (ABIM) Maintenance of Certification (MOC) program. Participants will earn MOC points equivalent to the amount of CME credits claimed for the activity. It is the CME activity provider's responsibility to submit participant completion information to ACCME for the purpose of granting ABIM MOC credit. Aggregate participant data will be shared with commercial supporters of this activity.

College of Family Physicians of Canada Mainpro+® participants may claim certified credits for any *AMA PRA Category 1 Credit(s)*™, up to a maximum of 50 credits per five-year cycle. Any additional credits are eligible as non-certified credits. College of Family Physicians of Canada (CFPC) members must log into Mainpro+® to claim this activity.

Through an agreement between the Accreditation Council for Continuing Medical Education and the Royal College of Physicians and Surgeons of Canada, medical practitioners participating in the Royal College MOC Program may record completion of accredited activities registered under the ACCME's "CME in Support of MOC" program in Section 3 of the Royal College's MOC Program.

For questions regarding the content of this activity or for technical assistance, contact CME@medscape.net.

INSTRUCTIONS FOR PARTICIPATION AND CREDIT

There are no fees for participating in or receiving credit for this educational activity. For information on applicability and acceptance of continuing education credit for this activity, please consult your professional licensing board.

This activity is designed to be completed within the time designated on the title page; physicians should claim only those credits that reflect the time actually spent in the activity. To successfully earn credit, participants must complete the activity online during the valid credit period that is noted on the title page. To receive *AMA PRA Category 1 Credit*™, you must receive a minimum score of 75% on the post-test.

Follow these steps to earn CME/CE credit*:

1. Read the target audience, learning objectives, and author disclosures.
2. Study the educational content.
3. Access the posttest webpage via the URL or by scanning the QR code.
4. Online, choose the best answer to each test question. To receive a certificate, you must receive a passing score as designated at the top of the test. We encourage you to complete the Activity Evaluation to provide feedback for future programming.
5. You may now view or print the certificate from your CME/CE Tracker. You may print the certificate, but you cannot alter it. Credits will be tallied in your CME/CE Tracker and archived for 6 years; at any point within this time period you can print out the tally as well as the certificates from the CME/CE Tracker.

*The credit that you receive is based on your user profile.

medscape.org/anthology/ded-diagnosis-and-treatment

Medscape Education © 2024 Medscape, LLC

COVER PHOTO: SRUILK/SHUTTERSTOCK

Clinical definition of dry eye disease

John D. Sheppard, MD, MMSc, FACS

Dry eye disease (DED) stems from dysfunction in the ocular structures responsible for tear film regulation, including the lacrimal glands, meibomian glands, cornea, and conjunctiva.[1-3] This dysfunction, in effect, leads to tear deficiency, eventually resulting in tear film instability and hyperosmolarity. The Tear Film and Ocular Surface Society (TFOS) classifies DED into 2 main subtypes: aqueous deficient (the inability to produce normal tears) and evaporative (an increase in tear evaporation) (**Figure 1**).[3] In either case, the pathologic changes that develop in DED ultimately ignite a vicious chronic inflammatory cycle on the ocular surface, causing injury/damage to the associated epithelial tissue, and impairing the patient's vision and quality of life.[1-3]

SYMPTOMS, CAUSES, AND RISK FACTORS

Dry eye disease is a common condition capable of causing varying degrees of ocular discomfort and visual disability.[2] DED is marked by fluctuations in vision that worsen throughout the day, with major symptoms including irritation, itching, soreness, ocular discomfort, burning, and intermittent blurred vision.[1-3,5,6]

Clinicians are encouraged to document a detailed medical history and work closely with the patient to identify risk factors potentially contributing to DED. Nonmodifiable risk factors include older age and female sex, both of which play a significant role in DED. Modifiable risk factors include autoimmune disorders such as rheumatoid arthritis (RA) and systemic lupus erythematosus. Other conditions that may

FIGURE 1. Classification of DED According to TFOS DEW II Guidance[3]

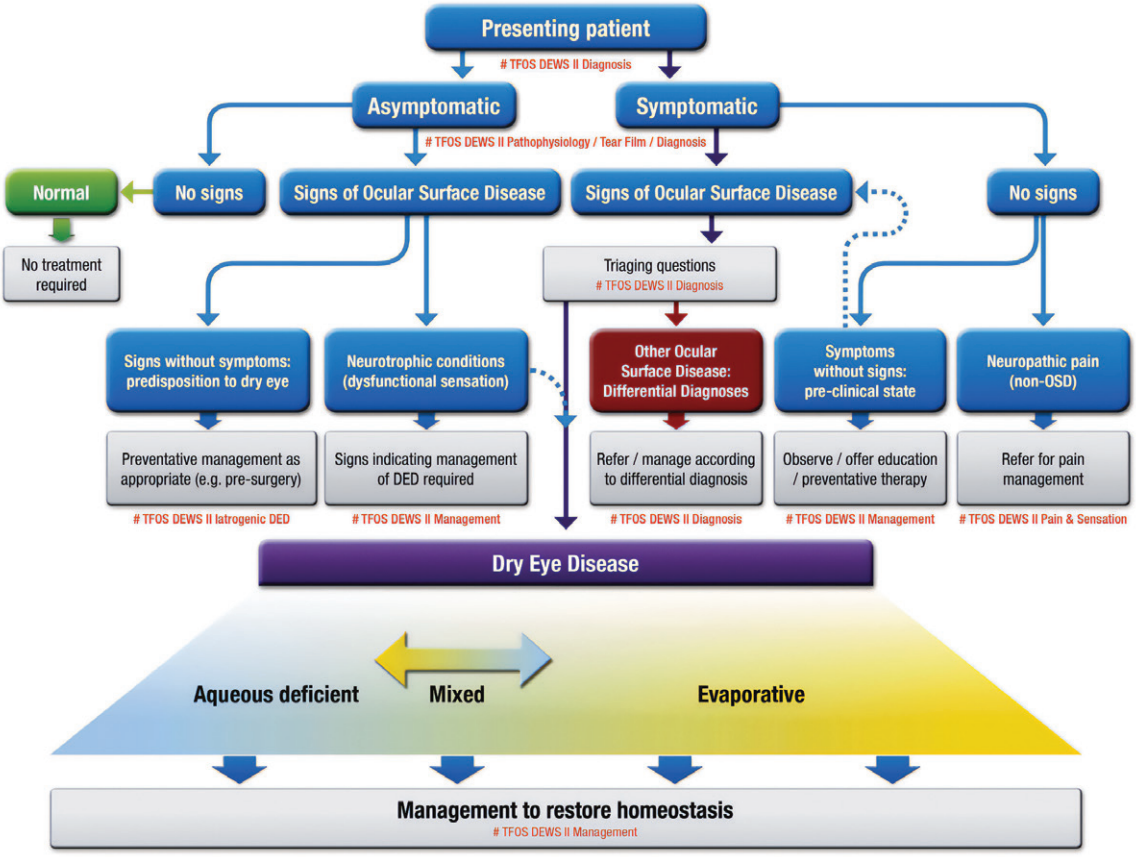

Reprinted from The Ocular Surface, 15(3), Craig, J.P., et al. TFOS DEWS II Definition and Classification Report, 276-283, Copyright (2017), with permission from Elsevier. TFOS DEW, Tear Film and Ocular Surface Society Dry Eye Workshop.

Medscape Disclaimer Statement

Medscape, LLC requires every individual in a position to control educational content to disclose all financial relationships with ineligible companies that have occurred in the past 24 months. Ineligible companies are organizations whose primary business is producing, marketing, selling, re-selling, or distributing healthcare products used by or on patients.

All relevant financial relationships for anyone with the ability to control the content of this educational activity have been mitigated. Others involved in the planning of this activity have no relevant financial relationships.

underly DED etiology include ocular allergies and dermatologic conditions (eg, ocular rosacea and demodicosis), and chronic conditions, such as diabetes (due to diabetic retinopathy) and glaucoma (medications for this can worsen DED).[1,6]

Exogenous factors and aspects of a patient's lifestyle, such as smoking, multivitamin consumption, chemical exposure (eg, 13-cis retinoic acid, polychlorinated biphenyls), and the use of medications including but not limited to antihistamines, antidepressants, antianxiety drugs, and corticosteroids can increase the risk of developing DED.[2,3] In addition, factors such as computer use, contact lens wear, androgen deficiency/hormone replacement therapy, and changes in the environment linked to pollution, low humidity, and sick building syndrome can all contribute to DED.[2,5,6]

Clinicians can ensure and maintain the ocular health of high-risk patients by establishing routine screening for DED and referring those requiring specialized attention to an eye care specialist early on.

Meibomian gland dysfunction (MGD) is considered the most common cause of evaporative DED, with signs of MGD reported in 70% to 90% of cases.[2,3,7-9] Whereas, systemic inflammatory disease is a significant cause of aqueous-deficient DED. Approximately 10% of patients have clinically significant aqueous deficient DED (ie, primary Sjögren syndrome).[10,11] Among patients with an underlying systemic inflammatory disorder, complications associated with severe DED include ocular surface keratinization; corneal scarring, thinning, or neovascularization; microbial or sterile corneal ulceration; and significant loss of vision.[2] Awareness of how these conditions manifest and their associated complications can help in making judicious clinical decisions.

USE OF CLINICAL QUESTIONNAIRES

Signs and symptoms of DED often mimic other conditions and establishing DED in the primary care setting can be challenging. In addition to patient history, the primary care clinician (PCC) might consider using clinical questionnaires to aid in diagnosis.[1,3,4] The Ocular Surface Disease Index (OSDI) and the Symptom Assessment in Dry Eye questionnaires (SANDE) can measure ocular surface discomfort or vision symptoms linked to DED, evaluate the impact of DED on daily functioning, and gauge changes in quality of life.[4,12] The Dry Eye Questionnaire (DEQ-5) and the Standard Patient Evaluation of Eye Dryness (SPEED) tool also add insight into the patient's symptoms and aid in confirming DED. Clinicians should note that such validated questionnaires might be ideally administered at the beginning of the patient interaction to help establish a diagnosis.[4,12] Alternatively, a simplified approach to an ocular review of systems may be more feasible. **Table 1** summarizes questions clinicians may consider helping rule out alternative diagnoses.[12]

REFERRAL TO SPECIALTY CARE

Although PCCs may offer initial management strategies to patients with DED, referral to an eye care specialist may be urgently warranted for patients who present with moderate or severe pain, fail to respond to initial therapy, or display signs of corneal infiltration, ulceration, or vision loss.[2]

TABLE 1. Initial Questions for the Differential Diagnosis of DED[12]

How severe is the eye discomfort?	Unless severe, dry eye presents with signs of irritation, such as dryness and grittiness rather than 'pain.' If pain is present, investigate for signs of trauma/infection/ulceration.
Do you have any mouth dryness or enlarged glands?	Trigger for Sjögren syndrome investigation
How long have your symptoms lasted & was there any triggering event?	Dry eye is a chronic condition, present from morning to evening, but generally worse at the end of the day. So, if sudden onset or linked with an event, examine for trauma/infection/ulceration.
Is your vision affected and does it clear on blinking?	Vision is generally impaired with prolonged staring but should largely recover after a blink. A reduction in vision that does not improve with blinking, particularly with sudden onset, requires an urgent ophthalmic examination.
Are the symptoms or any redness much worse in one eye than the other?	Dry eye is generally a bilateral condition, so if symptoms or redness are much greater in one eye than the other, detailed eye examination is required to exclude trauma & infection.
Do the eyes itch, are they swollen, crusty, or have they given off any discharge?	Itching is usually associated with allergies, while a mucopurulent discharge is associated with ocular infection.
Do you wear contact lenses?	Contact lenses can induce dry eye signs and symptoms and appropriate management strategies should be employed by the contact lens prescriber.
Have you been diagnosed with any general health conditions (including recent respiratory infections) or are you taking any medications?	Patients should be advised to mention their symptoms to the health professionals managing their condition, as modified treatment may minimize or alleviate their dry eye.

Reprinted from The Ocular Surface, 15(3), Wolffsohn, J.S., et al. TFOS DEWS II Diagnostic Methodology report, 539-574, Copyright (2017), with permission from Elsevier.

It is important to highlight the role of the interprofessional team in diagnosing and managing DED, as well as the role of other specialists in evaluating DED risk due to the number of comorbidities and medications that may contribute to DED. Specialists that may aid in the diagnosis and management of patients with DED include, but are not limited to, psychiatrists, neurologists, rheumatologists, dermatologists, obstetricians-gynecologists, and pediatricians.[1-3]

SPECIALIZED TESTING AND CONFIRMING DED

Specialized testing, including serum biomarker assays and computed tomography (CT) or magnetic resonance imaging (MRI) help rule out or identify underlying systemic conditions (eg, Sjögren syndrome, thyroid eye disease, sarcoidosis, RA, and ocular mucous membrane pemphigoid).[1,2,4,12]

A comprehensive ocular examination evaluates eye anatomy, physiology, function, and tear film stability, with tests including visual acuity (VA) and distance assessment, meibography, and slit-lamp examination (biomicroscopy). Additional tests may measure lacrimal gland function, tear osmolarity, or matrix metalloproteinase-9 (MMP-9), an ocular surface inflammatory biomarker. The Schirmer test assesses quantitative aqueous tear production. Measurement of tear breakup time (TBUT) measures tear film instability and rapid breakup, which are hallmarks of evaporative dry eyes. Specific methods can also be used to detect tear film or ocular surface abnormalities. The fluorescein dye test/tear function index detects punctate epithelial erosions on the ocular surface. Once a diagnosis of DED is confirmed, the attending eye care specialist can develop a treatment plan that is tailored to each patient.[1,2,4,12]

CLINICAL PEARLS

Collaboration between PCCs, eye care specialists, and the interprofessional team is essential for effective diagnosis and management of DED.[1,2,4] While PCCs play a vital role in initial diagnosis and patient education, eye care specialists provide expert diagnostic and therapeutic interventions for chronic DED. This approach ensures timely referrals and confirmation of DED diagnosis while addressing concomitant relevant ocular pathology and underlying etiologic comorbidities.[1,4] Clinicians should stress the importance of patient adherence to long-term treatment plans for continued receipt of therapeutic benefits. While DED has no cure, there are numerous available and effective patient-tailored treatments and environmental interventions.[1-4,13]

Dry eye disease: symptoms and impact on patient quality of life

Preeya K. Gupta, MD

Dry eye disease is largely a non–sight-threatening condition characterized by fluctuating vision and burdensome symptoms that progressively worsen throughout the day. DED and its associated symptoms can significantly affect quality of life, causing the patient difficulty with reading and driving, functioning socially and physically, and being productive in the workplace.[14,15] Patients may also experience anxiety and depression at all levels of DED severity, further complicating DED management.[16]

GOALS OF DED THERAPY

Treatment goals for patients with DED should aim to[1,13]:

- Restore and maintain ocular surface homeostasis
- Minimize clinical signs and long-term damage
- Maximize visual function and patient quality of life

Collaboration between PCCs and eye care specialists is essential to optimize care for patients with DED. Before selecting treatment, clinicians and specialists should consider the patient's medication history and patient preferences through shared decision-making.[1,2]

MANAGING DED IN PRIMARY CARE

Patient factors

Management of DED often requires a multifaceted approach, combining environmental and lifestyle modifications, pharmacologic agents, and nonpharmacologic modalities to address underlying etiology(ies) and restore/preserve tear film stability. PCCs should counsel patients on the causative factors associated with DED and emphasize the need to reduce or modify them, including lifestyle adjustments such as reducing prolonged screen time, time spent reading, contact lens wear, and exposure to brisk air conditioning flow, low humidity environments, and tobacco smoke.[1,2,4,5]

Clinicians should also carefully monitor medication use, particularly systemic drugs that may exacerbate DED.[1,2,4] If a medication is identified as a causative factor, discontinuation or dose adjustment may be necessary.[1,2,14,17] When a systemic drug is causing ocular toxicity, the treating clinician may also consider switching medications or changing the route of drug administration.[13,17]

First-line strategies PCCs can consider

Primary care clinicians should advise patients on initial

steps for treating DED, such as eyelid hygiene, warm compresses to help alleviate DED symptoms, and use of over-the-counter artificial tears (ocular lubricants), which remain a mainstay of first-line conservative therapy.[1-4] It should be noted, however, that while artificial tears provide some relief, they do not target DED's underlying pathophysiology. Addressing causative factors is crucial for effective DED management.[2,13]

Recommended and approved therapies

Currently there is no universally accepted approach to treating DED subtypes, largely due to the limited availability of clinical evidence.[2-4,13] The Tear Film and Ocular Surface Society Dry Eye Workshop (TFOS DEWS) II provides a stepwise approach to managing patients based on DED severity, with 4 main levels to guide therapy (**Table 1**).[13]

Notably, therapeutic approaches for DED may vary based on physician experience and patient preference, independent of disease severity.[1,2,13] An eye care specialist would ideally perform/prescribe specialized pharmacotherapies, such as those listed in steps 3 to 4.

Current U.S. Food and Drug Administration (FDA)-approved therapies for DED are listed in **Table 2**, with their phase 2/3 or phase 3 clinical trial results. Immunomodulatory drugs, such as cyclosporine A, a calcineurin inhibitor, and lifitegrast, a lymphocyte function-associated antigen-1 (LFA-1) antagonist, are indicated for the management of DED.[18-20] Other systemic therapies that may be used in the DED setting include corticosteroids, such as loteprednol etabonate, which is indicated for short-term use in patients with DED experiencing episodic flares, despite already being on treatments for chronic disease.[21]

Procedural and device-based treatments

Procedure and device-based treatment options may be recommended to patients needing additional management beyond lifestyle changes and artificial tears. These include common procedures, such as punctal occlusion, meibomian gland thermal pulsation and expression, intense pulsed light therapy, low-level light therapy, and

TABLE 1. TFOS DEWS II Stepwise Algorithm for Managing DED[13]

Treatment Level	Recommendations
Step 1	• Education on the condition and its management • Lifestyle modifications • Diet, including essential fatty acid supplementation • Cessation of causative factors • Lid hygiene • Use of warm compresses • Over-the-counter medications, including artificial tear drops • Lipid-containing supplements if MGD is present
Step 2	• Device-based treatments applied in office ○ Tear-conservation strategies ■ Punctal occlusion ■ Moisture chamber spectacles/goggles ○ Vectored thermal pulsation therapy ○ Intense pulsed light (MGD) • Approved/prescription medications ○ Antibiotics ■ Macrolides or tetracyclines ○ Short-course corticosteroid therapy ○ Immunomodulatory drugs ■ CsA and lifitegrast
Step 3	• Use of oral secretagogues • Consider autologous serum eye drops
Step 4	• Longer duration of corticosteroid therapy • Surgical intervention

CsA, cyclosporine A; MGD, meibomian gland dysfunction.

TABLE 2. Pivotal Trials of FDA-Approved Treatments for DED

Study Drug vs Control	Key Efficacy Data	Key Safety Data
CsA (0.05% emulsion) vs CsA (0.09% solution) vs vehicle[22*] (N = 455)	Improvement in conjunctival staining ($P < .01$)	AEs were mild in severity; instillation site pain was most common in both CsA groups: 13% to 15%; no serious ocular AEs were reported
CsA (0.09% solution) vs vehicle[23] (N = 744)	Clinically meaningful improvement in Schirmer test score at day 84: CsA, 16.6% vs vehicle, 9.2%; $P < .001$	TRAEs were mostly mild; most common AE associated with CsA: instillation site pain, 24.2%
Lifitegrast (5% solution) vs vehicle[24-26] (OPUS-1-3, N = 2017)	Improvements in signs/symptoms of DED; significant improvement in eye dryness score within 14 days (across all trials)	Mild to moderate TRAEs; no serious ocular AEs reported
Loteprednol etabonate (0.25% solution) vs vehicle[27-29] (STRIDE 1-3, N = 1970)	Significantly greater reduction in conjunctival hyperemia vs vehicle ($P < .009$ for all 3 trials)	Most frequently reported AE was instillation site pain: loteprednol etabonate, 5.7% to 6.1% vs vehicle, 5.2% to 6.1%

*Phase 2/3 trial. AE, adverse event; CsA, cyclosporine A; TRAE, treatment-related adverse event.

microblepharoexfoliation, and devices, such as eyelid hygiene devices, neurostimulation devices, and heat or moisture goggles.[1,2,13]

CLINICAL PEARLS FOR PRIMARY CARE

Primary care clinicians are an integral part of managing patients with DED, often providing initial education, establishing a diagnosis, and prescribing nonspecialized therapies.[1,4] PCCs are encouraged to have a low threshold for early referral to eye care specialists to avoid disease progression and ocular complications. Along these lines, PCCs and eye care professionals should work collaboratively with one another and their patients to identify and establish individual care plans based on disease features/severity, medical history, health status, and personal preferences.[1,2,4] As DED is a chronic disease that requires long-term treatment, a multifaceted approach that involves cessation of causative factors/triggers, lifestyle modifications, over-the-counter products, in-office treatments, and approved/evidence-based pharmacologic strategies may be required for optimal management.[1,2,4,13]

Novel agents for DED

Jason Luis Quiñones, PhD

Most treatments for DED provide only temporary relief, necessitating a multipronged approach blending lifestyle changes with pharmacologic intervention.[2,13,30] Because DED is a lifelong disease for which no cure is available, novel therapies are needed that can effectively modify the disease course and improve outcomes. Better understanding of DED pathophysiology has led to the development and approval of such agents with novel mechanisms of action.[30] This has opened the possibility to offer patients with DED new efficacious treatment options.[31]

RECENTLY APPROVED THERAPIES

New FDA-approved therapies for DED focus on restoring ocular surface homeostasis (**Table 1**).[30] Varenicline, an intranasal cholinergic agonist, stimulates tear production by activating the lacrimal functional unit.[30,32] Perfluorohexyloctane (NOV03), a steroid-free and preservative-free semifluorinated alkane, forms a barrier at the tear film-air interface, preventing evaporation and reducing shearing forces during blinking.[30,33] Future research aims to secure approval of NOV03 in treating DED associated with MGD, addressing an

TABLE 1. Pivotal Phase 2 and 3 Trials of New Pharmacologic Agents for Managing DED

Study Drug vs Control	Trial Name/Identifier (Enrollment Number)	Key Efficacy Data	Key Safety Data
Varenicline vs vehicle[35-37]	ONSET-1 NCT03636061 (N = 182)	Significantly greater improvement in tear production vs vehicle across all 3 trials (ONSET-1, at 3 different doses of varenicline: 0.006 mg, 0.03 mg, and 0.06 mg, $P < .001$; ONSET-2, at 2 different doses of varenicline: 0.3 and 0.06 mg, $P < .0001$; and MYSTIC, at 2 different doses of varenicline: 0.03 mg, $P > .05$, and 0.06 mg, $P = .024$, respectively)	Varenicline was well-tolerated across trials; most common TEAEs reported in ONSET-1 and MSYTIC: sneezing; ONSET-2: sneezing, cough, throat irritation, and instillation site irritation
	ONSET-2 NCT04036292 (N = 758)		
	MYSTIC NCT03873246 (N = 123)		
NOV03 vs vehicle[38-40]	MOJAVE NCT04567329 (N = 620)	Change from baseline to week 8 in total corneal fluorescein staining and eye dryness score was statistically significantly greater with NOV03 therapy vs vehicle (saline); $P < .001$	Incidence of ocular events was similar for NOV03 (12.9%) and saline (12.3%); no serious AEs or AEs leading to discontinuation were reported
	GOBI NCT04139798 (N = 599)	Change from baseline in total corneal fluorescein staining score and eye dryness score at week 8 was significantly greater with NOV03 therapy vs saline; $P < .001$	Most ocular AEs were mild in severity; no serious AEs occurred
	KALAHARI NCT04140227 (N = 208) (rolled over from GOBI)	Continued improvements in total corneal fluorescein staining and eye dryness score: maintained throughout the 52-week study vs GOBI baseline in the study eye, -2.1 +/- 2.5 and the fellow eye, -33.7 +/- 28.6	Ocular AEs experienced in 13.9% of patients; most common AEs: vitreous detachment (1.9%), allergic conjunctivitis, blurred vision, and increased lacrimation (each 1.4%)

TEAE, treatment-emergent adverse event; TRAE, treatment-related adverse event.

TABLE 2. Novel Therapies for DED Currently Under Clinical Study[30]

Agent Name	Drug Type/MoA	Phase of Development	Clinical Trial Identifier
Tanfanercept	Engineered soluble human TNF receptor I fragment; TNF-alpha inhibitor	Phase 3	NCT05109702
PL9643 MCr agonist	A-melanocyte stimulating hormone	Phase 3	NCT05201170
Tivanisiran (SYL 1001)	Small interfering siRNA against TRPV1	Phase 3	NCT05310422
AR-15512	TRPM8 agonist	Phase 3	NCT05285644
Ianalumab	Anti-BAFF receptor antibody	Phase 3	NCT05349214

BAFF, B-cell activating factor of the tumor necrosis factor family; siRNA, small interfering RNA; TNF, tumor necrosis factor.

unmet need in therapy for this specific indication.[34] However, updated medical guidelines are necessary to integrate these new agents effectively into current DED treatment strategies.

INVESTIGATING AGENTS

Several emerging therapies are in various phases of clinical investigation for the management of DED, including agents that interfere with inflammatory processes. Reproxalap targets the pro-inflammatory reactive aldehyde species (RASP) signaling pathway, and SkQ1, acts as a mitochondrial-targeted antioxidant.[30,41] Hyperkeratinization of the meibomian gland duct has been implicated in the etiology of MGD, supporting the modulation of keratin pathways as a novel approach to potentially alter the disease course of MGD.[30,42] AZR-MD-001 (selenium sulfide ointment) is a keratolytic agent being studied for DED in patients with MGD.[42] Recent data support the safe use of these agents for providing relief in the symptoms and/or signs of DED.[30] However, further research is needed to validate their efficacy and effective integration into clinical practice.

EMERGING CLINICAL DATA

Reproxalap

Reproxalap 0.25% ophthalmic solution has been studied in 5 clinical trials involving ~2000 patients with DED.[30] In a key phase 2 trial (N = 300), significant improvements were observed in combined DED symptoms by the first post-baseline visit (Week 2, $P < .0001$) and in nasal region fluorescein staining over 12 weeks ($P = .03$).[43] The most common treatment-emergent adverse event (TEAE) was ocular discomfort upon instillation, with most instances being transient and self-limiting.[43] Other studies have shown improvement in ocular discomfort and blurry vision with reproxalap.[30] The phase 3 TRANQUILITY-2 trial (N = 361) demonstrated reproxalap's statistical superiority over placebo in primary endpoints, including change from baseline on Schirmer's test and proportion of ≥ 10 mm Schirmer's test responders after 1 day of treatment.[42-44] In 2023, a new drug application (NDA) was submitted for reproxalap; however, it was determined after FDA review that further efficacy analyses were needed.[45]

SkQ1

The first phase 2b/3 clinical trials evaluating SkQ1 ophthalmic solution were VISTA-1 (N = 451) and VISTA-2 (N = 610).[46] While the co-primary endpoints of change from baseline in central corneal fluorescein staining and grittiness reduction were not met, both studies revealed significant improvements in key predetermined secondary endpoints, such as clearing of corneal fluorescein (VISTA-1, $P < .05$) and central corneal fluorescein staining relative to vehicle (in VISTA-2, defined by Schirmer's score by week 4; $P < .05$).[46] SkQ1 was also associated with a significant reduction in ocular discomfort and a favorable tolerability and safety profile compared to placebo.[46] SkQ1 will undergo further investigation in the VISTA-3 trial. Of note, adverse events such as burning after instillation, eye redness, and scratchiness were reported in an international clinical trial of SkQ1 in patients with DED.[47]

AZR-MD-001

In a recent phase 2 study, patients with MGD who received AZR-MD-001 (0.5% or 1.0% ophthalmic ointment) showed significant improvements in meibomian gland yielding liquid secretion (MGYLS) scores ($P < .001$) and ocular surface disease index (OSDI) total scores ($P < .05$).[48] Common TEAEs included application site pain, increased lacrimation, superficial punctate keratitis, corneal staining, eye pain, eye irritation, and eye inflammation. Most TEAEs were mild and transient.[48]

Other novel agents on the horizon

Several additional therapies currently in phase 3 of clinical development are actively being studied for the treatment of DED. These agents and their molecular targets are summarized in **Table 2**.[30]

WHAT THE PCC SHOULD KNOW

Safety concerns

Newer therapies approved for DED, such as varenicline and NOV03, pose minor safety concerns. Patients taking varenicline solution may experience sneezing, cough, throat irritation, and instillation-site (nose) irritation, and NOV03 users may encounter blurry vision.[32,33] No black box warnings, explicit contraindications, or monitoring guidance appear in the FDA prescribing labels for varenicline nasal

spray or NOV03, suggesting their relative safety for patient use in this setting.[32,33]

Clinical pearls for the PCC

Although new therapeutic options may not necessarily be available to all PCCs, clinicians should be aware of their availability. Familiarity with new and emerging agents fosters relationships between PCCs and eye care professionals to safely coordinate the integration of these therapies into clinical practice.[1,2,4]

KEY TAKEAWAYS

Although promising, new and investigative therapies require larger studies and updated medical guidelines to establish their integration into DED clinical management, and with new agents emerging, the demand for expertise from PCCs and eye care specialists will continue to rise. Early recognition of DED and implementation of newer treatments is critical to providing swift relief and preventing worsening symptoms requiring specialty care referral.[1,4] ●

Dry eye disease patient case

Selina McGee, OD, FAAO

Janet is a 46-year-old woman who works as a business executive, often spending 8-10 hours daily on her computer or cell phone. She presents today to her PCC with symptoms consistent with consistent with DED, beginning in the morning hours and worsening in intensity throughout the day. Janet's PCC performed a basic comprehensive metabolic blood panel and recommended using artificial tears (lubricating eye drops) for relief. Janet's initial workup is summarized in **Table 1**.

Janet's blood test results revealed no notable abnormalities pointing to a metabolic or endocrine disorder; her clinician advised her to continue using her eye drops for 2 to 3 months, with subsequent follow-up to discuss symptoms and changes in eye health status.

After 3 months, Janet returned to the clinic, having tried several different eyedrops without symptom relief. Her symptoms have worsened, including increased itchiness, grittiness, mild pain, blurriness, and photosensitivity, and are hampering her daily activities and work productivity. Considering her history and symptoms, Janet's PCC suspects DED. Taking her concerns and evolving clinical presentation seriously, her PCC refers her to a DED specialist (optometrist) for further management.

TABLE 1. Janet's Primary Care Workup

Personal and family medical history	• Suspected RA; testing performed 6 years ago was inconclusive • No other known comorbidities • Consumes a well-balanced diet consisting of meats, fruits, and vegetables • Current treatments/OTCs/corrective eyewear: ○ Daily woman's multivitamin supplement ○ Loratadine 10 mg once daily for ongoing allergy issues as needed ○ Uses contact lenses day and night
Presentation and physical exam	• Noninvasive eye examination in-office reveals eye redness; mild inflammation; watery eyes; mild photosensitivity; stringy mucus in and around eyelids
Laboratory measurements	• Blood testing: ○ Comprehensive metabolic panel to identify possible underlying etiologies all within normal limits ○ Abnormal findings: auto-immune (ANA/RF/HLA-B27-pos) suggestive of RA

ANA, antinuclear antibody; HLA, human leukocyte antigen; OTC, over-the-counter; RA, rheumatoid arthritis; RF, rheumatoid factor.

INITIAL EYE CARE EXAM AND TESTING

Janet consults with an optometrist, who performs a comprehensive eye exam and specialized testing.[1-3,12] Osmolarity was above normal in both eyes upon examination, consistent with tear homeostasis instability (moderate dry eyes); MMP-9 testing testing was positive in the right eye but negative in the left eye; and intraocular pressure (IOP) was normal in both eyes. SPEED questionnaire results suggested moderate to severe dry eye symptoms.

Figure 1 shows representative images captured from examinations. Slit lamp evaluation of the anterior segment and meibography showed lids/lashes with moderate collarettes, telangiectasia, and meibum secretion (3/5) that was cloudy and opaque in quality. Bulbar/palpebral conjunctiva were white and quiet; the corneal epithelium showed superficial punctate keratopathy (SPK), with a diffuse pattern in both eyes, indicative of DED; TBUTs (OD 6 s and OS 4 s) were abnormal, and tear meniscus heights (TMHs; OD 0.2 mm and OS 0.22 mm) were normal, consistent with evaporative DED and possible mixed DED. Analysis of the anterior chamber showed it was clear of any debris (deep and quiet). The irides were healthy, and the lenses were clear in both eyes. The posterior

FIGURE 1. Representative Images From Janet's Ophthalmologic Examination

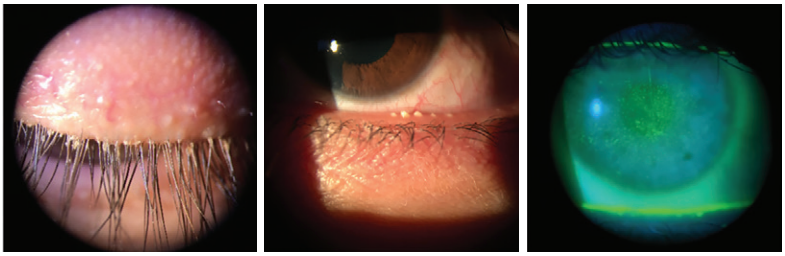

Images courtesy of Selina McGhee, OD, FAAO. Image showing Janet's right eyelid margins and eyelashes, with a noticeable degree of collarettes and debris (left); image showing yellow to white colored meibum secretions produced from Janet's right eye (middle); image showing sample fluorescein staining captured of Janet's right eye (right).

cup/disc ratio was normal in both eyes (0.2/0/2), consistent with the absence of glaucoma, and the macula foveal reflex and vessels were normal and intact.

DIAGNOSIS AND TREATMENT

Based on Janet's medical history, clinical presentation, and results of her comprehensive eye exams, Janet is diagnosed with evaporative DED due to MGD, ocular rosacea, ocular rosacea, demodex blepharitis, and meibomitis. Treatment should focus on the underlying condition, its symptoms, and complications.

Janet's optometrist provides education regarding her condition and discusses her treatment options and prognosis, emphasizing the importance of medication adherence and lifestyle modifications. Janet is prescribed varenicline solution, loteprednol etabonate (0.25% solution), and cyclosporine (0.09% ophthalmic emulsion) for 4 weeks.[19, 21] Due to the collarettes present and the demodex blepharitis diagnosis, she is also prescribed lotilaner solution (0.25%), 2 times per day for 6 weeks.[49] Janet is advised to take omega-containing supplements, reduce screen time (eg, taking 15- to 20-minute interval breaks), and avoid sleeping with contact lenses to minimize ocular surface irritation.

PATIENT FOLLOW-UP

One month into her treatment, Janet follows up with her optometrist. Although she reports some improvement, she believes further progress is possible. Comprehensive eye testing and imaging are repeated, showing improvement. Slit lamp evaluation of the anterior segment and meibography showed lids/lashes were improved, and there was a reduction in the presence of collarettes. Although telangiectasia was still present, the erythema she had experienced was improved, and meibum secretion quality was improved (2/5). The bulbar/palpebral conjunctiva was white and quiet; the corneal epithelium showed superficial punctate keratopathy remained diffuse in both eyes but had improved significantly; TBUT (OD 9 s and OS 7 s) and TMH (OD 0.22 mm and OS 0.25 mm) slightly improved. Analysis of the anterior chamber showed it was free of debris (deep and quiet). The irides were healthy, and the lenses were clear in both eyes. The posterior cup/disc ratio continued to be normal (0.2/0/2) in both eyes, and the macula foveal reflex and vessels remained normal and intact.

Janet's ongoing DED caused by MGD prompts modification to her treatment plan. She is prescribed NOV03 ophthalmic solution, which is efficacious in managing DED with MGD (but is not specifically indicated for MGD).[1,33,34,38-40] Lifestyle modifications and avoiding triggers, including specific cosmetic ingredients, are emphasized.[1-3,13] Janet's optometrist also recommends intense pulsed light therapy, in-office heating, and meibomian gland expression. Treatment typically includes 4 in-office sessions followed by maintenance every 6 to 12 months.[2,3,13,50]

CASE RESOLUTION AND OUTLOOK

Three months into her therapy, Janet's follow-up with her optometrist reveals additional improvement. Images captured from her 3-month follow-up examination are shown below in **Figure 2**. Slit lamp examination and meibography show complete resolution of collarettes, clear meibum quality (4/5), and no superficial punctate keratopathy. The anterior chamber remains free of debris (deep and quiet) and tear film parameters show a trend in improvement, with TBUT OD 10.1 s and OS 8.7 s, and TMH OD 0.23 mm and OS 0.28 mm.

Janet reports feeling much better, with almost complete resolution of symptoms, improved daily function, increased work productivity, and enhanced overall quality of life.

Janet's optometrist emphasizes the need to continue her medications despite feeling well, reminding her that DED has no cure and requires long-term management.[1-3,13] Follow-ups every 3-6 months are recommended, with additional visits for flare-ups or new symptoms. ●

FIGURE 2. Janet's Follow-Up Eye Exam



Left image courtesy of Selina McGhee, OD, FAAO; Right image credit: Shutterstock. Image showing right eye lid margins and eyelashes free from collarettes and debris (left) and image of Janet's right eye, showing signs of improvement, with no presence of erythema (right).

REFERENCES

1. Sheppard J, et al. Dry eye disease: identification and therapeutic strategies for primary care clinicians and clinical specialists. *Ann Med.* 2023;55:241-252.
2. Akpek EK, et al. Dry Eye Syndrome Preferred Practice Pattern®. *Ophthalmology*. 2019;126:P286-P334.
3. Craig JP, et al. TFOS DEWS II definition and classification report. *Ocul Surf.* 2017;15:276-283.
4. Verjee MA, et al. Dry eye disease: early recognition with guidance on management and treatment for primary care family physicians. *Ophthalmol Ther.* 2020;9:877-888.
5. Stapleton F, et al. TFOS DEWS II epidemiology report. *Ocul Surf*. 2017;15:334-365.
6. Bron AJ, et al. TFOS DEWS II pathophysiology report [published correction appears in *Ocul Surf*. 2019;17:842]. *Ocul Surf.* 2017;15:438-510.
7. Lemp MA, et al. Distribution of aqueous-deficient and evaporative dry eye in a clinic-based patient cohort: a retrospective study. *Cornea.* 2012;31:472-478.
8. Rabensteiner DF, et al. The prevalence of meibomian gland dysfunction, tear film and ocular surface parameters in an Austrian dry eye clinic population. *Acta Ophthalmol.* 2018;96:e707-e711.
9. Badian RA, et al. Meibomian gland dysfunction is highly prevalent among first-time visitors at a Norwegian dry eye specialist clinic. *Sci Rep.* 2021;11:23412.
10. Akpek EK, et al. Evaluation of patients with dry eye for presence of underlying Sjögren syndrome. *Cornea*. 2009;28:493-497.
11. Liew MS, et al. Prevalence and predictors of Sjogren's syndrome in a prospective cohort of patients with aqueous-deficient dry eye. *Br J Ophthalmol.* 2012;96:1498-1503.
12. Wolffsohn JS, et al. TFOS DEWS II diagnostic methodology report. *Ocul Surf.* 2017;15:539-574.
13. Jones L, et al. TFOS DEWS II management and therapy report. *Ocul Surf.* 2017;15:575-628.
14. Miljanović B, et al. Impact of dry eye syndrome on vision-related quality of life. *Am J Ophthalmol.* 2007;143:409-415.
15. Mertzanis P, et al. The relative burden of dry eye in patients' lives: comparisons to a U.S. normative sample. *Invest Ophthalmol Vis Sci.* 2005;46:46-50.
16. Li M, et al. Anxiety and depression in patients with dry eye syndrome. *Curr Eye Res.* 2011;36:1-7.
17. Gomes JAP, et al. TFOS DEWS II iatrogenic report. *Ocul Surf.* 2017;15:511-538.
18. Cyclosporine (0.05% emulsion) [prescribing information]. Approved 1983. Revised 2017.
19. Cyclosporine (0.09% solution) [prescribing information]. Approved 1983. Revised September 2019.
20. Lifitegrast solution [prescribing information]. Approved 2016. Revised June 2020.
21. Loteprednol etabonate (0.25% solution) [prescribing information]. Approved 1998. Revised October 2020.
22. Tauber J, et al. A phase II/III, randomized, double-masked, vehicle-controlled, dose-ranging study of the safety and efficacy of OTX-101 in the treatment of dry eye disease [published correction appears in *Clin Ophthalmol.* 2018;12:2637] [published correction appears in *Clin Ophthalmol.* 2019;13:215]. *Clin Ophthalmol.* 2018;12:1921-1929.
23. Goldberg DF, et al. A phase 3, randomized, double-masked study of OTX-101 ophthalmic solution 0.09% in the treatment of dry eye disease. *Ophthalmology*. 2019;126:1230-1237.
24. Sheppard JD, et al. Lifitegrast ophthalmic solution 5.0% for treatment of dry eye disease: results of the OPUS-1 phase 3 study. *Ophthalmology*. 2014;121:475-483.
25. Tauber J, et al. Lifitegrast ophthalmic solution 5.0% versus placebo for treatment of dry eye disease: results of the randomized phase III OPUS-2 study. *Ophthalmology*. 2015;122:2423-2431.
26. Holland EJ, et al. Lifitegrast for the treatment of dry eye disease: results of a phase III, randomized, double-masked, placebo-controlled trial (OPUS-3). *Ophthalmology*. 2017;124:53-60.
27. Gupta PK, et al. The role of KPI-121 0.25% in the treatment of dry eye disease: penetrating the mucus barrier to treat periodic flares. *Ther Adv Ophthalmol.* 2021;13:25158414211012797.
28. Holland EJ. Efficacy and safety of KPI-121 0.25% for short term relief in dry eye (STRIDE). Presented at: ASCRS Virtual Annual Meeting; May 16-17, 2020.
29. Korenfeld M, et al. Safety of KPI-121 Ophthalmic suspension 0.25% in patients with dry eye disease: a pooled analysis of 4 multicenter, randomized, vehicle-controlled studies. *Cornea*. 2021;40:564-570.
30. Roucaute E, et al. Novel treatments for dry eye syndrome. *Curr Opin Pharmacol.* 2024;75:102431.
31. Wu D, et al. Novel therapeutics for dry eye disease. *Ann Med.* 2023;55:1211-1212.
32. Varenicline solution (nasal spray) [prescribing information]. Approved 2006. Revised October 2021.
33. Perfluorohexyloctane solution [prescribing information]. Approved 2023. Revised May 2023.
34. Sheppard JD, et al. Dry eye disease associated with Meibomian gland dysfunction: focus on tear film characteristics and the therapeutic landscape. *Ophthalmol Ther.* 2023;12:1397-1418.
35. Wirta D, et al. ONSET-1 phase 2b randomized trial to evaluate the safety and efficacy of OC-01 (varenicline solution) nasal spray on signs and symptoms of dry eye disease. *Cornea*. 2022;41:1207-1216.
36. Wirta D, et al. Efficacy and safety of OC-01 (varenicline solution) nasal spray on signs and symptoms of dry eye disease: the ONSET-2 phase 3 randomized trial. *Ophthalmology*. 2022;129:379-387.
37. Quiroz-Mercado H, et al. A phase II randomized trial to evaluate the long-term (12-week) efficacy and safety of OC-01 (varenicline solution) nasal spray for dry eye disease: the MYSTIC study. *Ocul Surf.* 2022;24:15-21.
38. Sheppard JD, et al. NOV03 for signs and symptoms of dry eye disease associated with Meibomian gland dysfunction: the randomized phase 3 MOJAVE study. *Am J Ophthalmol.* 2023;252:265-274.
39. Tauber J, et al. NOV03 for dry eye disease associated with Meibomian gland dysfunction: results of the randomized phase 3 GOBI study. *Ophthalmology*. 2023;130:516-524.
40. Protzko EE, et al. Long-term safety and efficacy of perfluorohexyloctane ophthalmic solution for the treatment of patients with dry eye disease: the KALAHARI study. *Cornea.* 2023. doi:10.1097/ICO.0000000000003418 [Epub ahead of print]
41. Sheppard JD, et al. Four novel approaches to DED treatment. *Ophthalmol Manag.* 2022;26:34,36,38.
42. Mulpuri L, et al. Peering into the dry eye pipeline for 2023 and beyond. *touchOPHTHALMOLOGY.* 2023;17:15-18.
43. Clark D, et al. Early onset and broad activity of reproxalap in a randomized, double-masked, vehicle-controlled phase 2b trial in dry eye disease. *Am J Ophthalmol.* 2021;226:22-31.
44. ClinicalTrials.gov. The TRANQUILITY 2 trial: A phase 3 clinical trial to assess the efficacy and safety in subjects with dry eye disease. Accessed February 7, 2024. https://clinicaltrials.gov/ct2/show/study/NCT05062330
45. Hutton D. Aldeyra Therapeutics receives complete response letter from FDA for reproxalap NDA. Accessed February 7, 2024. Published November 29, 2023. https://www.ophthalmologytimes.com/view/aldeyra-therapeutics-receives-complete-response-letter-from-fda-for-reproxalap-nda
46. Ousler GW, et al. Safety and efficacy of ophthalmic mitochondrial reactive oxygen species scavenger visomitin for the treatment of dry eye disease: findings of VISTA-1 and VISTA-2 studies. *Invest Ophthalmol Vis Sci.* 2022;63:1555-A0280.
47. Brzheskiy VV, et al. Results of a multicenter, randomized, double-masked, placebo-controlled clinical study of the efficacy and safety of visomitin eye drops in patients with dry eye syndrome. *Adv Ther.* 2015;32:1263-1279.
48. Watson SL, et al. Efficacy and safety of AZR-MD-001 selenium sulfide ophthalmic ointment in adults with meibomian gland dysfunction: A vehicle-controlled, randomized clinical trial. *Ocul Surf*. 2023;29:537-546.
49. Lotilaner [prescribing information]. Approved 2023. Revised July 2023.
50. Vora GK, Gupta PK. Intense pulsed light therapy for the treatment of evaporative dry eye disease. *Curr Opin Ophthalmol.* 2015;26:314-318.

A PUBLICATION OF
THE JOURNAL OF
FAMILY
PRACTICE™
APRIL 2024 | MDEDGE.COM/FAMILYMEDICINE

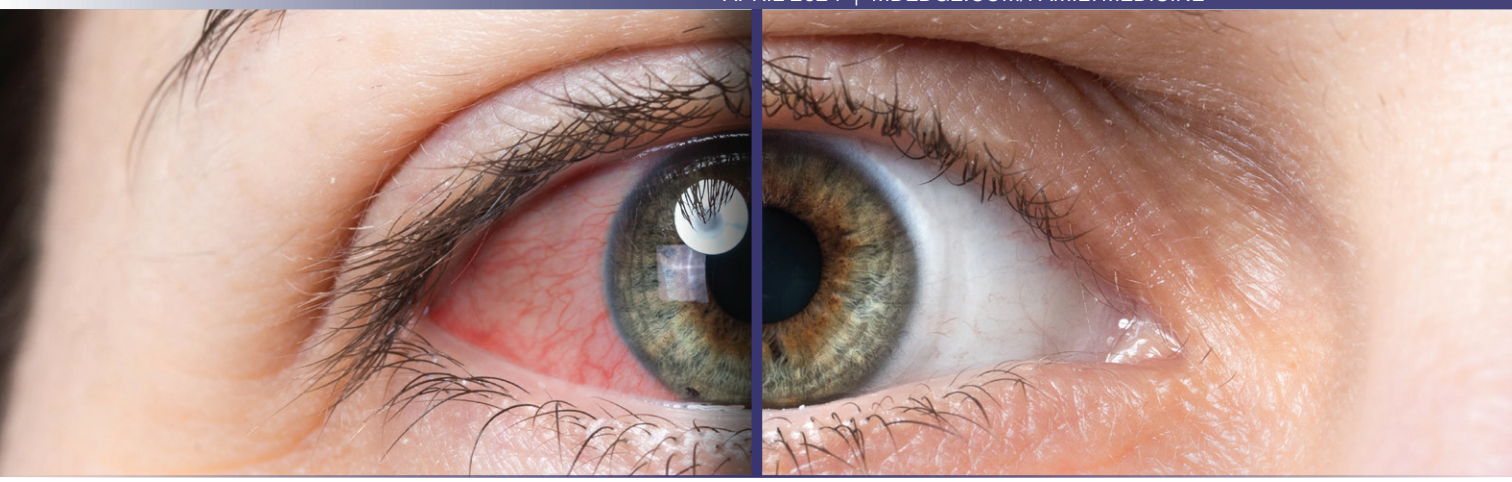

Dry Eye: A Hands-On Guide for Diagnosis and Treatment in Primary Care

Based on a Medscape Education Online Activity

THE JOURNAL OF FAMILY PRACTICE
17550 N Perimeter Drive,
Suite 110
Scottsdale, AZ 85255-7829

PRSRT STD
U.S. POSTAGE
PAID
HARRISBURG PA
PERMIT 500